

Visual outcome of patients with posterior capsular opacification treated with Nd:YAG laser

Ajit K. Joshi¹, Akshay Parashar^{2*}, Konduskar Rasika³

¹Professor and HOD, ²Senior Resident, ³Junior Resident, ¹⁻³Dept. of Ophthalmology, Bharati Vidyapeeth Medical College and Hospital wanlesswadi, Sangli- Miraj road, Sangli, Maharashtra, India

Abstract

Aim: To study the visual outcome and morbidity of patients who will be treated by Nd: YAG laser capsulotomy following PCO.

Keywords: Cataract, Elsching pearl, Intra-ocular pressure, Retinal detachment.

Introduction

The posterior capsular opacification (PCO) is the most frequent post-operative complication associated with decreased vision following small incision cataract surgery or phacoemulsification. The incidence of development of PCO is 25 to 50%, between 2 months and five years in adults following the initial surgery. PCO in pediatric age group is a major problem where the incidence approaches 100%. Nd-YAG (Neodymium yttrium aluminum garnet) laser posterior capsulotomy is a non-invasive, effective, relatively safe technique compared to primary or secondary posterior capsulotomy to manage intact posterior capsule that opacify post-operatively. This procedure is not always free of complications and several complications have been reported in the various clinical studies¹. In this study, an attempt has been made to evaluate the visual outcome following Nd-YAG laser capsulotomy and also to evaluate the immediate and late complications following laser capsulotomy.

Materials and Methods

It was a hospital based observational study. It was conducted from December 2015 to September 2017 in the Ophthalmology Department, Bharati Hospital, Sangli. Study was started after Institutional ethical committee clearance (2015-16/130). Seventy eight patients who had undergone small incision cataract surgery or Phacoemulsification with PCIOL and came with chief complains of postoperative diminution of vision or glare and clinically diagnosed to have PCO were selected on first come first basis.

All patients previously operated for cataract by routine SICS or Phacoemulsification with PCIOL implantation and with significantly impaired visual acuity due to PCO were included in the study. Eyes with active inflammation, other associated co-morbid conditions (corneal opacities, macular diseases, retinopathies, optic nerve diseases, glaucoma) and who cannot follow up, un-cooperative and unwilling patients were excluded from the study.

Patient was explained in detail about the purpose of the procedure, duration, painless nature, importance of maintenance of steady fixation, and the associated complication, following which an informed written consent was taken from the patient. 0.8% Tropicamide and 5% Phenylephrine hcl eye drop was instilled into the lower fornix to achieve mydriasis, 30 minutes and 10 minutes before the procedure. Anti-glaucoma medication Timolol 0.5% eye drop, one drop one hour before laser procedure was instilled into the cul-de-sac and 0.5% Proparacaine hcl eye drop was instilled in the cul-de-sac just before the procedure. At the laser table the procedure was explained once again to the patient, the table, stool and chin rest was adjusted for optimal patient comfort, the room was darkened to improve visualization of the target and consequently help in accurate focusing of the laser beam. The slit lamp beam was narrowed and obliquely angled to minimize miosis. Using 1 to 2mJ per pulse from Q switched ND YAG laser a sufficient opening in the posterior capsule was made, minimal energy of 1mJ was used with increment of 0.5mJ; in calcitrant condition upto 4.5 mJ was used. Capsulotomy was preferably started in an existing area of separation between posterior capsule and IOL, further areas of separation was achieved by placing the shots in a cruciate pattern starting from 12 'o'clock and progressing towards 6 'o' clock, in clock wise direction, Residual posterior capsular flaps if noted in the pupillary area were directly fired with laser shots to cut them so that they retract and fall back towards the periphery.

All patients were examined under the slit lamp and were advised topical Nepafenac 0.1% eyedrop, 3 times a day for a month to control post laser inflammation. After capsulotomy, follow up was done at the end of 1 hour, one week and at one month. The visual acuity were measured at one week and one month whereas IOP were measured at each follow up and also examined for any associated complication and appropriate intervention were made during the study period.

*Corresponding Author: Akshay Parashar, Dept. of Ophthalmology, Bharati Vidyapeeth Medical College and Hospital wanlesswadi, Sangli- Miraj road, Sangli, Maharashtra, India
Email: dranjurchandran@gmail.com
<http://doi.org/10.18231/j.ijoo.2019.028>

Results and Observations

The study comprised 78 eyes of 78 patients diagnosed to have PCO by direct ophthalmoscope and slit lamp examination. The study shows no sex predilection (Table 1). The average age of patients was 65 ± 11.05 years, ranging from 22 to 85 years (Fig.1). The study showed that right eye was more involved than the left eye. (Fig. 2). The interval between cataract extraction and capsulotomy ranged from 06 to 72 months with an average of 26 months (2 year and two months), formation of PCO increases after 1 year of surgery according to the present study (Fig. 3). Out of 78 patients, Elschnig pearl type of PCO (Fig. 4) was around 85% and fibrous type (Fig. 5) was 15% (Fig.6). 16.66% percent of the patients best corrected visual acuity was between CF 1 mt to 6/60 before laser application. There were 55.12% patients with visual acuity between 6/60 and 6/24 and 28.20% patients had visual acuity between 6/18 and 6/9 before treatment (Fig.7). Following ND YAG laser capsulotomy 85.89% patients gained 6/18 or better BCVA after one week, 71(91.03%) patients gained best corrected visual acuity of 6/18 or better after 1 month. The result was significant as $p < 0.05$ (Fig. 8). Only 11 out of 78 patients had complications. Out of which, 3 (3.85%) patients had raised IOP, 6 (7.69%) patients had IOL pitting, 2 (2.56%) patients had CME. 7 patients had vision less than 6/18 post Nd: YAG laser capsulotomy, out of which 2 patients had CME, 3 patients had amblyopia (high hypermetropia) and 2 patients had surgically induced high astigmatism treated by giving best corrected refraction. There was no incidence of RD (Fig. 9). The total cumulative energy (energy per pulse in mJ x number of pulses) required to perform adequate capsulotomy ranged from 35 to 105 mJ. The mean total cumulative energy delivered for elschnig pearl type Posterior Capsular Opacification was 64 ± 30 mJ while for fibrous type of Posterior Capsular Opacification higher energy 84 ± 30 mJ was required. The mean total energy delivered was 67 ± 30 mJ but maximum patients required less than 100 mJ for capsulotomy & in 1 case who required more than 100 mJ developed rise in Intra ocular pressure (Table 2). In our study, after 1 hour post laser capsulotomy, 43(55.12%) patients did not have any fluctuations in their IOPs.

32(41.02%) cases showed marginal elevation in their IOPs in the range of 1-2 mmHg (CCT corrected).

3(3.84%) cases showed rise of 5 mm Hg in IOP.

After 1 week post laser capsulotomy, out of 78 cases, 71(94.87%) patients had normal IOP whereas 4(5.12%) cases had still marginal elevation of 1-2mm Hg.

Antiglaucoma medication was stopped in those 3(3.84%) cases who showed rise of 5 mm Hg in IOP at 1 hour as their IOP returned to normal level after 1 week.

After 1 month post laser capsulotomy, all 78 cases came to pre capsulotomy IOP level at follow up (Table 3)

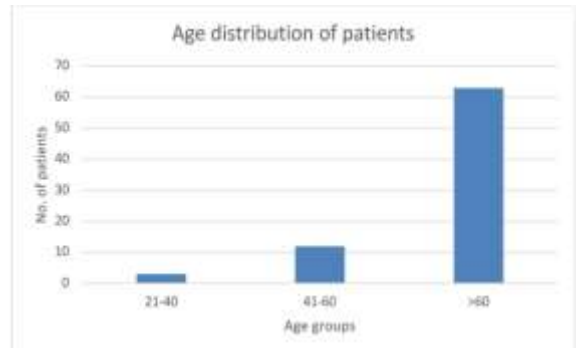


Fig. 1: Showing age distribution

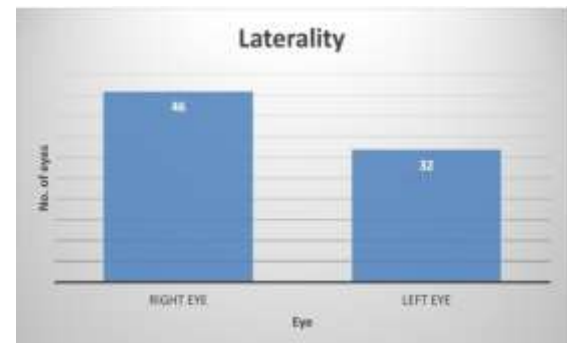


Fig. 2: Laterality

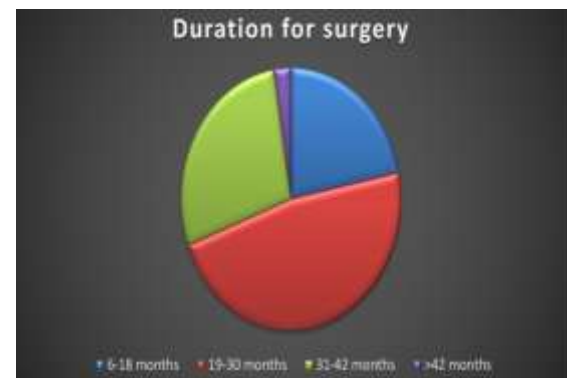

Fig. 3: Time interval between cataract surgery and Nd:YAG laser capsulotomy

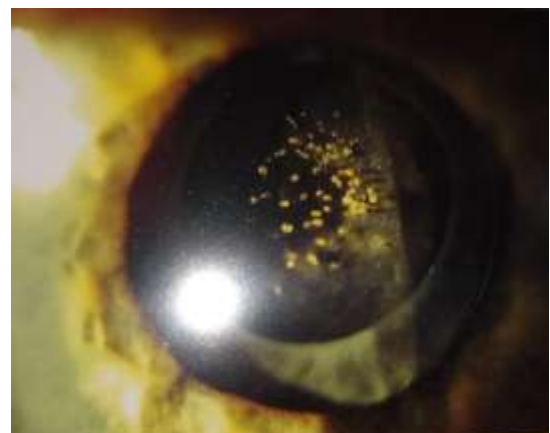

Fig. 4: Elschnig's Pearls type of PCO.

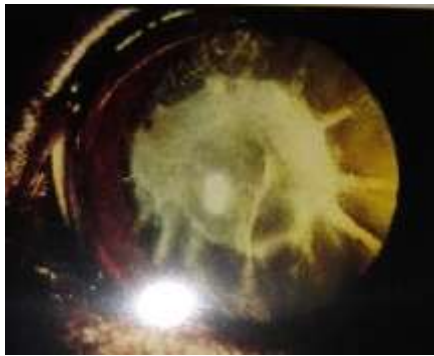

Fig. 5: Fibrous type of PCO

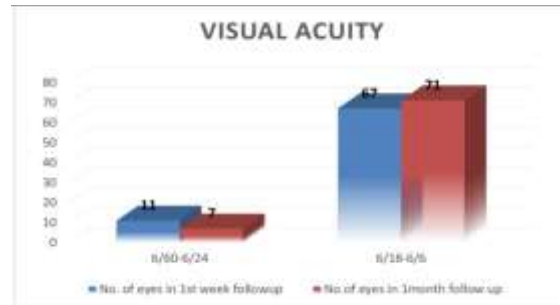


Fig. 8: Showing Best corrected visual acuity after ND YAG laser capsulotomy

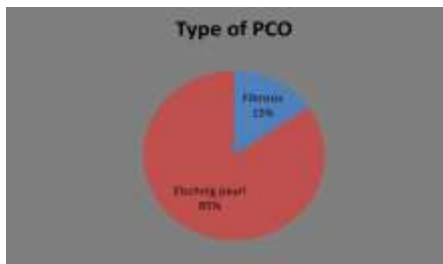


Fig. 6: Types of PCO

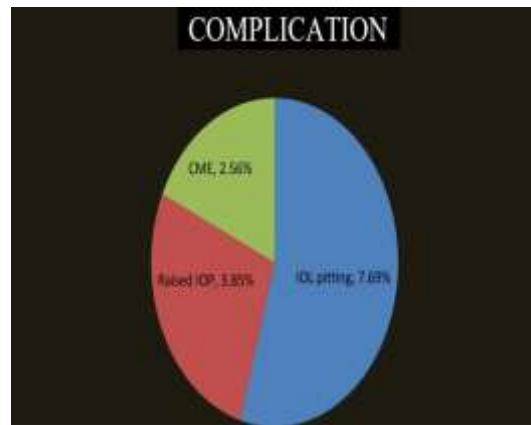


Fig. 9: complication of Nd:YAG

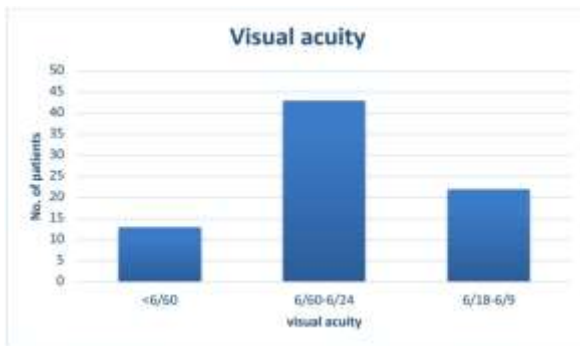


Fig. 7: Showing best corrected visual acuity before ND YAG laser capsulotomy

Table 1: Showing sex distribution

SEX	Number of eyes	Percentage
Male	39	50
Female	39	50

Table 2: Cumulative Energy required in different type of PCO

Cumulative laser energy in mj.	Elschnig's pearl		Fibrosis		Total	
	Cases	%	Cases	%	Cases	%
<50	9	11.59%	0	0	9	11.59%
51-60	13	16.74%	1	1.25%	14	17.99%
61-70	23	29.62%	2	2.50%	25	32.12%
71-80	12	15.45%	1	1.25%	13	16.70%
81-90	9	11.59%	5	6.25%	14	17.84%
91-100	0	0	2	2.50%	2	2.50%
>100	0	0	1	1.25%	1	1.25%
Total	66	84.99%	12	15%	78	100%

Table 3: Rise in IOP after ND:YAG Laser capsulotomy in relation to pre laser capsulotomy IOP

IOP in mmHg	1 st hour	1 st week	1 month
NO change	43(55.12%)	74(94.87%)	78(100%)
1-2mmHg increase	32(41.02%)	4(5.12%)	0
5mmHg increase	3(3.84%)	0	0

Discussion

In the present study, we examined 78 patients, out of which 39(50%) were females and 39(50%) were males. There was no significant sex predilection among the patients who developed PCO.

Cataract is the leading cause of blindness worldwide, occurs equally among male and females and complication like PCO also occur in equal proportions irrespective of gender. This is in agreement with the study of Pandey SK et al.¹, Ken Hayashi et al.,² Aslam TM et al.³ Dharmaraju B et al.⁴ and Spalton DJ et al.⁵

In present study out of 78 cases, 75(96.15%) cases fall in the age group more than 40 years. This is perhaps the age at which patients with age related cataract present to the ophthalmologist and more number of cataract surgeries performed in this age group.

Relatively less number of cases presented with PCO in younger age in our study group (<60 years). This can be attributed to the fact that number of cataract surgeries performed in that age group was less.

Out of 78 eyes examined in our study, 46(58%) were right and 32(41%) were left eyes. The difference between the causation of PCO in right eye to that of left eye is statistically significant ($P>0.05$), large number of patients were of right eye with PCO compared to left eye.

Significant number of involvement of right eyes in our study could be due to the fact that more number of right eyes got operated for cataract in our study group.

In the present study majority of patients, the timing of YAG laser capsulotomy following cataract surgery with PCIOL implantation averaged 26 months.

Spalton et al.⁵ noted in his study development of PCO in his patients by 2 to 3 years after cataract surgery.

Considering the illiteracy and rural background of our patients, in few patients there can be a possibility of time lapsed between actual development of PCO and patients undergoing YAG capsulotomy.

Schaumberg et al.⁶ also conducted an important meta analysis on published articles on PCO and generated pooled estimate of eyes developing PCO over three post operative points that is 1,3 and 5 years and noted a steady increase in incidence of PCO over first five postoperative years. The present study is in agreement with this study.

In the present study out of 78 eyes studied, 66(84.61%) eyes were having Elschnig's pearls and 12(15.38%) eyes were having fibrosis type of PCO which is in agreement with the study done by Tariq M Aslam et al.⁷ who noted mean pearl grading score as 3.3 and mean fibrosis grading score as 2.3.

All the 78 patients in our study showed improvement in visual acuity following the YAG laser capsulotomy procedure.

After one week of YAG capsulotomy, the visual acuity improved to $\geq 6/18$ in 67(85.90%) patients.

After one month, additional 4 patients i.e. total 71(91.03%) patients gained visual acuity of $\geq 6/18$.

This shows that Nd:YAG capsulotomy in PCO improves

patients' best corrected visual acuity with necessary refractive correction.

Improvement in BCVA in 71(91.03%) patients is in agreement with the study mentioned below:

Dharmaraju B et al.⁴ in his study on 100 patients undergoing Nd:YAG laser capsulotomy noted improvement in BCVA in 95% cases.

In our study, 7(8.97%) patients failed to achieve BCVA $\geq 6/18$ post YAG laser capsulotomy after one month.

Three (3.84%) patients were having high hypermetropic amblyopia and two (2.56%) patients had high surgically induced astigmatism whereas two (2.56% patients developed CME after YAG capsulotomy.

Elevated intraocular pressure is recognised as the most common, although usually transient complication following Nd:YAG laser capsulotomy.

In our study, After 1 hour post laser capsulotomy, 43(55.12%) patients did not have any fluctuations in their IOPs 32(41.02%) cases showed marginal elevation in their IOPs in the range of 1-2 mmHg but no one had IOPs above 21 mmHg 3(3.84%) cases showed rise of 5 mm Hg in IOP.

After 1 week post laser capsulotomy, out of 78 cases, 71(94.87%) patients had normal IOP whereas 4(5.12%) cases had still marginal elevation of 1-2mm Hg.

Those 3(3.84%) cases who showed rise of 5 mm Hg in IOP at 1 hour as their IOP returned to normal level after 1 week.

After 1 month post laser capsulotomy, all 78 cases came to pre capsulotomy IOP level at follow up.

Our present study is in agreement with the studies mentioned below.

- In a study conducted by Lin J C et al., an IOP rise was noted of at least 5 mm Hg, 1 hr following the capsulotomy in 7.2% of the patients.⁸
- Stark WJ et al. reported a transient IOP rise (>5 mmHg) in the early post capsulotomy period occurs in approximately 10 to 40% of all individuals.⁹

Association of energy with rise in IOP-In our study, out of 3 cases who developed high IOP and were kept on antiglaucoma for 1 week, 1 patient required higher energy for the YAG capsulotomy.

In present study out of 78 cases, 2(2.56%) cases developed cystoid macular oedema following Nd:YAG laser posterior capsulotomy

Mean total energy in eyes with CME was 67.5 mJ which is same as mean total energy for the entire group.

Roger F Steinert et al. studied 897 patients and reported incidence of CME as 1.23% and in their study concluded that the numbers of laser pulses and energy delivered were not risk factor for development of CME.¹⁰

The present study is in agreement with the above study.

In present study out of 78 cases, 6(7.69%) cases developed IOL pitting during Nd:YAG laser posterior capsulotomy.

Patil MS et al.¹¹ in their study on 100 eyes of 100 patients undergoing Nd:YAG capsulotomy observed IOL pitting in 7 patients (7%).

In our study no case (0%) developed retinal detachment. This could be because of the absence of risk factors in our cases like intra-operative PC rent, patients with lattice degeneration.

Khan MY (2006)¹² have examined the relationship between Nd:YAG laser posterior capsulotomy and development of retinal detachment and have found 0% frequency of RD in their studies. This is in agreement with our study.

William Tasman studied 18 eyes that developed pseudophakic RD after YAG capsulotomy, he found that the average time interval from YAG capsulotomy to RD was six months¹³.

Shorter duration of follow up (1 month) in our study is a limitation considering follow up period of 6 months quoted by William Tasman in view of development of retinal detachment post Yagcapsulotomy.

Other complications like anterior uveitis, rupture of anterior vitreous face, iris burns and corneal burns did not occur in our study.

Shashi Jain et al. studied 280 eyed, reported 0% incidence of rupture of anterior vitreous face.¹⁴

Following authors have reported less than 1% of incidence of anterior uveitis their case studies after Nd:YAG laser capsulotomy.

- a. Roger F Steinert studied and reported less than 1% of eyes have anterior uveitis.¹⁰
- b. Keates et al. reported 0.4% incidence of anterior uveitis.¹⁵

In our case study not a single case of anterior uveitis was seen.

In present study the total cumulative energy (energy per pulse in mix number of pulses) required to perform adequate capsulotomy ranged from 35 to 105 mj. The mean total cumulative energy delivered for Elsching pearl type of PCO was 64mj while for fibrous type of PCO higher energy 84 mj was required. The mean total energy delivered was 67mj.

Dharmaraju, et al. studied 100 eyes, reported the mean total cumulative energy delivered for Elsching pearl type of PCO was 65±15mj while for fibrous type of PCO higher energy 85±20 mj was required. The mean total energy delivered was 75±15 mj.⁴

According to Flohr et al. 89% of eyes required a pulse setting of less than 1.7 mJ to successfully penetrate the posterior capsule. The mean total energy delivered was 83±76mj.¹⁶

The results of above studies study is in agreement with the present study.

Source of Funding

None.

Conflict of Interest

None.

References

1. Pandey SK, Apple D, Werner L, Malerf A, Biomedl M, Franzio, et al. Posterior capsule opacification: A review of the aetiopathogenesis, experimental and clinical studies and factors for prevention; *Indian J Ophthalmol* 2004;52:99-112.
2. Hayashi K, Hayashi H, Nakao F, Hayashi F. Correlation between posterior capsule opacification and visual function before and after Neodymium: YAG laser posterior capsulotomy. *Am J Ophthalmol* 2003;136(4):720-6.
3. Aslam TM, Devlin H Dhellon B, Werghi M, Taguri A, Wadood Use of ND YAG laser capsulotomy. *Br J Ophthalmol* 2003;48:594-612.
4. Dharmaraju B, Vijayasree S, Sridhar K:A clinical study of visual outcome in Nd:YAG Laser capsulotomy in posterior capsule opacity. *Int J Contemp Med Res* 2016;3(9):2665-8.
5. Spalton DJ, Posterior capsular opacification after cataract surgery. *Eye* (1999) Royal College of Ophthalmologists 13: 489-492
6. Schaumberg DA, Dana MR, Christen WG, Glynn RJ. A systematic overview of the incidence of posterior capsule opacification. *Ophthalmol* 1998;105:1213-21.
7. Aslam T, Patton N. Methods of assessment of patients for Nd:YAG laser capsulotomy that correlate with final visual improvement. *BMC Ophthalmol* 2004;4(13):1-6.
8. Lin JC, Katz LJ, Spaeth GL: Intraocular pressure control after Nd:YAG laser capsulotomy in eyes with glaucoma. *Br J Ophthalmol* 2008;92:337-9.
9. Stark WJ, Worthen D, Holladay JT, Murray G. Neodymium: YAG lasers. An FDA report. *Ophthalmol* 1985;92(2):209-12.
10. Steinert RF, Puliafito CA, Kumer SR, Dudak SD, Patel S. Cystoid macular edema, retinal detachment, and glaucoma after Nd:YAG laser posterior capsulotomy. *Am J Ophthalmol* 1991;112:373-80.
11. Patil MS, Balwir NB, Vidhate S:A study of Nd:YAG Laser capsulotomy in the management of posterior capsular opacification. *MVP J Med Sci* 2016;3(1):18-24.
12. Khan MY, JanS, Khan MN, Khan A, Kundi N. Visual outcome after Nd:yagcapsulotomy in posterior capsule opacification. *Pak J Ophthalmol* 2006;22(2):87-91.
13. Tasman W. Pseudophakic retinal detachment after YAG laser capsulotomy. *Aust New Zealand J Ophthalmol* 1989;17(3):277-9.
14. Jain S, Chandravanshi SL, Jain G, Tirkey E, Jain S. Effect of Nd:YAG laser capsulotomy in pseudophakic eyes with special reference to IOP changes. *J Evol Med Dent Sci* 2014;3(55):12627-35.
15. Keates RH, Steinert R F, Puliafito CA.Long term follow up of Nd:YAG laser posterior capsulotomy. *Am J Intraocular Implant Soc* 1984;10:164.
16. Flohr MJ, Robin AL, Kelly JS: Early Complications Following Q-switched Neodymium:YAG Laser Posterior Capsulotomy. *Am Acad Ophthalmol* 1985; 92(3): 360-3.

How to cite this Article: Joshi AK, Parashar A, Rasika K. Visual outcome of patients with posterior capsular opacification treated with Nd:YAG laser. *Int J Ocul Oncol Oculoplasty* 2019;5(3):103-7.