

Eyelid eccrine carcinoma – A case report

Uehara M. M. R.^{1*}, Enokihara M. M. S. S.², Allemann N.³, Okazaki C.⁴, Matsumoto F.K.⁵, Bison S. H. D. V. F.⁶, Osaki T. H.⁷

^{1,3,4,5,6,7}Dept. of Ophthalmology and Visual Sciences, ²Dept. of Pathology, São Paulo Federal University/Paulista School of Medicine, Brazil

***Corresponding Author: Mariah M. R. Uehara**

Email: mariahepm75@gmail.com

Abstract

Eccrine carcinoma is a rare sweat gland tumor also called as syringoid carcinoma. It comprises a malignant primary cutaneous neoplasm which prevalence increases from the fifth decade of life and has a high rate of local invasion. Other types of cutaneous tumors such as squamous cell and basal cell carcinomas and metastases of visceral adenocarcinomas are considered differential diagnoses. An anatomopathological examination with the immunohistochemical study is fundamentally important for this neoplasia diagnostic.

Keywords: Eccrine carcinoma, Syringoid carcinoma, Ductal eccrine carcinoma.

Introduction

Eccrine carcinoma (EC), also referred to as a syringoid⁸ or eccrine ductal carcinoma,⁹ is a rare tumor,¹⁰ comprising <0.01% of all cutaneous cancers and generally presenting either as an infiltrative plaque or a slow-growing solitary nodule on the scalp, extremities,⁹ trunk, cephalic region, and eyelids.^{3,4,7,8} EC manifests as a primary cutaneous tumor, and its prevalence increases from the fifth decade of life,⁹ affecting both male and female patients equally.^{2,7} There are reports of local invasion, local recurrence after surgical procedure,^{8,9} and, more rarely, distant metastases in the literature.^{4,5} The associated risk factors include immunosuppression, exposure to ultraviolet rays, and family history.³

EC has been originally described as a basal cell carcinoma with eccrine differentiation (under the name of eccrine epithelioma) and subsequently reported as an eccrine syringoid or eccrine syringomatous carcinoma, all characterized as malignant eccrine tumors.⁴

Differential diagnosis may include other types of malignant neoplasms such as squamous cell carcinoma, basal cell carcinoma, amelanotic melanoma or seborrheic keratosis,² as well as metastasis of visceral adenocarcinomas.^{5,6}

Case Report

A 49-year-old Caucasian male sought hospital emergency care presenting with a hardened nodular lesion in the right lower eyelid for a month that was rapidly growing (Fig. 1). His medical history revealed multiple diffuse skin lesions on the face and back of the hands diagnosed as squamous and basal cell carcinomas and actinic keratosis, for which he underwent surgical excision performed by the Dermatology team.

Ophthalmologic examination showed a corrected visual acuity of 20/20 in both eyes; tonometry and retinal funduscopy results, as well as extrinsic ocular motility and pupillary reflexes, were normal. Slit-lamp examination of both eyes revealed moderate meibomitis (2 + / 4 +), clear conjunctiva, clear cornea, trophic iris, and a wide anterior

chamber. The patient had a nodule in the medial-temporal portion of his right lower eyelid, which was approximately 10 × 10 mm large, hardened, mobile, without bone adherence, and a nonulcerated conjunctival fornix. He did not report weight loss and sweating, and there was no palpable lymph node enlargement.

Surgical treatment was performed under local anesthesia, including a complete excision of the lesion and free margins (the removed fragment had the dimensions 20 × 18 × 16 mm), and the remaining lower eyelid site was reconstructed using a tarsal-conjunctival flap by the Hughes technique at the same surgical time. The excised material was sent for complete anatomopathological study.

Postoperatively, the patient showed good progression, and the eyelid opening was performed in the fourth week in the ambulatory surgical center under local anesthesia. After 1 week of the second surgical procedure, he presented 2 + / 4 + soft tissue edema at the operative wound site without infectious characteristics (Fig. 2), which was treated by systemic corticosteroids and cold compresses. A partial improvement of the condition was noticed after 2 weeks; however, the patient subsequently developed chronic local eyelid edema. He was referred for oncological screening and investigation of distant metastases.

The anatomopathological study of the surgical specimen revealed a well-defined, homogeneous, whitish tumor presenting areas of necrosis, infiltration groups, 43 mitoses, and 10 large enlargement groups, which was defined as an EC. In the immunohistochemical analysis, carcinoembryonic antigen (CEA), BRST-2, epithelial membrane antigen (EMA) and androgen receptor antigens were tested, which showed a positive result for EMA, an inconclusive result for CEA, and a negative result for the other antigens. Finally, the diagnosis of EC of the sweat glands of the eyelid was made.

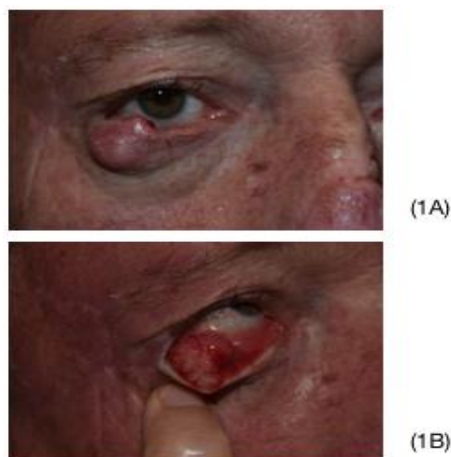


Fig. 1: (1A): Nodular lesion of the right lower eyelid. **(1B):** Conjunctival involvement of the lesion.

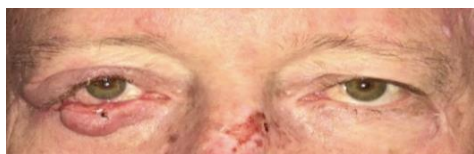

Fig. 2: Postoperative aspect (40th day) with chronic right lower eyelid edema.

Discussion

Considering the histology, the eccrine glands originate from the embryonic dermis during the first months of fetal development and are widely distributed throughout the skin^{1,6} (Fig. 3A). EC is composed of numerous tubular structures aligned by one or several layers of atypical basaloid cells;¹⁰ thin cords or similar nests may also occur in addition to

syringomatous foci⁸ that are frequently present.^{4,6} Some tumors are well differentiated with small ductal structures and may have clear variant cells or differentiation of the acrosyringium (Fig. 3A and 3B). A PAS-positive diastase-resistant material has been reported to be present in the lumen of these tubular structures.⁴

The tumor is centered in the dermis but often extends to the subcutaneous or deeper tissues. A perineural invasion is common just as an aggressive neoplastic transformation can be found.⁴

EC differs from microcystic adnexal carcinoma because it has areas with a basal cell pattern in contrast to the squamous features of the latter. However, some ECs may have syringoma-like ducts (Fig. 3D), but these are generally larger and better organized than those observed in microcystic adnexal carcinomas.^{4,5} Unlike these last type of carcinomas, EC has absent or minimal desmoplastic stroma but may also present sclerotic stroma.⁴

Since the cells of EC do not present specific microscopic characteristics, it is not possible to establish the lineage of the neoplasias based on the microscopic findings, which thus confirms the immense importance of immunohistochemical study.¹ Most of the cells express simple epidermal cytokeratins (CKs 7, 8, 18, 19), and a small number of cells express stratified epidermal cytokeratins (CKs 5, 14) showing positivity to CEA,¹⁰ EMA (Fig. 4A), and S100.^{1,8} The acrosyringium cells stain for high molecular weight keratin and CK 14, and a subpopulation of the cells also exhibit BCL-2 positivity. Some ECs are positive for androgen and estrogen receptors, and Ki-67 and ps53 markers can also be used for differentiating between benign and malignant lesions¹ (Fig. 4C).

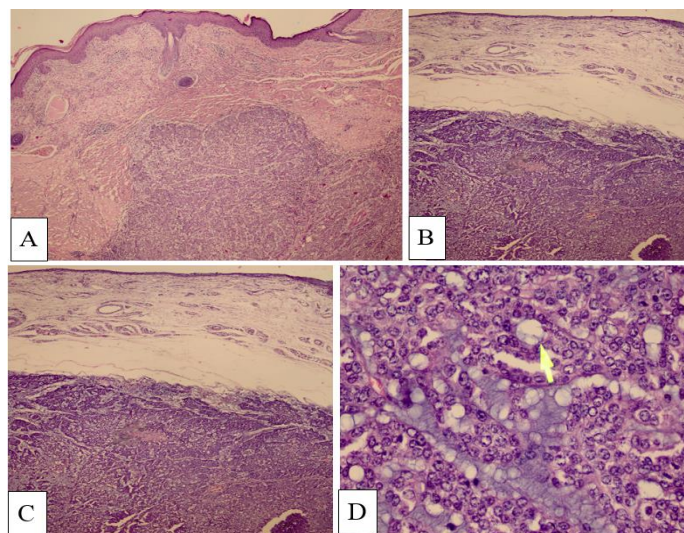


Fig. 3: Anatomopathological study of the surgical specimen excised from the right lower eyelid. **(3A):** In the eyelid skin aspect of the lesion, the neoplasia presented clusters of cubic cells with rounded nuclei and atypia. The neoplasia was considered as totally dermal and contained structures that outlined ductal arrangements (HE 40×); **(3B):** In the conjunctival aspect of the lesion, the neoplasia presented a similar appearance with arrangement in groups interspersed by ducts (HE 40×); **(3C):** Presence of nuclear atypia and ductal arteries (HE 100×); **(3D):** The arrow points to a ductal arrangement with lumen containing basophilic secretion and absence of decapitation, suggesting that it is an eccrine duct (HE 400×).

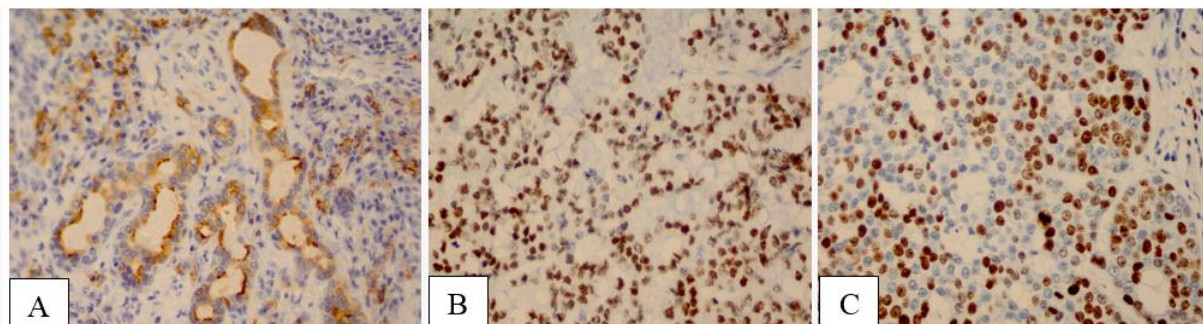


Fig. 4: Immunohistochemical study of the neoplastic lesion of the right lower eyelid (400×). **(4A):** Immunoexpression of the epithelial membrane antigen (EMA) marker; **(4B):** Immunoexpression of the p63 marker, which is also observed in eccrine carcinomas; **(4C):** Neoplastic nuclei showing various proliferation signs, characterizing the malignant nature of the lesion.

Elective treatment is total resection of the lesion with wide margins^{2,8} due to the high relapse rate and the significant mortality. Radiotherapy³ should be considered to prevent tumor recurrence or metastasi.^{4,3} However, Mohs surgery could be an appropriate form of treatment.^{4,5} The specific mortality rate has been reported to be 3.2%, and the survival rates at 1, 5, and 10 years have been reported to be 90%, 75%, and 60%, respectively. Men aged >60 years comprise patients with a worse prognosis.³

Conclusion

EC is a rare malignant neoplasia that should be included in the differential diagnosis of cutaneous tumors of the extremities and the cephalic region in patients aged >50 years.

Special thanks

Carlos Alberto Affonso Ferreira M.D, Vanessa El Mir M.D.

Conflict of Interest: None.

References

1. Serhrouchni KI, Harmouch T, Chbani L, Fatemi HE, Sekal M, Hammam N, Soughi M, Benchat L, Amarti A. Eccrine carcinoma: a rare cutaneous neoplasm. *Diagn Pathol* 2013;8:15. doi: 10.1186/1746-1596-8-15.
2. Leonhardt FD, Zanoni A, Ponce F, Haddad L, Scapulatempo Neto C, Cervantes O, Abrahão M. Eccrine sweat gland carcinoma. *Revista Brasileira de Otorrinolaringologia* 2007;73(2):286. doi: 10.1590/S0034-72992007000200024.
3. Gopinath S, Giambarberi L, Patil S, Chamberlain RS. Characteristics and survival of patients with eccrine carcinoma: A cohort study. *J Am Acad Dermatol* 2016;75(1):215-7. doi: 10.1016/j.jaad.2016.01.029.
4. Moy, R. L., Rivkin, J. E., Lee, H., Brooks, W. S., & Zitelli, J. A. Syringoid eccrine carcinoma. *J Am Acad Dermatol* 1991;24(5):857-60. doi: 10.1016/0190-9622(91)70133-m.
5. Weber P. J., Gretzula J. C., Garland L. D., Hevia O., & Menn, H. (1987). Syringoid eccrine carcinoma. *J Dermatol Surg Oncol* 1987;13(1):64-7. doi: 10.1111/j.1524-4725.1987.tb00498.x.
6. Krishnakumar S., Mohan E. R., Babu K., Das D., & Biswas J. (2003). Eccrine duct carcinoma of the eyelid mimicking meibomian carcinoma: clinicopathological study of a case. *Survey Ophthalmol* 2003;48(4):439-46. doi:10.1016/s0039-6257(03)00050-x.

7. Matos, Diogo. Carcinoma Ductal Écrino. *Revista da Sociedade Portuguesa de Dermatologia e Venereologia*, [S.l.], 2015;72(4):599-604.
8. Hoppenreijns VPT, Reuser TTQ, Mooy CM. Syringomatous carcinoma of the eyelid and orbit: a clinical and histopathological challenge. *Br J Ophthalmol* 1997;81:668-72.
9. Kacker, Ashutosh, and Ashok R. Shaha. Ductal eccrine carcinoma arising in the postaural area. *Ear, Nose Throat J*, 1999;576. Academic OneFile.
10. Urso, C., Paglierani, M., & Bondi, R. Histologic Spectrum of Carcinomas with Eccrine Ductal Differentiation (Sweat-Gland Ductal Carcinomas). *Am J Dermatopathol* 1993;15(5):435-40. doi:10.1097/00000372-199310000-00004.

How to cite this article: Uehara M. M. R, Enokihara M. M. S. S, Allemann N, Okazaki C, Matsumoto FK, Bison S.H.D.V.F, Osaki T. H. Eyelid eccrine carcinoma – A case report. *Int J Ocul Oncol Oculoplasty* 2019;5(2):100-2.