

Demography and clinical profile of patients of vernal keratoconjunctivitis in a tertiary eye care center of Bihar

Rajnee Sinha¹, Gyan Bhaskar^{2*}, M S Ali³, Anita Ambastha⁴, Aayushi⁵, Sandeep Kumar⁶

¹Junior Resident, ²Additional Professor, ^{3,4}Associate Professor, ⁵Senior Resident, ⁶Fellow IOL, ¹⁻⁵Regional Institute of Ophthalmology, IGIMS, Patna, Bihar, ⁶Sankara Eye Hospital, Kanpur, Uttar Pradesh, India

***Corresponding Author: Gyan Bhaskar**

Email: drgyan6@gmail.com

Abstract

Objective: To know the demography and clinical profile of patients of vernal keratoconjunctivitis (VKC) presented in the out-patient department of regional institute of ophthalmology (RIO), IGIMS Patna, Bihar over a period of 1 year from May 2017 to April 2018.

Materials and Methods: This was a retrospective study done on diagnosed patients of vernal keratoconjunctivitis. Out of total 25344 OPD patients, 1267 patients were in age group of 1-25 years and either sex. Out of which 240 patients were included in this study had diagnosis of vernal keratoconjunctivitis (VKC) on the basis of their history, symptoms and clinical findings. Detailed history was taken from each patient including age at the onset of the disease, gender of the patient, any seasonal variations, his/her place of residence, any associated allergic or "atopic" illnesses. Thorough examination was done to find out visual acuity, condition of cornea, limbus, bulbar, palpebral conjunctiva and associated complications.

Results: Out of 240 patients, VKC was more common in male (86.66%) than female (13.33%) patients with maximum cases seen between 6-10 years of age. Majority of cases reported in summer in the month of May and June. Palpebral form was predominant among all that is around 174(72.5%) cases followed by mixed 50(20.83%) and Limbal form 16 (6.66%). Most common symptom was itching (100%) seen in almost all cases. Palpebral papillae were commonest sign. Associated allergic conditions were found in 16 (6.66%) patients.

Conclusion: Vernal keratoconjunctivitis is a recurrent bilateral disorder in which both IgE and cell mediated immunity play important roles. It primarily affects boys and onset is generally from about age of 5 years onwards and resolves around puberty. The clinical course of this disease is usually benign and self-limiting, with vision in most children remains normal but sight threatening complications may manifest if cornea gets involved. Few cases showed history of atopy and other allergic conditions. VKC is one of the leading causes of outpatient ophthalmic morbidity.

Keywords: Palpebral, Bulbar, Allergic, Atopic, Keratoconjunctivitis.

Introduction

Spring catarrh is another name of vernal keratoconjunctivitis (VKC). It is a chronic, bilateral, at times asymmetrical, seasonally exacerbated conjunctivitis occurring with the onset of hot weather. Observed mostly in children and young adults presenting with complaints of severe itching and photophobia accompanied by ocular discomfort and lacrimation.^{1,2} It primarily affects boys and onset is generally from about age of 5 years onwards and resolves around puberty. The disease is more common among males, the male to female ratio varying from 4:1 to 2:1. The clinical course of this disease is usually benign and self-limiting, with vision in most children remains normal but sight threatening complications may manifest if cornea gets involved. Family history of allergic disorders such as asthma, rhinitis, eczema, urticaria and multiple atopic diseases was reported in 49% of patients suffering from VKC. In its typical form, VKC presents with intense itching, which may be associated with lacrimation, photophobia, a foreign body sensation, burning and thick mucoid discharge.

Ropy discharge is a characteristic of VKC. Horner-Trantas's dots are most common sign of VKC characterized by transient limbal or conjunctival yellow-white points or deposits and are degenerating eosinophils and epithelial cell debris. Large (> 1 mm) papillae in VKC occur predominantly at the upper tarsus. Papillae that may attain a size of 7-8 mm are known as cobblestone papillae. Papillae

size correlate positively with the persistence or worsening of symptoms over long-term follow-up.³

Based on the predominant involvement of either tarsal or limbal conjunctiva, VKC can be divided into palpebral, limbal or mixed type with limbal forms being prevalent in non-White patients.⁴ The mixed form is characterized by the presence of both forms in the same eye. While it is considered a long-term disease with an average duration of 4-8 years, VKC generally subsides before or just after puberty.⁵⁻⁷ Photophobia, pain and foreign body sensation are caused by involvement of the cornea. Corneal changes include punctate epithelial keratitis, epithelial macroerosions, shield ulcer, plaque formation and late corneal vascularization.^{8,9}

The clinical course of VKC seems to have geographical variations. Therefore, this retrospective study was done to know the demographic and clinical profile of disease in our geographical area, where patients come from all districts of Bihar and surrounding states.

Materials and Methods

This was a hospital based retrospective and observational study conducted in a tertiary eye care hospital in Patna, Bihar. Data were collected from a total of 25344 new registered patient in OPD, in which 1267 patients were 01-25 years of age and either sex. Out of 1267 patient, 240 patients were diagnosed as VKC, based on history, symptoms and clinical findings.

Study was conducted over a period of 1 year between May 2017 to April 2018. All those patients in age group of 1-25 years coming to opd with complain of itching, redness, foreign body sensation, history of any associated allergy, mucoid discharge underwent proper clinical evaluation including slit lamp evaluation to look for associated signs including palpebral papillae, ropy discharge, horner-tranta spots, any corneal findings, best corrected visual acuity, fundus examination, signs of any recurrence. History was taken of all diagnosed cases of vkc including age of onset of disease, place of residence, any seasonal variations, associated allergic illnesses.

Inclusion Criteria

1. All patients who had history of itching, redness, photophobia, lacrimation and mucous discharge were included in the study.
2. Age 1 year to 25 years of either sex

Exclusion Criteria

Patients with history of contact lens induced conjunctivitis, other ocular diseases and trauma were excluded from the study.

Type of VKC

- A. **Palpebral form of VKC**- Papillae of size > 1mm on upper palpebral conjunctiva with no limbal infiltration implies the palpebral form of VKC.
- B. **Limbal form of VKC**- Papillae of < 1 mm on the upper palpebral conjunctiva with limbal infiltration marked the limbal form of VKC.
- C. **Mixed VKC** - features of both limbal and palpebral form.

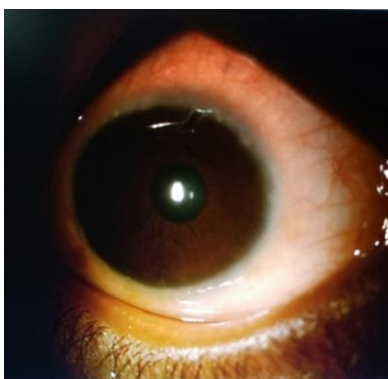


Fig. 1: Limbal form

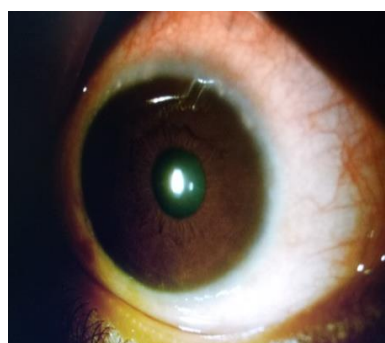


Fig. 2: Limbal form

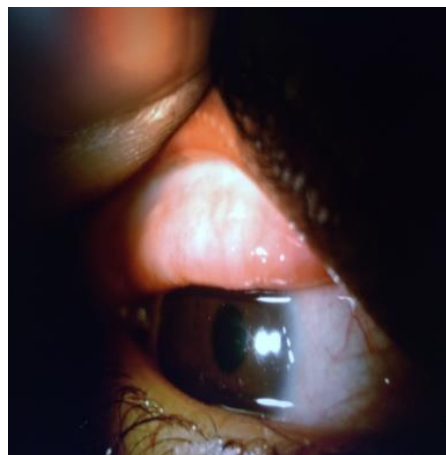

Fig. 3: Palpebral form

Results

Out of 1267 patients of age group 1- 25 years, 240 patients (19%) were diagnosed as VKC, in which males were 208 (86.66%) and females were 32 (13%, Table 1). Maximum cases were seen in 6-10 years of age which were 120 (50%, Table 2). Majority of cases reported in the month of May and June 40 and 45 respectively it was 85(35%, Table 3).

According to symptom profile (Table 4), 240 (100%) cases presented with itching, redness was seen in 120 (50%) cases, photophobia in 60 cases (25%), ropy discharge in 40 cases (16.66%), and foreign body sensation in 40 cases (16.66%).

According to disease pattern (Table -5) it was found that Palpebral form in 174 cases (72.5%), mixed form in 50 cases (20.83%), limbal form in 16 cases (6.67%). 190 cases (79.16%) had papillae on upper palpebral conjunctiva, 82 cases (34.16%) had conjunctival congestion, 40 cases (16.66%) had SPKs and limbal papillae, and 22 cases (14.67%) had Horner tranta's spots. Coexisting allergic conditions was found in only 16 (6.66%) patients.

Table 1: Gender distribution

Gender	No. of cases
Male	208 (86.66%)
Female	32 (13.33%)

Table 2: Age distribution

Age range (in years)	No. of cases (%)
1-5	16 (6.66)
6-10	120 (50)
11-15	70 (29.16)
16-20	26 (10.83)
21-25	08 (3.33)
Total	240

Table 3: Month wise distribution

Months	No. of patients
January 2018	13
February 2018	21
March 2018	25
April 2018	27
May 2017	40
June 2017	45
July 2017	23
August 2017	15
September 2017	13
October 2017	6
November 2017	7
December 2017	5

Table 4: Distribution of patients by symptoms

Symptoms	No. of cases
Itching	240 (100)
Redness	120 (50)
Photophobia	60 (25)
Ropy discharge	40 (16.66)
Foreign body sensation	40 (16.66)

Table 5: Clinical types of VKC

Types	No. of cases (%)
Palpebral	174 (72.5)
Limbal	16 (6.6)
Mixed	50 (20.83)
Total	240

Table 6: Ocular signs in VKC patients

Ocular signs	No. of cases (%)
Papillae on upper palpebral conjunctiva	190 (79.16%)
Conjunctival congestion	82 (34.16%)
SPKs and limbal papillae	40 (16.66%)
Horner tranta's spots	22 (14.67%)

Discussion

Vernal keratoconjunctivitis is a recurrent bilateral disorder in which both IgE and cell mediated immunity play important roles. It primarily affects boys and onset is generally from about age of 5 years onwards. Which is consistent with our study as most of the cases were seen in 6-10 years of age group. This is in accordance with the study conducted by Kawuma M, which found the commonest presentation with VKC to be between 5 and 9 years of age.¹⁰ Saboo US et al. reported male preponderance (M: F ratio 6.4:1) in their study.¹¹ which was also seen in our study as males were 208 as compared to females which were around 32 in number and Male: Female ratio was 6.5:1. 8 cases (3.33%) in this study group were more than 20 years of age which is in accordance with that of Leonardi et al. who found 4% of patients above 20 years of age.^[12] Different environmental and geographical variations may be responsible for such varied demography.

The study conducted by Jivange VS et al., reported highest incidence in hot and dry season which is also seen in our study as most of the patients gave history of onset of disease in summer season.¹³ 6.66% of patients in our study had associated history of allergy which is in accordance with the study of Saboo US et al. where personal or family history of allergy was present in 4.91% of patients.¹¹

In this study most common complain given by patient was itching in almost all cases (100%), followed by other symptoms like redness, photophobia, thick mucoid discharge, few cases had corneal complications in the form of superior punctuate epithelial erosions, plaques and shield ulcer. The predominant type of VKC found in our study was of the palpebral form (72.5%) followed by mixed (20.83%) and limbal (6.66%) form which is in consistent with Rajappa et al. who found palpebral form as the predominant form in their study.¹⁴ This signifies that the prevalence of subtypes of VKC is different in various parts of the world. This study has some important limitations. Much of the data is self-reported and subject to recall bias from the subjects. Another limitation was retrospective nature from a hospital-based eye center; hence the data may not represent the exact characteristic of patient treated in a community center.

Conclusions

Vernal keratoconjunctivitis is a recurrent bilateral disorder in which both IgE and cell mediated immunity play important roles. It primarily affects boys and onset is generally from about age of 5 years onwards and resolves around puberty. Few cases showed history of atopy and other allergic illnesses. It is mostly seen in tropical countries like our which has warm and dry climate. So, after knowing the geographical trend and clinical profile of VKC in our region, we can make the treatment plan and preventing measures can be taken for recurring cases.

Source of Funding: Self.

Conflict of Interest: None.

Ethical Clearance: Taken.

References

1. Shoja MR, Besharati MR. Evaluation of keratoconus by videokeratography in subjects with vernal keratoconjunctivitis (VKC). *J Res Med Sci* 2006;11:164-9.
2. Attarzadeh A, Khalili MR, Mosallaei M. The potential therapeutic effect of green tea in treatment of vernal keratoconjunctivitis. *Im J Med Hypotheses Ideas* 2008;2:21.
3. Bonini S, Bonini S, Lambiasi A. Vernal keratoconjunctivitis revisited. A case series of 195 patients with long-term follow-up. *Ophthalmol* 2002;107:1157-1163.
4. Verin PH, Dicker ID & Mortemousque B. Nedocromil sodium eye drops are more effective than sodium cromoglycate eye drops for the long-term management of vernal keratoconjunctivitis. *Clin Exp Allergy* 1999;29:529-36.
5. Leonardi A, Bogacka E, Fauquet JL, et al. Ocular allergy: recognizing and diagnosing hypersensitivity disorders of the ocular surface. *Allergy* 2012;67(11):1327-37.
6. Leonardi A. Vernal keratoconjunctivitis: pathogenesis and treatment. *Prog Retin Eye Res* 2002;21(3):319-39.

7. Bonini S, Lambiase A, Marchi S, et al. Vernal keratoconjunctivitis revisited: a case series of 195 patients with long-term followup. *Ophthalmol* 2000;107(6):1157–63.
8. Allansmith MR & Ross RN (1988): Ocular allergy. *Clin Allergy* 1988;18:1-136.
9. Buckley RJ (1988): Vernal keratoconjunctivitis. *Int Ophthalmol Clin* 28: 303–8.
10. Kawuma M. The Clinical picture of Vernal KeratoConjunctivitis in Uganda, *Community Eye Health*. 2001;14:60-7.
11. Saboo US, Jain M, Reddy JC. Demographic and clinical profile of vernal keratoconjunctivitis at a tertiary eye care centre in India. *Ind J Ophthalmol* 2013;61:486-9.
12. Leonardi A, Busca F, Motterle L. Case series of 406 vernal keratoconjunctivitis patients: A demographic and epidemiological study. *Acta Ophthalmol Scand* 2006;84:406-10.
13. Jivangi VS, Raikar HA, Khatib ZI. Clinical profile of patients with vernal kerato conjunctivitis. *Int J Res Med Sci* 2015;3:2831-4.
14. Rajappa SA, Fatima F and Avinash S. A clinical study of Vernal Keratoconjunctivitis. *IJBR* 2014;5:04.

How to cite this article: Sinha R, Bhaskar G, Ali MS, Ambastha A, Aayushi, Kumar S. Demography and clinical profile of patients of vernal keratoconjunctivitis in a tertiary eye care center of Bihar. *Int J Ocul Oncol Oculoplasty* 2019;5(2):90-3.