

Retropupillary fixated iris claw lens -an option for aphakia management

Sakshi Patil¹, Navneet Chhabda^{2*}, Ajit Joshi³

¹Associate Professor, ²Junior Resident, ³Professor and HOD, Bharati Vidyapeeth (Deemed to be University) Medical College and Hospital, Sangli, Maharashtra, India

***Corresponding Author: Navneet Chhabda**

Email: schhabda@rediff.com

Abstract

Aim: To study visual and surgical outcome in aphakic patients after implantation of retropupillary fixated iris claw lens.

Materials and Methods: Medical records of the patients operated in Bharati Hospital, Sangli for the treatment of aphakia by secondary retropupillary fixated iris claw lens from September 2017 to August 2018 were included in the study. The data collected included the preoperative best corrected visual acuity (BCVA), auto-refractokeratometry, anterior segment evaluation on the slit lamp and posterior segment evaluation done by indirect ophthalmoscopy after pupillary dilatation with tropicamide eyedrops. The patients were also assessed for lacrimal sac patency and Goldmann applanation tonometry for intraocular pressure (IOP). Intraocular lens (IOL) power was calculated by SRK-T formula in aphakic mode by immersion based biometry. At follow up i.e. day 7 and 1 month, findings of patients include in study were BCVA, slit lamp examination and auto-refractokeratometry.

Results: 86.66% patients operated by retropupillary fixated iris claw lens had postoperative improvement in visual acuity as compared to preoperative visual acuity.

Conclusions: Retropupillary fixated Iris claw lens is an effective method of aphakia management with good visual outcomes and easy learning curve.

Keywords: Aphakia, Iris claw lens, Visual acuity.

Introduction

Cataract surgeries are one of the most common ophthalmic surgeries performed by ophthalmologists.¹ A cataract surgery aims at removal of cataractous lens with 'in the bag' placement of Intraocular Lens (IOLs). One of the complications of cataract surgeries include posterior capsular rent. This leads to inadequate capsular support preventing in the bag placement of IOL.

Various IOL options are available for use in this scenario which include anterior chamber (ACIOL), scleral fixated (SFIOL), and iris fixated IOL either anterior or posterior.²⁻⁵ Each of these variety of IOLs have their merits and demerits. ACIOLs are known to have a high risk of corneal decompensation and glaucoma.⁶ Scleral-fixated IOLs preserve anatomical integrity but are technically challenging and time-consuming with few intraoperative and postoperative complications such as suture erosion, IOL-related complications and rarely retinal detachment.⁷ Iris-claw IOLs compensate the corneal complications noted in ACIOLs and are technically less challenging and less time-consuming than SFIOL implantation.⁸ Retropupillary fixation of iris-claw IOLs preserve the anatomy of anterior segment and is associated with good visual outcome with a low incidence of intraoperative and postoperative complications.^{9,10}

In our study, we retrospectively analysed the post-operative best corrected visual acuity (BCVA) and complications of patients operated by retropupillary fixated iris claw lens.

Materials and Methods

The study was conducted in the department of Ophthalmology, Sangli during the period of March 2019 to

May 2019 after taking the approval from the college ethical committee (ethical committee approval letter number 337/19).

Medical records of the patients operated for treatment of aphakia by secondary retropupillary fixated iris claw lens from September 2017 to August 2018 in department of Ophthalmology and fulfilling the inclusion criteria were included in the study.

The inclusion criteria was patients who were kept aphakic because of cataract surgery complication and underwent retropupillary fixated iris claw lens fixation secondarily.

The patients with corneal opacity, glaucoma, iris trauma or damage and posterior segment pathology were excluded from the study.

The data collected included the preoperative best corrected visual acuity (BCVA), automated keratorefractometry by NIDEK auto-refractometer, findings of anterior segment evaluation on the slit lamp for any corneal pathology or pupillary distortion and findings of posterior segment evaluation done by indirect ophthalmoscopy after dilating the pupils by tropicamide eyedrops. The readings of patient's intraocular pressure recorded by applanation tonometry, lacrimal sac patency and IOL lens power calculated by SRK-T formula in aphakic mode by immersion-based biometry were taken into account. The details of patients recorded at each follow up (at day 7 and 1 month) including BCVA, slit lamp examination and auto-refractokeratometry were taken for the study.

Surgical Method

The patients were operated under all aseptic precaution by a single surgeon. The eye to be operated was painted with

10% betadine and draped. Universal eye speculum was inserted, separating the eyelids. Two sideports were made at 3 and 9 o'clock. After taking 5.5 mm sclerocorneal incision, tunnel was made superiorly in patients who were operated by phacoemulsification for cataract surgery. In the patients operated by Small Incision Cataract Surgery (SICS), the previously made tunnel was reopened. Vitrectomy probe and irrigation probe were inserted in the Anterior Chamber (AC) from 3 and 9 o'clock. Using the Alcon Infinity machine, anterior vitrectomy was performed at the cut rate of 2000/sec with low irrigation. Viscoelastic substance was injected in AC. Iris claw lens was inserted in AC and then repositioned in retropupillary position with haptics at 3 and 9 o'clock and centralized. The IOL's haptic was held with special forcep and tucked with the enclaver in iris. Peripheral Iridectomy (PI) was done at 1 o'clock in patients who did not have patent PI after the primary surgery. After aspirating viscoelastic material, intracameral moxifloxacin (Auromax 0.5% w/v) was put in the AC. The sideports were hydrated. Subconjunctival injection of 0.1ml gentamicin (80mg/2ml) and 0.1ml dexamethasone (4mg/ml) was given and eye padded after instilling chloramphenicol eye ointment.

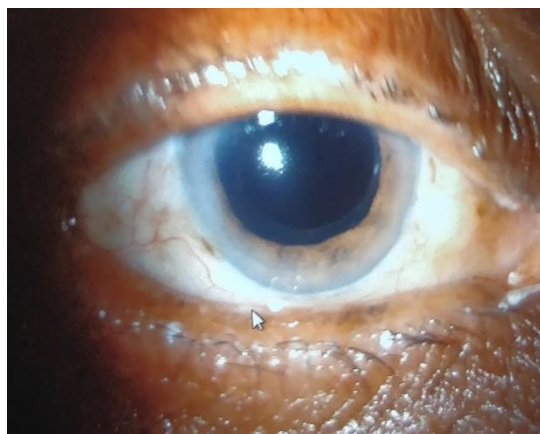


Fig. 1: Image showing patient with surgical aphakia

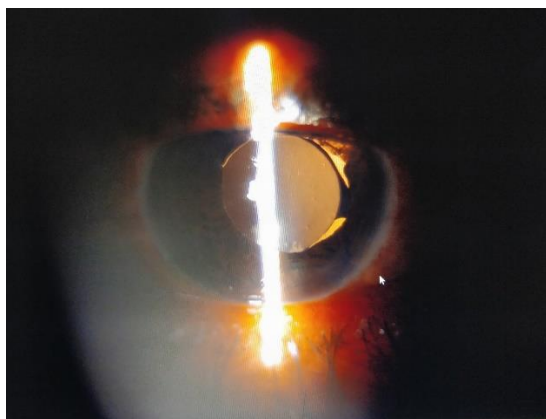


Fig. 2: Post-operative picture of patient operated by retropupillary fixated iris claw lens (in retroillumination)

Results

Out of the fifteen patients, 8 were male and 7 were female (Fig. 3).

Table 1: Sex-wise distribution of patients

Gender	No. of patients
Male	8
Female	7

Table 2: Age-wise distribution of patients

Age of patients	No. of patients
51-60 years	5
61-70 years	7
71-80 years	3
Total	15

Among the 15 patients, most of the patients (7) were among the age group of 61 to 70 years (see table 2), followed by 5 patients in the age group of 51 to 60 years and 3 patients in the age group of 71-80 years.

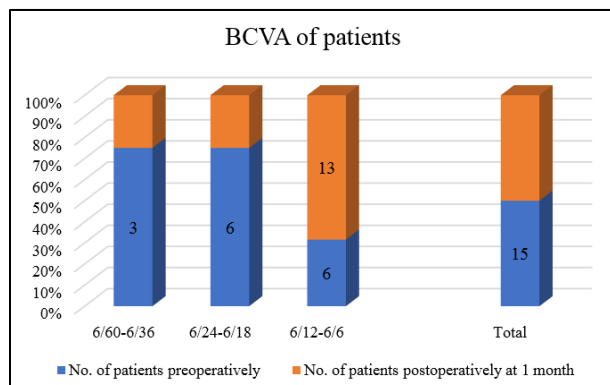
Table 3: Distribution of patients according to causes of surgical aphakia (Posterior capsular rupture)

Causes of surgical aphakia	No. of patients
Mature cataract	3
Zonular dehiscence	2
Small pupil	2
Pseudoexfoliation	3
Inexperienced surgeon	5
Total	15

Cataract surgeries performed by trainee surgeons in a teaching hospital like ours led to most cases of surgical aphakia of which 5 (see table 3) cases were part of the study. Other causes of posterior capsular rupture included cataract surgeries performed in patients with mature cataract (3), pseudoexfoliation (3), mature cataract (2), small pupil (2) and zonular dehiscence (2).

Table 4: Distribution of patients according to Best Corrected Visual Acuity (BCVA) pre retropupillary fixated iris claw fixation and post iris claw fixation

Range of Best corrected visual acuity (BCVA)	No. of patients in whom aphakic vision is recorded(pre retropupillary fixated iris claw lens implantation)	Percentage	No. of patients postoperatively at 1 month (post retropupillary iris claw lens implantation)	Percentage
6/60-6/36	3	20%	1	6.66%
6/24-6/18	6	40%	2	13.33%
6/12-6/6	6	40%	13	86.66%
Total	15	100%	15	100%

**Fig. 4:** Distribution of patient according to BCVA pre and post retropupillary fixated iris claw lens implantation

At 1 month post-operative 6.66% had BCVA of 6/60-6/36. There were 13.33% patients with BCVA of 6/24-6/18. In most of the patients i.e.86.66% (Fig. 4). The BCVA improved to 6/12-6/6 at 1 month post-operative. Thus, 86.66% (see table 4) of patients had a significant visual improvement.

Table 5: Distribution of patients according to complications

Complication	No. of patients
Yes	3 (1 CME,1 Post operative corneal edema, 1 ovalisation of pupil)
No	12

Most of the cases were not associated with any complication (Table 5). One patient had ovalisation of pupil instead of the circular pupil post-surgery due to improper centration of the iris claw lens. Post operatively on day 1 and day 7, one patients had corneal edema with raised intraocular pressure (IOP). One patient developed Cystoid Macular Edema (CME) in the post-operative period due to which the patient's BCVA was 6/36.

Discussion

Aphakia is one of the common complications of cataract surgeries caused due to posterior capsular rent during surgery. Of the various modalities of treatment retropupillary fixated iris claw lens were used in our study to manage such patients.

At the postoperative period of 1 month, 86.66% of patients had BCVA of 6/12 to 6/6 on Snellen's visual acuity

chart. This is comparable with the post-operative visual outcome results obtained in studies conducted by Gonnermann et al⁹ and Proddatoori et al.¹¹

One case developed cystoid macular edema at 7 days post-operative and had BCVA counting finger 3 meters. Macular Optical Coherence Tomography (OCT) confirmed the diagnosis and he was started on 0.1% nepafenac eye drops thrice a day. The post-operative visual acuity at 1 month in this patient improved to 6/36. As the patient did not follow up after 1 month, so we could not access status of his macular edema further.

One patient had post-operative corneal edema and raised IOP which was managed conservatively with tablet Acetazolamide 250 mg twice a day for 3 days along with Timolol eyedrops twice a day for ten days. The patient recovered with this treatment at one month postoperatively.

Post operatively, one patient had ovalisation of pupil due to asymmetric haptic fixation.¹² In similar study conducted by Proddatoori et al. they had 17 patients with pupil distortion.

The other complications of Iris claw lens like de-enclavation and dislocation were not seen in our study.

Limitations

As the study duration was short, long term complications of Iris claw lens could not be studied. The sample size of the study was small so the various tests of significance were not applicable for statistics.

Conclusion

Retropupillary fixated iris claw lens implantation helps in management of aphakia with good postoperative outcome in terms of visual acuity. With an easy learning curve as compared to SFIOL and less complications as compared to ACIOL like corneal endothelial decompensation, retropupillary fixated iris claw lens is a good alternative for aphakia management.

Conflict of Interest: None.

References

- Lahane TP. Tackling the cataract backlog – An initiative by the Maharashtra State, India. *Indian J Ophthalmol* 2018;66:1391-3.
- Rao R, Sasidharan A. Iris claw intraocular lens: A viable option in monocular surgical aphakia. *Indian J Ophthalmol* 2013;61:74-5.

3. Gicquel JJ, Langman ME, Dua HS. Iris claw lenses in aphakia. *Br J Ophthalmol* 2009;93:1273-5.
4. Evereklioglu C, Er H, Bekir NA, Borazan M, Zorlu F. Comparison of secondary implantation of flexible open-loop anterior chamber and scleral-fixated posterior chamber intraocular lenses. *J Cataract Refract Surg* 2003;29:301-8.
5. Jare NM, Kesari AG, Gadkari SS, Deshpande MD. The posterior iris-claw lens outcome study: 6-month follow-up. *Indian J Ophthalmol* 2016;64:878-83.
6. Snellingen T, Shrestha JK, Huq F, Husain R, Koirala S, Rao GN, et al. The South Asian cataract management study: Complications, vision outcomes, and corneal endothelial cell loss in a randomized multicenter clinical trial comparing intracapsular cataract extraction with and without anterior chamber intraocular lens implantation. *Ophthalmol* 2000;107:231-40.
7. Teng H, Zhang H. Comparison of artisan iris-claw intraocular lens implantation and posterior chamber intraocular lens sulcus fixation for aphakic eyes. *Int J Ophthalmol* 2014;7:283-7.
8. Schallenberg M, Dekowski D, Hahn A, Laube T, Steuhl KP, Meller D, et al. Aphakia correction with retropupillary fixated iris-claw lens (Artisan) - long-term results. *Clin Ophthalmol* 2014;8:137-41.
9. Gonnermann J, Klamann MK, Maier AK, Rjasanow J, Jousen AM, Bertelmann E, et al. Visual outcome and complications after posterior iris-claw aphakic intraocular lens implantation. *J Cataract Refract Surg* 2012;38:2139-43.
10. Helvaci S, Demirduzen S, Oksuz H. Iris-claw intraocular lens implantation: Anterior chamber versus retropupillary implantation. *Indian J Ophthalmol* 2016;64:45-9.
11. Proddatoori KK, Jajapuram SD, Pyda S, Zamrudh S. Retropupillary fixated iris-claw lens: An effective alternative for aphakia. *J Clin Ophthalmol Res* 2018;6:91-4.
12. Forlini M, Soliman W, Bratu A, Rossini P, Cavallini GM, Forlini C, et al. Long-term follow-up of retropupillary iris-claw intraocular lens implantation: A retrospective analysis. *BMC Ophthalmol* 2015;15:143.

How to cite this article: Patil S, Chhabda N, Joshi A. Retropupillary fixated iris claw lens -an option for aphakia management. *Int J Ocul Oncol Oculoplasty* 2019;5(2):76-9.