

Pediatric orbital inflammatory myofibroblastic tumor: A rare case

Shashidhar V. S^{1,*}, Manju Kumari²

¹Consultant, ²Fellow, ^{1,2}Dept. of Orbit and Oculoplasty, ^{1,2}Sankara Eye Hospital, Bangalore, Karnataka, India

*Corresponding Author: Shashidhar V. S

Email: shashvasi@yahoo.com

Abstract

This case report highlights, a 4 year old female child with gradually increasing exophytic mass involving eye ball in right orbit. Enucleation with mass excision was done and histopathological examination reported the diagnosis of inflammatory myofibroblastic tumor (IMT). These are benign tumors of unknown etiology. We are reporting this case to enlighten on considering IMT as differential diagnosis of solid tumors in orbit and also early diagnosis and treatment can save vision and eye.

Keywords: Pseudotumor, Plasma cells, Orbital mass, Pseudoneoplasia, IMT.

Introduction

The exact etiology of IMT is not known, it is also been referred as xanthomatous pseudotumor / pseudosarcomatous myofibroblastic proliferation. IMT is considered as a pseudoneoplastic Inflammatory condition with diverse morphology.¹ IMT occurrence in orbit though rare is been described to occur in other organs like lungs and abdomen. It is known to be characteristically recurrent and locally invasive.

Case Report

A 4 year old female, presented to oculoplasty department of our hospital with complaints of gradually increasing mass in right eye over 2 years. She was diagnosed as right eye retinoblastoma (elsewhere). On examination, there was a large greyish white cauliflower like mass projecting out of right orbit with areas of blood clots and crusts on the surface, obscuring the eyeball (Fig. 1). Left eye was within normal limits. Regional lymph nodes, preauricular and submandibular were enlarged and non tender.

Blood investigations, consisting of full blood count, liver function tests, peripheral blood smear examination, renal function tests were normal. USG abdomen, bone marrow aspiration cytology, CSF analysis, X-ray chest were also performed and were unremarkable. MRI and CT scan of brain and orbit showed right sided, intensely enhancing extraconal and exophytic soft tissue mass lesion encompassing anterior and inferolateral periorbital region with mass effect on the globe (Fig. 2) and involvement of inferior rectus, inferior oblique (Fig. 4) lateral rectus and medial rectus (Fig. 3). Mass was measuring approximately 5.3 x 4.4 x 3.8 cm, optic nerve was normal, there was no evidence of bony destruction, focal involvement of the cornea with anterior camber and displacing lens laterally noted. Multiple deep and superficial enlarged parotid lymph nodes were seen.

Extended enucleation along with mass was performed and sent for histopathological examination. Postoperative period was uneventful (Fig. 5). Childs' parents were counseled about using prosthetic eye for cosmesis.

HPE showed, partly circumscribed lesion with focal stratified squamous epithelial lining and composed of spindle cell proliferation in fascicles and sheets separated by compact fibrovascular stroma (Fig. 6). These cells have vesicular elongated nucleus and moderate amount of eosinophilic cytoplasm. No definite atypia or necrosis noted. Stroma showed moderate to dense mixed inflammation, in addition, foam cells and reactive lymphoid follicles in stroma, areas of calcification, edema, myxoid, collagenous stroma and proliferating blood vessels were noted. Inflammatory cells were seen infiltrating extraocular muscles, however no infiltration into the eyeball contents noted. The histopathological finding were suggestive of IMT.

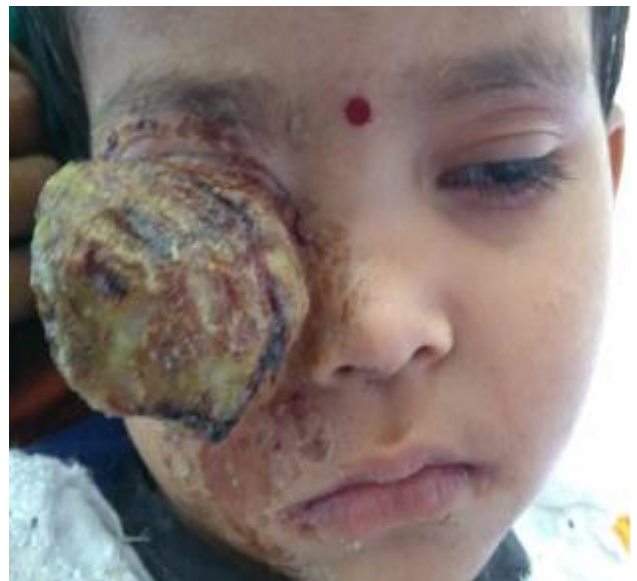

Fig. 1: Clinical picture of child.

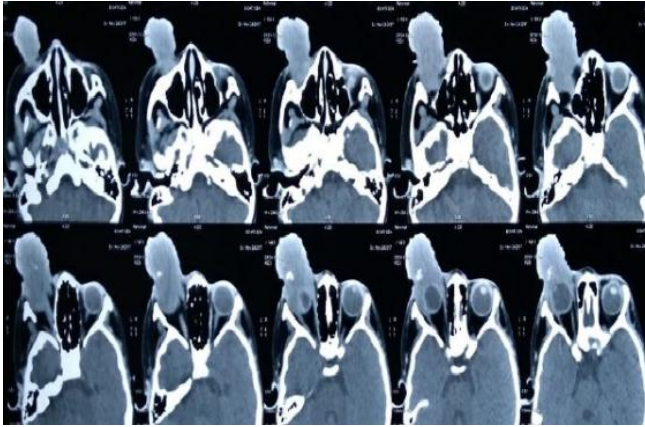


Fig. 2: CT scan axial section showing mass lesion encompassing anterior and inferolateral periorbital region with mass effect on the globe and involvement of lateral rectus and medial rectus. Mass was measuring approximately 5.3 x 4.4 x 3.8 cm.

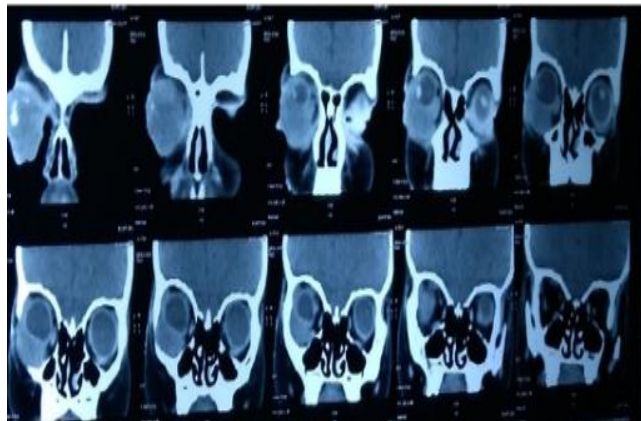

Fig. 3: CT scan coronal section showing globe distortion with involvement of inferior rectus and inferior oblique muscle.

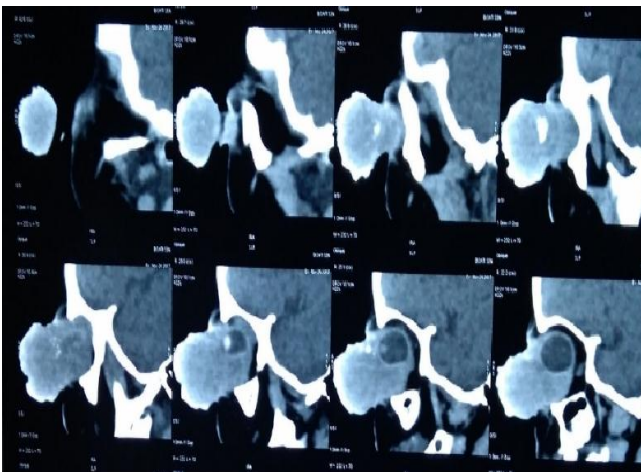


Fig. 4: CT scan sagittal section showing the involvement of cornea and anterior of eye.

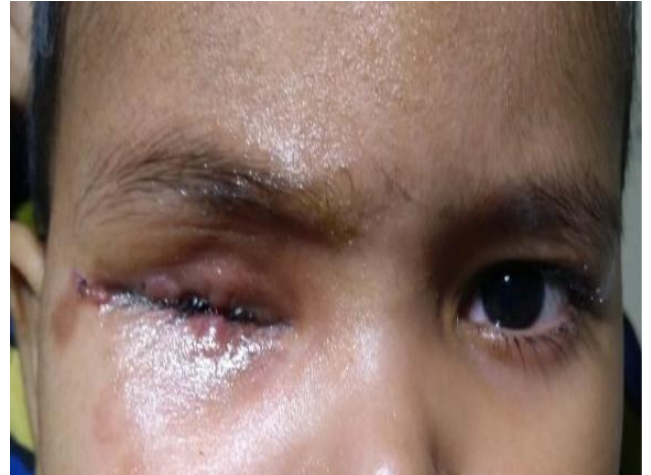

Fig. 5: One week postoperative picture of child.

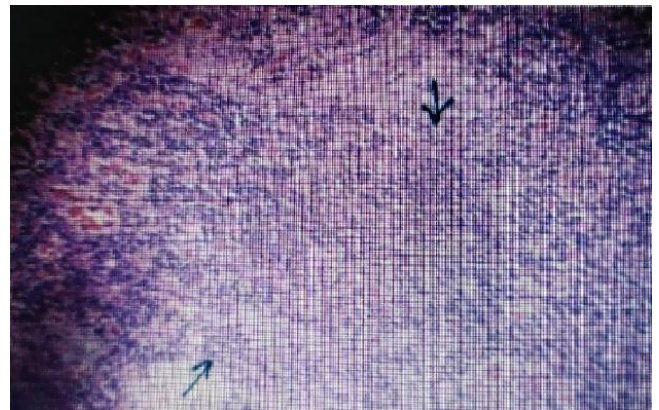


Fig. 6: histopathology slide showing features suggestive of IMT fibrous stroma infiltrated by plasma cells and lymphocytes.

Discussion

IMT of orbit is a rare benign condition. Low grade malignant transformation into sarcomas has been reported, but overall prognosis is favorable.^{2,3} It is composed of differentiated myofibroblastic spindle cells with plasma cells and /or lymphocytes.^{3,4} It commonly occurs in children and young adults, with no sexual or racial predilection.^{1,5} Due to its prevalence in pediatric patients, a differential diagnosis of rhabdomyosarcoma should be kept in mind. IMT is considered as a benign pseudoneoplastic inflammatory condition with varied presentations. It is known to recur and is locally invasive.

Presentation of IMT varies depending on the location, like diplopia with subconjunctival mass, painful proptosis, painless gradual diminution of vision, orbital mass with multiple neuropathy or phthisis.^{1,6-10} Our patient presented with a large exophytic orbital mass. Mass arising from the perilimbal area in an eighteen-month-old boy was most similar to our case.⁶ It should be noted that most of the reported cases were in male and our case was in female.

HPE of the orbital lesion in our case, revealed proliferating spindle cells, which are suggestive of IMT. Immunohistochemistry for anaplastic lymphoma kinase - 1

(ALK-1) is a useful indicator of chromosomal abnormality seen in IMT. However, ALK immunoreactivity has been reported only in 36% to 60% of cases.^{3,9}

Immunohistochemistry was not done in our case because of unavailability. In HPE of our patient and other case reports, the prominent cell type has been spindle cells. This tumor also invariably shows positive immunoreactivity for SMA, vimentin, and capolin.^{1,8,11}

IMT is an idiopathic condition, possible reported causes include autoimmune reaction, T and B cell lymphoma and trauma. Associations between IMT and infections with mycoplasma, Epstein Barr virus, mycobacterium, actinomycetes has been reported.^{3,12} CT scan of our case and other reported cases showed mass involving the orbit. A. M. McKinney et al. reported multiple cranial nerve involvement in an adult patient.⁶ Bony erosion has been reported in 2 cases so far, one by Lauwers et al¹³ and other by Lindfay Laura Lau et al.³

Surgical excision of the tumor is the treatment of choice for IMT. In orbital tumors, it may not be possible to completely excise the tumor.^{3,12} Combination of surgery and oral prednisolone has been mentioned as treatment options in other studies.^{1,6,13} For recurrent and unresectable tumors radiotherapy is an option of treatment but usually high doses are required which is a limiting factor.¹¹ Complete resection leads to cure and has good prognosis. However, 25-35% of cases do recur. Any local recurrence or aggressive behavior of IMT is attributable to an incomplete resection of the mass.^{14,3,8}

Our patient was managed by extended enucleation. There was no recurrence of tumor at 6 months of follow up.

Conclusion

Orbital IMT is a rare condition of unknown etiology, can manifest as orbital mass in early childhood and adults. IMT is difficult to diagnose, though histopathological examination is confirmatory along with immunohistochemistry, preoperative CT scan and MRI are mandatory for defining the extent of tumor and planning further management. Surgical resection is the treatment of choice. For unresectable and recurrent tumors high dose oral or intravenous steroids can be used. It's important to note that early diagnosis and treatment can save vision and eye.

Conflict of Interest: None.

References

1. H.S. Sa, J. Y. Ji, Y. L. Suh, and Y. D. Kim, "Inflammatory myofibroblastic tumor of the orbit presenting as a

- subconjunctival mass," *Ophthalmic Plast Reconstr Sur* 2005;21(3):211–215.
2. J. G. Batsakis, M. A. Luna, A. K. El-Naggar, and H. Goepfert, "Inflammatory pseudotumor: what is it? How does it behave?" *Ann Otol Rhinol Laryngology* 1995;104(4 I):329–331.
3. Lindfay Laura Lau, Syed Shoeb Ahmad, Anis Farhad and Shuaibah Abdul Ghani Inflammatory Myofibroblastic Tumor—A Case Report *US Ophthalmic Review*, 2016;9(1):34–36.
4. Coindre JM, Histologic classification of soft tissue tumors (WHO.), *Ann de Pathologie*, 1994;14:426–427.
5. A. M. McKinney, J. Short, L. Lucato, K. SantaCruz, Z. McKinney. "Inflammatory myofibroblastic tumor of the orbit with associated enhancement of the meninges and multiple cranial nerves," *Am J Neuroradiol* 2006;27(10): 2217–2220.
6. Sangeeta Shah, Badri Prasad Badhu, Poonam Lavaju, and Anju Pradhan, Ocular Inflammatory Myofibroblastic Tumor in the Left Eye with Phthisis Right Eye: A Rare Occurrence in a Child, *Case Rep Ophthalmol Med* 2015.
7. D. P. O'Malley, C. Poulos, M. Czader, W. G. Sanger, and A. Orazi, "Intraocular inflammatory myofibroblastic tumor with ALK overexpression," *Arch Pathol Lab Med* 2004;128(1):e5–e7.
8. V. Dutta, M. G. Manoj, A. Malik, and P. Kumar, "ALK negative Inflammatory myofibroblastic tumor of the orbit: amasquerading entity," *Indian J Ophthalmol* 2014;62(5):627–629.
9. H. S. Mudhar and M. Nuruddin, "ALK-1 positive orbital inflammatory myofibroblastic tumour (IMT) associated with prominent numbers of IgG4 plasma cells—a case report," *Orbit* 2013;32(5):321–323.
10. S. K. Cramer, A. Skalet, A. Mansoor, D. J. Wilson, and J. D. Ng, "Inflammatory myofibroblastic tumor of the orbit: a case report," *Ophthalmic Plast Reconstr Sur* 2015;31(1):e22–e23.
11. Navinan MR, Liyanage I, Herath S, Inoperable inflammatory myofibroblastic tumour of the para-nasal sinuses and orbit with recurrence responding to methotrexate and prednisolone: a case report, *BMC Res Notes* 2015;8:27.
12. Narla LD, Newman B, Spottswood SS, Inflammatory Pseudotumor, *Radio Graphics*, 2003;23:719–729
13. N. Lauwers, V. De Groot, C. Kenis, S. N. Dhubhghail, J. Claes, and R. J. W. De Keizer, "Atypical sino-orbital inflammatory myofibroblastic tumor with bone and cerebral invasion extending to the orbit," *Eur J Ophthalmol* 2013;24(4):608–610.
14. C. M. Coffin, P. A. Humphrey, and L. P. Dehner, "Extrapulmonary inflammatory myofibroblastic tumor: a clinical and pathological survey," *Semin Diagn Pathol* 1998;15(2):85–101.

How to cite this article: VS Shashidhar, Kumari M, Pediatric orbital inflammatory myofibroblastic tumor: A rare case, *Int J Ocul Oncol Oculoplasty*. 2019;5(1):38-40