

Rhino orbital mucormycosis – A case series

Glennys Carvalho¹, T.C. Vikram Raj Mohanam², Benita Jayachandran^{3,*}, Hannah Ranjee Prasanth⁴

^{1,2}Assistant Professor, ³Junior Resident, ⁴Associate Professor, ¹Dept. of General Medicine, ²Dept. of ENT, ^{3,4}Dept. of Ophthalmology, Pondicherry Institute of Medical Sciences Kalapet, Puducherry, India

***Corresponding Author: Benita Jayachandran**

Email: benitajayachandran@gmail.com

Abstract

Mucormycosis is a fulminating, opportunistic and often a fatal mycotic infection. Its incidence is commonly observed among immune suppressed patients. We are reporting 3 cases of Rhino-orbital mucormycosis with central retinal artery occlusion. All 3 were males in the age range of 50-70 years. All were diabetic with similar clinical presentation; they were treated with I.V Amphotericin B along with control of blood sugars. Although the general outcome was good in all the three patients the visual prognosis remained poor.

Keywords: Central retinal artery occlusion, Diabetes, Immunocompromised Mucormycosis, Rhino-orbital.

Introduction

Mucormycosis is a relatively rare and fatal infective condition. The causative agents belong to the Mucoraceae family, *Absidia*, *Mucor*, and *Rhizopus* which may often be seen in decaying organic matters like food soil and excreta of animals.¹ They have ability to multiply rapidly and release numerous spores that become airborne and which can gain access to humans either by inhalation or ingestion. The spores which enter the person with normal immune system are usually killed by phagocytic action, and rarely immunocompromised people become a victim of this infection.² In India the incidence of mucormycosis was observed to be 0.14 cases per 1000 population.³ In US the incidence was reported to be 20 per 100,000 cases with 0.7% among autopsied patients.⁴ Among US population the cumulative 1 year incidence of Mucormycosis was reported to be 4 per 1000 stem cell and 0.6 per 1000 solid organ transplantation cases respectively.⁵

Rhino-Orbito-cerebral mucormycosis is often observed with immunocompromised state, like blood dyscrasia, malignancy, diabetes mellitus with poor glycemic control, prolonged corticosteroid therapy, post organ transplantation and in severe debilitating conditions like burns and trauma⁶ As rhino- orbito-cerebral mucormycosis occurs rarely, it may pose a challenge for clinicians to diagnose and treat this fatal condition. Early identification of clinical presentation followed by aggressive antifungal therapy, debridement and correction of immunocompromised state is very important to reduce the mortality rate in this condition⁷. Ocular morbidity commonly seen in mucormycosis is central retinal artery occlusion when there is orbital involvement, which may often lead to irreversible blindness. The disease presents often with clinical symptoms resembling facial or orbital cellulitis with rapid progressive clinical course which may end in fatal outcome if not managed properly. Hence the authors decided to write up these cases to resolve the diagnostic dilemma among clinicians treating these patients.

Case Report 1

A 70 year old male with diabetes mellitus for five years and coronary artery disease presented with complaints of fever, right side facial swelling and numbness for 1 month. He had history of sudden painless loss of vision in the right eye. On ocular examination of right eye there was no perception of light, lid edema, proptosis, raised tear film height, grade four relative afferent pupillary defect and restriction of extraocular movements in all quadrants. Fundus showed Mild disc edema, cattle tracking of vessels suggestive of a Central retinal artery occlusion (CRAO), macula showed cherry red spot, background retina was edematous. Based on the presenting features and clinical findings a clinical diagnosis of rhino-orbito-cerebral mucormycosis was made with differential diagnosis of orbital cellulitis, maxillary sinusitis and superior orbital fissure syndrome. Paranasal sinus debridement with orbital decompression was done. Histopathological investigation of debrided tissue sample revealed angioinvasive fungal filaments confirming the diagnosis of Mucormycosis. (Fig. 1 & Fig. 2) Treatment was initiated with IV Liposomal Amphotericin B 0.5mg/kg in view of right maxillary sinus fungal involvement with orbital invasion. In addition, patient's cardiac status was evaluated, echocardiography was done which identified vegetation of 14x6mm attached to basal chordae near the left ventricular apex suggestive of infective fungal endocarditis which could have led to CRAO. The general status of the patient improved although the visual prognosis remained poor.

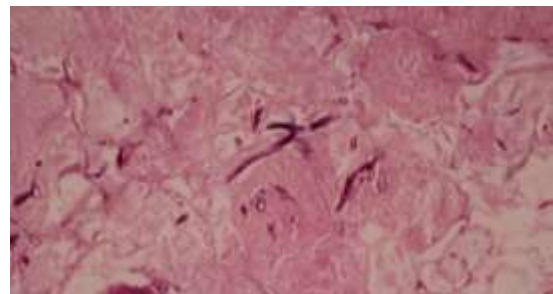


Fig. 1: Histopathological staining showing broad aseptate fungi

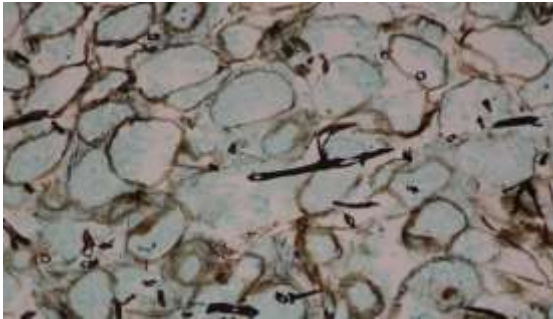


Fig. 2: Gomori silver staining

Case Report 2

A 54 year old male with diabetes mellitus for fifteen years and chronic kidney disease, presented with complaints of right side facial swelling and pain with sudden loss of vision right eye. History of brownish nasal discharge occasionally blood stained for one week. History of pulmonary tuberculosis 10 years back, which was treated. On examination, there was no perception of light in right eye with periorbital edema, proptosis and conjunctival chemosis (Fig. 3) with grade four relative afferent pupillary defect and restriction of extraocular movements in all quadrants. Fundus showed pale disc with well defined margins, cattle tracking of vessels suggestive of a Central retinal artery occlusion (CRAO) (Fig. 4), macula showed cherry red spot, background retina was pale. Oral examination revealed ulcer in the hard palate (Fig. 5). Computed tomography of Paranasal Sinus showed involvement of nasal cavity, maxillary, anterior and posterior ethmoid sinus (Fig. 6). Potassium hydroxide mount done showed Broad Aseptate Hyphae, Zygomycetes with branches confirming the diagnosis of mucormycosis. Medical management involved initiation of Intravenous liposomal Amphotericin B 0.5mg/kg followed by Endoscopic debridement of mucormycosis with palatal fenestration. The general status of the patient improved although the visual prognosis remained poor.

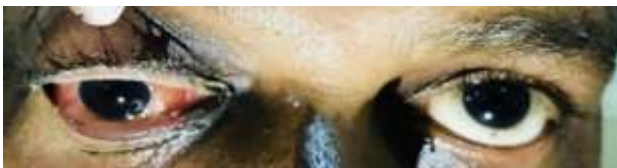

Fig. 3: Right eye with conjunctival chemosis

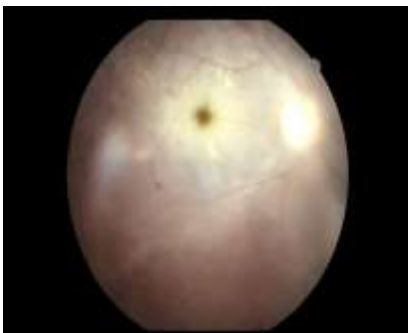

Fig. 4: Central Retinal artery occlusion

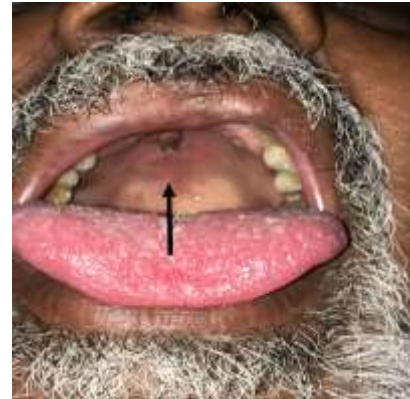

Fig. 5: Hard palate lesion

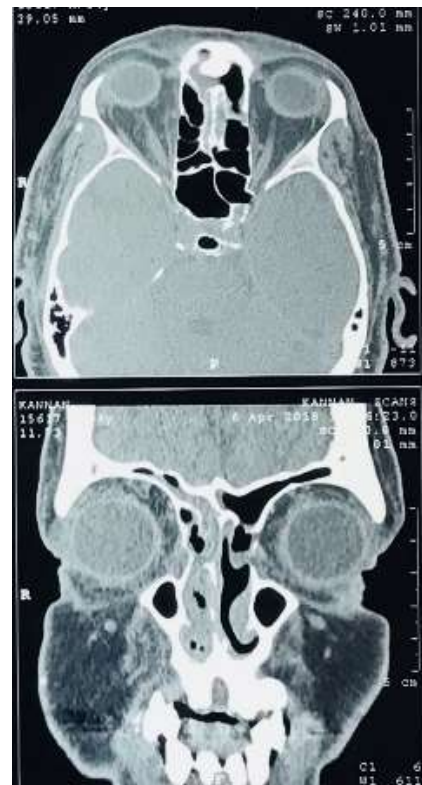

Fig. 6: CT of Paranasal Sinus showed involvement of nasal cavity, maxillary, anterior and posterior ethmoid sinus

Case Report 3

A 71 year old male with history of diabetes mellitus for 10 years and hypertensive for the past 3 years presented with the complaints of intractable pain in and around the orbit with sudden loss of vision in the right eye. Ocular examination of right eye revealed no perception of light, periorbital edema, proptosis, conjunctival chemosis with grade 3 relative afferent pupillary defect and restriction of extraocular movements in all direction of gaze. Fundus examination revealed pale disc with well-defined margins, cattle tracking of vessels suggestive of a Central retinal artery occlusion (CRAO), macula showed cherry red spot, background retina was pale. Oral examination revealed a 2 x 4mm black necrotic ulcer over hard palate. MRI revealed Right sided

pansinusitis with no direct extension to orbit and an 18x7mm defect in the hard palate. Subsequent treatment involved Intravenous liposomal Amphotericin B 0.5mg/kg followed by endoscopic debridement of mucormycosis with palatal fenestration. Tissue culture of debrided sample showed *Rhizopus Arrhizus* growth confirming the diagnosis of mucormycosis. The general status of the patient improved although the visual acuity remained poor.

Discussion

Mucormycosis is an uncommon fungal infection which is invasive in nature with potential fatal outcome.⁸ Because mucormycosis is not a notifiable disease and the incidence is relatively rare, the real data on incidence is difficult to estimate. There are no clear demographic factors which predispose individuals to this condition. Reviews from previous studies show a similar male to female distribution; however a review retrospectively for the past 30 years of all published cases of pulmonary mucormycosis by Lee et al had a male-to-female ratio of 3:1.⁹, which is similar to our series where all three patients were male.

Mucormycosis is commonly reported among patients with poor glycemic control, immunosuppressive conditions like HIV, Malignancy and post organ donation, because of their immunocompromised state.¹⁰ In our series all the three patients were chronic diabetics with poor compliance to treatment which may have predisposed to the development of the disease. The possible mode of transmission of this condition was by inhalation of fungal spores into paranasal sinus and extending into adjacent tissues. Upon germination the fungus invade the adjacent structures like palate, sphenoid sinus, orbit and finally the brain.¹¹ The initial presentation is usually nonspecific in rhino-orbital-cerebral mucormycosis. It usually presents with eye or facial pain, numbness followed by conjunctival chemosis and eventually loss of vision. Elevated white blood count is seen in patient with functional bone marrow. Fever may not be a typical symptom since in half of the patients it is not seen. If untreated, the infection may spread to the orbit, which can result in compromised extraocular muscle function, proptosis and chemosis.¹² Similar results were seen in case series published by Bavikar et al and Kim JG et al where patients presented with facial swelling associated with pain, numbness and loss of vision.^{13,14}

Prompt diagnosis of rhino orbital mucormycosis along with aggressive treatment are vital for good prognosis of the patient¹⁵ Symptoms correlating with mucormycosis in a susceptible individual should call for immediate initiation of treatment while necessary steps are taken towards confirmation of mucormycosis.¹⁶ The presence of branching aseptate hyphae in debrided tissue in histopathological examination may confirm the clinical diagnosis,¹⁷ along with fungal cultures for further confirmation.¹⁸

Imaging studies in the early stages of the disease may not be helpful. In correlation with the clinical finding CT scan may also be used to detect the progression of the disease¹⁹ Soft tissue involvement of fungal infection can be accurately

identified by MRI²⁰ For determining the progression of the disease and surgical intervention both CT and MRI scans should be frequently obtained.²¹ Management of rhino orbito-cerebral mucormycosis involves addressing three key issues: correction of underlying predisposing factors, early initiation of antifungal therapy and appropriate surgical intervention.²²

Although amphotericin B deoxycholate is the drug of choice for mucormycosis, lipid formulations of amphotericin B are considered to be very effective. Recommended initial doses for the lipid formulation of amphotericin are 5-7.5 mg/kg/day, up to 10 mg/kg/day for possible involvement of CNS.²³

Debridement of necrotic tissue along with Antifungal therapy is important for patient survival. In rhino orbital mucormycosis, surgical care includes drainage of the sinuses and even removal of the orbital contents. Repeated surgery may be required, especially for rhino-orbital mucormycosis.²⁴

Conclusion

Rhino orbital mucormycosis is a rare disease with fatal outcome. Patients presenting with symptoms like pain over face with facial swelling, and orbital involvement along with predisposing conditions should routinely be examined for mucormycosis. Early diagnosis, prompt antifungal therapy, surgical debridement and reversal of underlying predisposing conditions is the most important criterion for conservation of orbit and thereby vision of the patient.

Funding: No funding sources.

Conflict of Interest: Nil

References

1. Kwon-Chung KJ. Taxonomy of fungi causing mucormycosis and entomophthoromycosis (zygomycosis) and nomenclature of the disease: molecular mycologic perspectives. *Clin Infect Dis.* 2012;54 Suppl 1:S8-S15.
2. Casqueiro J, Casqueiro J, Alves C. Infections in patients with diabetes mellitus: A review of pathogenesis. *Indian J Endocrinol Metab.* 2012;16(1):S27-36.
3. Chakrabarti A, Singh R. Mycoses. Mucormycosis in India: unique features. *Mycoses.* 2014;57Suppl3:85-90.
4. Kontoyiannis DP, Wessel VC, Bodey GP, Rolston KV. Zygomycosis in the 1990s in a tertiary-care cancer center. *Clin Infect Dis.* 2000 Jun. 30(6):851-856.
5. Kontoyiannis DP, Marr KA, Park BJ. Prospective surveillance for invasive fungal infections in hematopoietic stem cell transplant recipients, 2001-2006: overview of the Transplant-Associated Infection Surveillance Network (TRANSNET) Database. *Clin Infect Dis.* 2010(8):1091-100.
6. Prabhu RM, Patel R. Mucormycosis and entomophthoromycosis: a review of the clinical manifestations, diagnosis and treatment. *Clin Microbiol Infect.* 2004;10 Suppl 1:31-47.
7. Onyango JF, Kayima JK, Owen WO. Rhinocerebral mucormycosis: case report. *East Afr Med J.* 2002;79(7):390-393.
8. Reddy SS, Rakesh N, Chauhan P, Sharma S. Rhinocerebral Mucormycosis Among Diabetic Patients: An Emerging Trend. *Mycopathologia.* 2015;180(5-6):389-396.

9. Francis Y. W. Lee, Sherif B. Mossad, Karim A. Adal. Pulmonary Mucormycosis the last 30 years. *Arch Intern Med.* 1999;159(12):1301-1309. doi:10.1001/archinte.159.12.1301
10. Bodenstern NP, McIntosh WA, Vlantis AC, Urquhart AC. Clinical signs of orbital ischemia in rhino-orbitocerebral mucormycosis. *Laryngoscope.* 1993;103(12):1357-1361.
11. Hosseini SM, Borghei P. Rhinocerebral mucormycosis: pathways of spread. *Eur Arch Otorhinolaryngol.* 2005;262(11):932-928.
12. Spellberg B, Ibrahim AS. *Harrison's Principles of Internal Medicine.* Vol. 2. USA: McGraw-Hill Education; 2015. Mucormycosis; pp. 1350–1351.
13. Kim JG, Park HJ, Park JH. Importance of immediate surgical intervention and antifungal treatment for rhinocerebral mucormycosis: a case report. *J Korean Assoc Oral Maxillofac Surg.* 2013;39(5):246-250.
14. Bavikar P, Mehta V. Rhino-Orbital-Cerebral Mucormycosis: A Fatal Complication of Uncontrolled Diabetes Mellitus. *Cureus.* 2017;9(11):e1841. Published 2017 Nov 13. doi:10.7759/cureus.1841
15. Spellberg B, Edwards J Jr, Ibrahim A. Novel perspectives on mucormycosis: pathophysiology, presentation, and management. *Clin Microbiol Rev.* 2005;18(3):556-569.
16. Chamilos G, Lewis RE, Kontoyiannis DP. Delaying amphotericin B-based frontline therapy significantly increases mortality among patients with hematologic malignancy who have zygomycosis. *Clin Infect Dis.* 2008;47(4):503-509.
17. Lass-Flörl C. Zygomycosis: conventional laboratory diagnosis. *Clin Microbiol Infect.* 2009;15Suppl 5:60-65.
18. Greenberg RN, Scott LJ, Vaughn HH, Ribes JA. Zygomycosis (mucormycosis): emerging clinical importance and new treatments. *Curr Opin Infect Dis.* 2004;17(6):517-525.
19. Talmi YP, Goldschmied-Reouven A, Bakon M, Barshack I, Wolf M, Horowitz Z, Berkowicz M, Keller N, Kronenberg J. Rhino-orbital and rhino-orbito-cerebral mucormycosis. *Otolaryngol Head Neck Surg.* 2002;127(1):22-31.
20. O'Neill BM, Alessi AS, George EB, Piro J. Disseminated rhinocerebral mucormycosis: a case report and review of the literature. *J Oral Maxillofac Surg.* 2006;64(2):326-333.
21. Herrera DA, Dublin AB, Ormsby EL, Aminpour S, Howell LP. Imaging findings of rhinocerebral mucormycosis. *Skull Base.* 2009;19(2):117-125.
22. Kim JG, Park HJ, Park JH, et al. Importance of immediate surgical intervention and antifungal treatment for rhinocerebral mucormycosis: a case report. *J Korean Assoc Oral Maxillofac Surg.* 2013;39(5):246-250.
23. Spellberg B, Walsh TJ, Kontoyiannis DP, Edwards J Jr, Ibrahim AS. Recent advances in the management of mucormycosis: from bench to bedside. *Clin Infect Dis.* 2009;48(12):1743-1751.
24. H. Abid, J. Ammar, F. Yengui. Successful treatment of pulmonary mucormycosis with combined medical and surgical approach, *Respiratory Medicine Extra.* 2007;3(3):120–123.

How to cite this article: Carvalho G, Mohanam TCVR, Jayachandran B, Prasanth HR. Rhino orbital mucormycosis – A case series. *Int J Ocul Oncol Oculoplasty.* 2018;4(4):178-181.