

Endoscopic Dacryocystorhinostomy (DCR) as a primary treatment in acute dacryocystitis in adults

Reshma Pathan^{1,*}, Rizwan Pathan², Ayisha Afreen³

¹Assistant Professor, ²Professor, ³Post Graduate, ^{1,3}Dept. of Ophthalmology, ²Dept. of ENT, Navodaya Medical College, Raichur, Karnataka, India

*Corresponding Author

Email: drreshma_ophtho@yahoo.co.in

Abstract

Aim: To study the result of using endoscopic DCR as a primary treatment for acute dacryocystitis in adults.

Settings and Design: A retrospective case study done to evaluate the results of endoscopic DCR as a primary treatment for acute dacryocystitis in adults.

Materials and Methods: After informed written consent and routine preoperative evaluation patients were posted for primary endoscopic dacryocystorhinostomy. Oral antibiotics were simultaneously started. All patients were taken under intravenous sedation. All cases selected were operated by the same surgeon. The outcome was evaluated in terms of decrease in the swelling, pain and epiphora. The follow up was done 1wk, 4wks, and 6 months after surgery. At every follow up lacrimal syringing was done to establish the patency of the sac. The granulation tissue was cleaned every time endonasally.

Results: All surgeries were uneventful the sac area was much easier to identify due to its swollen nature. Some of the patients underwent a simultaneous septoplasty surgery due to the presence of a deviated nasal septum no DCR stents or tubes were used for the surgery. The first post-operative day the swelling and epiphora were reduced. The pain also reduced in all the patients but in 4 of the patients it reduced gradually over a period of 2 days. The lacrimal syringing showed patent lacrimal passages.

On subsequent follow up i.e. 1 wk and 1 month the osteotomy was cleaned of all the granulation tissue with suction endonasally. The osteotomy was patent at 6 months follow up in 26 patients.

Conclusion: The success rate after the combined treatment of endo-DCR, antibiotics and anti-inflammatory drugs was 92, 85%.

Key Words: DCR, Epiphora, NLD.

Introduction

Acute dacryocystitis is an acute suppurative inflammation of the lacrimal sac, characterized by the presence of a painful swelling in the region of the sac. Acute inflammation of the sac is almost always secondary to lacrimal duct obstruction.^(1,2) Lacrimal duct obstruction can be primary i.e inflammation due to unknown cause and secondary due to infections, inflammatory conditions, neoplasms, trauma and mechanical. It is more common in females. The striking predilection for the females is due to a narrower lumen of the bony naso lacrimal canal which predisposes to obstruction.⁽³⁾ The causative organisms are streptococcus hemolyticus, pneumococcus and staphylococcus. The most common gram-positive organisms isolated include *S. aureus* (worldwide), *S. pneumoniae* (Africa), and *S. epidermidis* (USA). Among the gram-negative isolates, there is a variable predominance like that of *H. influenza* (Middle East), *P. aeruginosa* (North India and USA), *E. coli* (Europe), and *Corynebacterium diphtheriae* (China).⁽⁴⁾

The various stages of acute dacryocystitis include cellulitis, lacrimal abscess and later development of a lacrimal fistula between the sac and the skin.

The most common treatment protocol followed is a course of systemic antibiotics, incision and drainage for the abscess followed by dacryocystorhinostomy which can be external or endoscopic. The complications of incision and drainage include scar in the area, loss of skin, a lacrimal fistula at the site⁽⁶⁾ and pain and

discomfort to the patient during the procedure. It can also disrupt the lacrimal pump mechanism.⁽⁵⁾ The scar and adhesions of the sac after incision and drainage^(7,8) makes external DCR difficult later. Endoscopic DCR can be used as a primary treatment for acute dacryocystitis in the stage of cellulitis with or without lacrimal abscess. There is immediate relief of pain, swelling and epiphora. The painful procedure of incision and drainage can be avoided by the patient. There is no scar reinfection and lesser chances of lacrimal fistula at the site. It also gives more physiological and dependent drainage of the tears.

Materials and Methods

A retrospective case series study of 30 patients with nasolacrimal duct block and presenting with acute dacryocystitis with its complications like preseptal cellulitis, lacrimal empyema, with or without a spontaneous lacrimal fistula was done. Of the 30 patients chosen 27 were females and 3 were males. The females were in the age group of 19-79 yrs average being 45-50 yrs. The youngest male was 16yrs old and the oldest 39 yrs old. 26 out of the 30 patients presented with lacrimal empyema, 2 patients presented with preseptal cellulitis and 2 patients had an associated lacrimal fistula with the empyema. Patients with canalicular block, failed external DCR and failed endoscopic DCR were excluded from the study. After taking written informed consent and routine preoperative evaluation patients were posted for

primary endoscopic DCR. Oral antibiotics were simultaneously started. All patients were taken under intravenous sedation. All cases selected were operated by the same surgeon.

Intranasal infiltration was given in all planes to the anterior end of the middle turbinate. Mucosal flap was elevated maintaining haemostasis. Bony landmarks were identified and bone over the medial wall of the lacrimal sac was removed using these bony landmarks like anterior end of the middle turbinate and posterior margin of frontal process of maxilla. Bone was removed with anterior Kerrisons straight and curved punches to expose the lacrimal sac. Bigger sized punch was used after it was ensured that the lacrimal sac was not included in the punch. Adequate bone was removed till we were able to see the opening of the common canaliculi. If the sac could not be opened completely then removal of the uncinata process was very helpful. Syringing confirmed the patency of the rhinostomy. The nasal cavity was packed with antibiotic gauze or with gel foam. The post-operative medications included oral amoxicillin +clavulanic acid and diclofenac sodium. The patient was discharged the next day and the antibiotics were continued for 1 week along with topical antibiotic drops in the eye. The outcome was evaluated in terms of decrease in the swelling, pain and epiphora. Pain was assessed subjectively using verbal rating scale as no pain, mild pain, moderate pain, severe pain pre and postoperatively. Swelling was assessed by clinical observation. The follow up was done 1 wk, 4wks, and 6 months after surgery. Patients who were lost for follow up at 6 months were excluded from the study. At every follow up, lacrimal syringing was done to establish the patency of the lacrimal osteium. The granulation tissue surrounding the osteium was also cleaned endonasally under local anaesthesia as an office procedure. It was done only in cases where there was granulation tissue at ostium. At 6 months interval the patency of the osteium was reconfirmed with lacrimal syringing.

Results

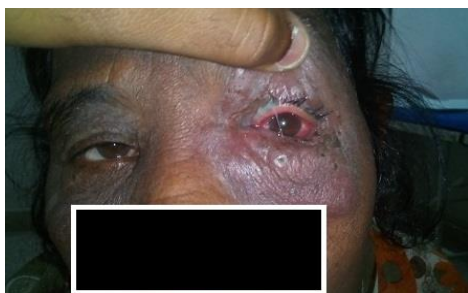

Fig. 1: Left eye acute dacryocystitis with preseptal cellulitis

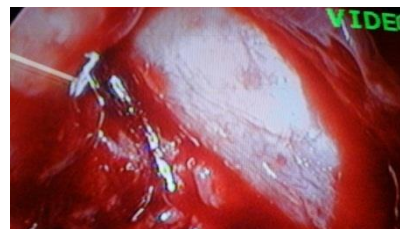


Fig. 2: Sac exposed

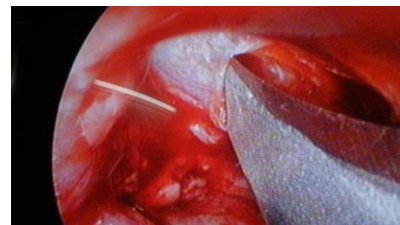


Fig. 3: Incision of sac

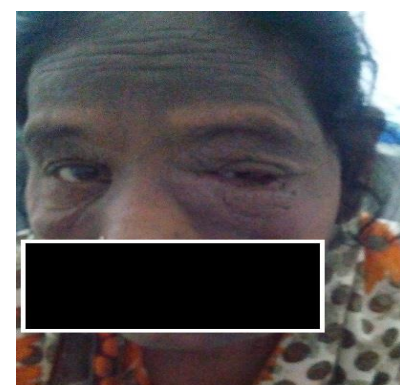

Fig. 4: Post operative day 1

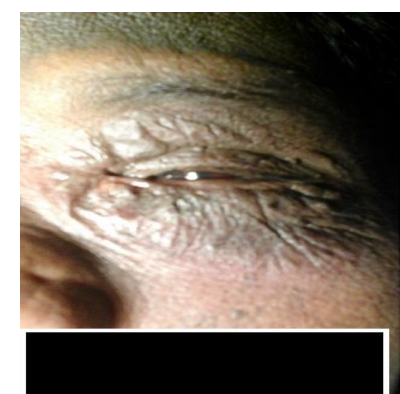


Fig. 5: Post operative 1 wk

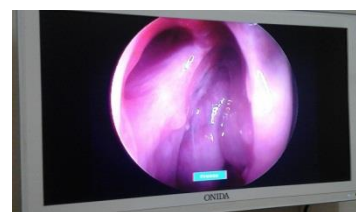

Fig. 6: Patent ostium at end of 6 months with tear flow

Table 1:

Presentation	no of subjects
Lacrimal abscess	26
Preseptal cellulitis	2
Lacrimal abscess with fistula	2
Total	30

Table 2:

6 Month follow up	no of subjects
Patent ostium	26
Restenosis of ostium	2
Lost for follow up	2
Total	30

All surgeries were uneventful, the sac was much easier to identify due to its swollen nature. Some of the patients underwent septoplasty simultaneously for the presence of deviated nasal septum. No DCR stents or tubes were used during surgery.

On the first post-operative day the swelling and epiphora reduced in all the 26 patients. The pain also reduced in all but 4 of the patients in whom it reduced gradually over a period of 2 days. The lacrimal syringing showed patent lacrimal passages in all the 30 patients.

On subsequent follow up i.e 1 wk and 1 month the osteotomy was cleaned of all the granulation tissue with suction endonasally. The osteotomy was patent at 6 months follow up for almost all the patients except for 2 patients who were lost for follow up at 6 months. 2 patients had complain of pooling of tears in the eye but no epiphora. This was due to the restenosis of the osteium but not total obstruction. The patients were taken for a revision endoscopic DCR under local anesthesia. There was a spontaneous closure of the fistula with in a period of 1-2 wks in both the patients who had a lacrimal fistula with abscess. The success rate was 92.85%.

Discussion

Nasolacrimal duct obstruction can be primary or secondary. Primary acquired nasolacrimal duct obstruction (PALDO) is usually idiopathic. It is seen in 80% of the patients. Other causes include trauma, chronic sinusitis, granulomatous diseases like Wegeners granulomatosis, tuberculosis and paranasal sinus tumors.

Dacryocystitis is usually secondary to obstruction of the Nasolacrimal duct. (NLD).⁽¹⁾

Acute Dacryocystitis is due to NLD obstruction along with retention of the tears leading to secondary infection with bacteria. Patients present with pain, redness, epiphora and swelling in the region of medial canthus. Typically the swelling does not extend above the medial canthus. The infection is localized to the preseptal space. Acute dacryocystitis is an ophthalmic emergency that can lead to complications like orbital

cellulitis with lacrimal abscess, facial cellulitis and even cavernous sinus thrombosis and vision loss if left untreated.⁽⁹⁾

The common treatment protocol followed is intravenous antibiotics and incision and drainage for the abscess.⁽¹⁰⁾ This may result in a persistent fistula between the sac and the skin, the incidence being 5.1%.⁽⁶⁾ There is also a risk of recurrent infection before DCR can be performed and the adverse effects of prolonged intake of systemic antibiotics.⁽¹¹⁾

After the control of the active inflammation the patient is taken for surgery which can be external or endoscopic DCR.⁽¹²⁾

Acute dacryocystitis if secondary to infection or inflammation can sometimes subside with only conservative treatment with antibiotics and anti-inflammatory drugs and surgical treatment may not be required. But dacryocystitis secondary to nasolacrimal duct obstruction should always be treated with dacryocystorhinostomy and antibiotics and anti-inflammatory are used to reduce the inflammation and infection.

Surgery during the acute stage is not done as there is risk of exacerbation and spread of infection.⁽¹³⁾ Endoscopic DCR as a primary treatment gives the preference of approaching the lacrimal sac through the non-infected tissue planes and can prevent spread of infection and prevents external scar.⁽¹⁴⁾ It has the benefit of more patient comfort as incision and drainage is avoided, there is immediate relief of pain, swelling and also epiphora. It has an added advantage of minor traumatization with lacrimal pump function being preserved, reduction in time of surgery, and simultaneous treatment of sinonasal diseases. This also provides physiological and dependent drainage of the tears. Endoscopic DCR with lasers are also a proven alternative for conventional treatment of incision and drainage but the results are short lived because of the small size of the ostia created. The ostial fibrosis and stenosis result from the heat generated by bone and mucosal ablation with a holmium: yttrium-aluminium-garnet (holmium: YAG) and potassium titanyl phosphate (KTP) laser.⁽¹⁴⁾

There is less hospital stay as the treatment is immediate. There were 27 females and 3 males indicating a high female preponderance of the disease due to the anatomical predisposition. Among the males the age was less as compared to the females. A similar study for evaluating the efficacy of endoscopic DCR in acute dacryocystitis⁽¹³⁾ have given the success rate to be 93.2% which is similar to our study. But DCR stents were used in this study. Our study did not use anystents but the outcome was similar. Another study of 11 cases⁽¹⁴⁾ of acute dacryocystitis with abscess treated with Endoscopic DCR without DCR stents found a success rate of 81.8%. Stents were not used as they found that maneuvering of the stents difficult because of the edematous nature of the sac. Our study without the use

of any Stents had a success rate of 92.85%. The high success rate would be attributed to the regular removal of the granulation tissue surrounding the osteium. Though previous studies have shown excessive bleeding during the procedure⁽¹³⁾ due to the inflammation our study showed no such complications. Consistent with our study another study⁽¹⁵⁾ on 9 cases of acquired lacrimal abscess found endoscopic DCR to be very effective and cessation of epiphora and spontaneous closure of the fistula was seen in all the cases after the surgery.⁽¹⁷⁾ Our study showed that the results of endoscopic DCR in both chronic (89.8-90%)^(18,19) and acute dacryocystitis to be the same. The results are good in the terms of patient comfort and recovery even in the stage of preseptal cellulitis, lacrimal abscess and lacrimal fistula. The fistulas spontaneously closed in a period of 1-2 wks and no fistulectomy was required. It also showed that no DCR stents were required for the surgery and regular cleaning of the osteium endonasally had a good result.

Lee and Woog⁽²⁰⁾ in their study also advocated Endoscopic DCR as a primary treatment of choice for acute purulent dacryocystitis.

Conclusion

This was a retrospective study of 30 patients with acute dacryocystitis who underwent endoscopic DCR as a primary treatment. The outcome was good with immediate relief of pain, swelling, and epiphora. The treatment results were similar in complications of acute dacryocystitis including lacrimal fistula and no fistulectomy was required. This study showed that endoscopic DCR can be used in complications of acute dacryocystitis like cellulitis and fistulas whereas previous studies were done in lacrimal empyemas.no DCR stents were used in this study.

The success rate of the surgery was 92.85%.

References

1. Pinar-Sueiro S, Sota M, Lerchundi TX, Gibelalde A, Berasategui B, Vilar B, et al. Dacryocystitis: Systematic Approach to Diagnosis and Therapy. *Curr Infect Dis Rep* 2012;14(2):137-146.
2. Lueder GT. The Association of neonatal dacryocystoceles and infantile dacryocystitis with nasolacrimal duct cysts (an American Ophthalmological Society Thesis). *Trans Am Ophthalmol Soc* 2012;110:74-93.
3. Meller J. Diseases of lacrimal apparatus. *Trans Ophthalmol.soc UK* 1929;49:233-311 PubMed.
4. Coden DJ, Hornblase A, Haas BD. Clinical bacteriology of dacryocystitis in adults. *Ophthal Plast Reconstr Surg* 1993;9:125-131.
5. Benger R, Forer M. Endonasal dacryocystorhinostomy Primary and Secondary. *Aust NZJ Ophthalmol* 1993; 21(30):441 PubMed-442).
6. Rhonda VB, Dale RM. Acquired Lacrimal sac fistula after incision and drainage for dacryocystitis: A multicenter study. *Ophthalmic plastic and reconstructive surgery* 2009;455-7.
7. Boulos PR and Rubin PA. A Lacrimal Sac Abscess Incision and Drainage Technique. *Arch Ophthalmol* 2008; 126(9):1297 PubMed-1300.
8. Pollard ZF. Treatment of acute dacryocystitis in neonates. *J Pediatr Ophthalmol Strabismus* 1991; 28(6):341-343.
9. Massaro BM, Gonnoring RS, Harris GJ. Endonasal laser dacryocystorhinostomy. A new approach to nasolacrimal duct obstruction. *Arch ophthal* 1990;108:1172-76 PubMed.
10. Maheshwari R, Maheshwari S, Shah T. Acute dacryocystitis causing orbital cellulitis and abscess orbit 2000;28(2-3)196-99.
11. Woog JJ, Metson R, Puliafito CA, Holmium YAG endonasal laser dacryocystorhinostomy *Am J Ophthalmol* 1993; 116: 1-10.
12. Yakopson, Vladimir S. et al. "Dacryocystorhinostomy: History, Evolution and Future Directions." *Saudi Journal of Ophthalmology* 25.1 (2011):37-49.
13. Wu W, Yan Y, Mac callum JK, Tu Y, Jiang AC, Yang Y, et al. Primary treatment of acute dacryocystitis by endoscopic dacryocystorhinostomy with silicone intubation guided by a soft probe. *Ophthalmology* 2009 Jan;116:116-22.
14. Morgan S, Austin M, whitet H. The treatment of acute dacryocystitis using laser assisted endonasal dacryocystorhinostomy, *BrJ Ophthalmol* 2004;88:139-41 PubMed.
15. Naik SM, Naik SS. Acute dacryocystitis with abscess: Endonasal dacryocystorhinostomy, the primary treatment of choice. *Clin Rhinol An Int J*2012;5(3):107-113.
16. Duggal P, Mahindroo NK, Chauhan A. Primary endoscopic dacryocystorhinostomy as treatment for acute dacryocystitis with abscess formation: *Am J otolaryngol Head Neck Med Surg* 2008;29:177-1779.
17. Subbaiah S. Role of endoscopic dacryocystorhinostomy in treating acquired lacrimal fistulae. *J Laryngol Otol* 2003 oct;117 (10);793-95.
18. Ozgur Yigit, Mehmet S, Umit T. External and endoscopic dacryocystorhinostomy in chronic dacryocystitis: comparison of results. *European Archives of Oto-Rhinolaryngology*. August 2007, vol 264.pg-897-885.
19. Orjeto- Tonuzi, Ali T, Besa V, Manushaqu B, Comparative study of external and endoscopic endonasal dacryocystorhinostomy for the treatment of chronic dacryocystitis. *National Journal of Oto rhino laryngology and head and neck surgery*, Vol 3⁽¹²⁾ No.1, April 2015.
20. Lee TS, Woog JJ, Endonasal dacryocystorhinostomy in the primary treatment of acute dacryocystitis with abscess formation. *Ophthal Plast. Reconstr Surg* 2001;17:180-83 PubMed.