

A retrospective study of pterygium cases treated in a tertiary care hospital at Puducherry

S. Chaitra¹, Sutapa Das^{2*}, M. Subhashini³, M. Kaviraj⁴

¹Post Graduate, ²Associate Professor, ³Professor & Head, ⁴Research Associate, ¹⁻³Dept. of Ophthalmology, ⁴Central Research Laboratory, ²Sri Manakula Vinayagar Medical College and Hospital, Puducherry, India

***Corresponding Author:**

Email: crl@smvmch.ac.in

Abstract

Introduction: Pterygium is a fibrovascular outgrowth of the conjunctiva occur due to the exposure of eyes to UV irradiation, heat and dust causes. There are different surgical procedures available for the management of pterygium with varying recurrence rates. This study briefs the pattern of pterygium among patients attending a rural teaching hospital in south India.

Materials and Methods: 58 pterygium cases of both sexes were included in the study. Age and sex, topography, complications, management and recurrence of pterygium among these cases were retrospectively analyzed.

Results: 70 eyes were clinically diagnosed with pterygium. Majority of the cases were in the active working age group of 20 to 50 with a female predominance of 69%. Pterygium was found to be prevalent in the right eye (43.10%) and in the nasal region (93.10%). Conjunctival autograft (55 cases) and amniotic membrane graft (3 cases) were done to manage all cases and the follow up has shown no recurrence.

Conclusion: Pterygium cases can be efficiently managed with the application of conjunctival autograft and amniotic membrane graft techniques. The major occupation of this area is agriculture where people are more prone to UV exposure in the fields and should take appropriate protective measures to prevent the occurrence and recurrence of pterygium.

Keywords: Amniotic membrane graft, Conjunctival autograft, Pterygium, UV irradiation.

Introduction

Pterygium is a common ophthalmic condition characterized by a wing shaped fibro vascular overgrowth of the conjunctiva. Pterygium growth is more common in the nasal region of the eye and is rarely found on the temporal part.⁽¹⁾ Ultraviolet radiation exposure is believed to be the major risk factor for the development of pterygium. It is reported from all over the world and is more prevalent in tropical countries that are closer to the equator.⁽²⁾ Factors like heat, dust, heredity, Chronic dry eye, limbal stem cell deficiency are also found to be associated with the development of pterygium.^(3,4,5) It is harmless until the growth of pterygium affects the function of the eye. Pterygium, upon encroachment into the cornea, induces astigmatism, blurred vision, due to optical zone involvement and diplopia. People with pterygium mostly come to treatment for cosmetic purpose. But the purpose of approaching an ophthalmologist may also be due to pterygium associated complications like watering of the eye, foreign body sensation, etc. Surgical removal is the gold standard procedure opted to treat pterygium. Radiotherapy with strontium-90/yttrium beta-irradiation is a nonsurgical procedure available to treat early pterygia.⁽⁶⁾ In a study, dipyridamole an antianginal agent, which also has anti-inflammatory and anti-neoplastic properties is used topically to treat a case of pterygium successfully.⁽⁷⁾ In case of progressive pterygium, the best choice of treatment is the surgical excision with appropriate postoperative measures to prevent recurrence. Different surgical procedures have been developed over time to

cure different types of pterygium with a vision to provide complete cure.^(8,9) Surgical excision by bare sclera technique with or without the use of mitomycin C, conjunctival auto grafts and amniotic membrane transplantation, are the surgical procedures presently in practice to treat pterygia. The success rate differs among these techniques and each technique has its own merits and demerits.⁽¹⁰⁾ In bare sclera procedure, the excision of pterygium is followed by simply leaving the scleral bed to re-epithelialize. Bare sclera technique is also followed by the use of mitomycin C; an antimetabolite with antiproliferative effect on cells.⁽¹¹⁾ It is a simple convenient procedure to perform but it has a high recurrence rate upto 80%.⁽¹²⁾ Conjunctival autografts are the widely used procedure for pterygium with recurrence rates as low as 2% to 39%. After excision, the scleral bed is transplanted with a graft obtained from the limbal or bulbar conjunctiva. Limbal conjunctival autograft is found to be more efficient than the conjunctival autograft with a recurrence rate of 0 to 15%.⁽¹³⁾ When the excision is too large, such as double headed pterygium, there exists a problem of insufficiency of the conjunctiva. For such cases, amniotic membrane serves as the best alternative since it has success rates comparable to conjunctival grafts.⁽¹⁴⁾

Materials and Methods

The study was conducted for a period of two years from January 2014 to December 2015 at the ophthalmology department of Sri Manakula Vinayagar Medical College and Hospital, Puducherry. Patient

inclusion criteria: patients who were diagnosed with pterygium and admitted for surgical treatment were included in this study. Exclusion criteria: patients of the following types were excluded from the study, 1) patients who were unwilling to undertake surgery, 2) patients with malignant symptoms, 3) patients who were unable to co-operate with the follow up study of minimum 3 months. Details including name, age, sex, address, personal and family's medical history of the patients were recorded. The range of follow up period after pterygium surgery was 6 to 18 months.

Results

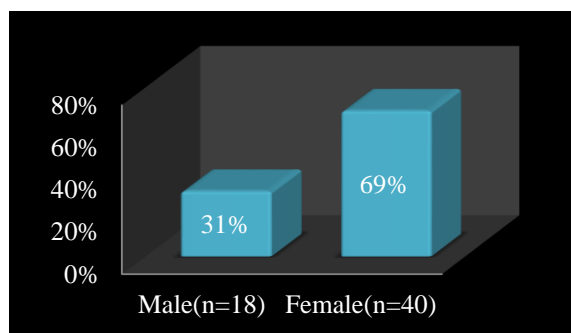
70 eyes of 58 cases were included in the present study. Distribution of age and sex among the patients, eye affected and the site of pterygium, surgical procedure done, are detailed below.

Age and Sex: The mean age of the study subjects is 9.6, with the youngest of 21years and the oldest of 77 years. The age groups 30-39 and 60 to 69 has shown a high prevalence (25.9%) followed by 40-49 (20.6%). A low rate was reported in the less than 30 and above 70 age groups (8.6%) (Table 1). A high female predominance of (69%) over males (31%) is seen. (Fig. 1)

Table 1: Age distribution of pterygium

Age	Total
<30	5(8.60%)
30-39	15(25.90%)
40-49	12(20.60%)
50-59	15(25.90%)
60-69	6(10.30%)
70>	5(8.60%)
Total	58(100%)

The active age group of 30 to 50 is more prone to pterygium



A high female predominance is seen in the study

Fig. 1: Sex distribution of pterygium

Topography of the Involved Eyes: Of the 58 cases, 44.8% had complications of watering and foreign body sensation in the pterygium affected eye. Whereas 31% of patients approached of having defect in vision and 24.1% came to the treatment for cosmetic purpose (Table 2). Right eye (48.2%) was found to be more

prone to pterygium compared to the left one (31%). 20.7% of the patients have had their both eyes affected by pterygium. 3 eyes were diagnosed with double headed pterygium and one case with temporal pterygium, all the rest of the cases were found to be nasal pterigia (93.1%). (Table 3)

Table 2: Pterygium associated complications

Complication	N=58
Defective Vision	18(31%)
Watering/ Foreign Body Sensation	26(44.80%)
Cosmetic	14(24.10%)

Majority of the patients required treatment for pterygium associated complications

Table 3: Topography

Characteristics	N=58
Right eye	28(43.10%)
Left eye	18(31%)
Both eyes	12(20.6)
Occurrence: Nasal/Temporal/Bilateral	
Nasal	54(93.10%)
Temporal	1(1.72%)
Double headed(bilateral)	3(5.17%)

Occurrence of pterygium is most common in the right eye and in the nasal region

Management and Recurrence: The nasal and temporal pterigia were managed by surgical excision followed by conjunctival-limbal autografts. Surgical excision followed by amniotic membrane transplant was done to the three double headed pterigia. There is no postoperative recurrence observed in any of the patients during the follow up period (Table 4).

Table 4: Pterygium management

Surgical Procedure	N=58	Recurrence
Conjunctival Limbal Autograft	55	0
Amniotic Membrane Transplant	3	0

Recurrence is not found in any patients after the surgical procedures

Discussion

The occurrence of pterygium is most common in people aged from 20 to 50 years old.⁽¹⁵⁾ Majority of our study subjects falls in the age of 30 to 50 years. No cases were found below 20 years and the oldest was found to be 77 years. A decline in the number of cases above 50 years of age and the absence of any cases below 21 years old shows that pterygium affects people who are in their active working age. Anguria et al in 2014 reported that younger age has a significant effect

on the recurrence of pterygium in South African population. According to our observation, there is no recurrence at all in any age group.⁽¹⁶⁾

Most of the literatures support the fact that males are more prone to pterygium^(17,18) but we have found a high female predominance in our study. People attending Sri Manakula Vinayagar Medical College and Hospital, Puducherry are from the rural villages of Puducherry and Villupuram where agriculture is the major occupation. Women of these areas spend most of their time in the agriculture fields compared to men,⁽¹⁹⁾ hence exposed to UV irradiation and become more susceptible to develop pterygium.

According to our study, the purpose of approaching the mologist was mainly complications associated with pterygium. The cosmetic purpose of treatment was found to be of low importance among the study subjects. Literature shows that more number of pterygia were treated for cosmetic reason, without any complications.⁽²⁰⁾ The need for treatment varies among populations. It also depends on the fact that the society is urbanized or rural, where the extend of importance to cosmetics differs.

Right eye is found to be more susceptible to pterygium than the left one. The exact mechanism behind this is not clearly understood. Our study also supports the same by showing 43.1% predominance in right eye over left eye (31%). The study also shows a low (20%) incidence of pterygium in both the eyes. Occurrence of pterygium in the nasal region is the most common, in our study only one case (1.72%) was diagnosed with temporal pterygium, 3 subjects (5.17%) with bilateral pterygium and all the rest of the cases (93.10%) were nasal pterigia. These findings are similar in trend with the other studies available in the literature.^(19,17,21) Srinivas et al in 1998 studied 53 pterygium cases in south India who were treated by conjunctival- limbal autograft and found that 3.8 of were recurrent.⁽¹³⁾ A 5% recurrence was reported in a study conducted in 80 north Indian patients in 2013.⁽²²⁾ 0% recurrence observed in all cases treated by conjunctival- limbal autograft of our study is similar to the study conducted by Col in 2006 at Nepal.⁽²³⁾ David et al (2000) reported a 3.8% recurrence in Taiwan population treated with amniotic membrane graft.⁽²⁴⁾ Yadav in 2015 found a 4.1% recurrence in amniotic membrane grafted pediatric population of India.⁽²⁵⁾ 10% of recurrence in patients operated with amniotic membrane graft is also reported in 2015.⁽²⁶⁾ The three bilateral cases operated by amniotic membrane graft in our study shows 0% recurrence. A 100% success rate in the present study shows the efficiency of conjunctival- limbal autograft and amniotic membrane graft in the management of pterygium.

Conclusion

People working outdoors may take preventive measures like using sunglasses, caps to avoid UV

irradiation and dust. A reference standard to grade pterygium and the appropriate procedure required for each type of pterygium is to be developed for better management. The 100% success rate, without any recurrence proves that conjunctival- limbal autograft for the management of nasal and temporal pterigia and amniotic membrane transplant for double headed pterigia, as best choices to be opted.

References

1. Kamel S. Pterygium its nature and a new line of treatment. *Br J mol.* 1946 Sep;30(9):549–63.
2. Moran DJ, Hollows FC. Pterygium and ultraviolet radiation: a positive correlation. *Br J mol.* 1984 May;68(5):343–6.
3. Goldberg L, David R. Pterygium and its relationship to the dry eye in the Bantu. *Brit. Y.* (1976) 60, 720.
4. Li M, Zhang M, Lin Y, Xiao Q, Zhu X, Song S, et al. Tear function and goblet cell density after pterygium excision. *Eye (Lond).* 2007 Feb;21(2):224–8.
5. Hecht F, Shoptaugh MG. Winglets of the eye: dominant transmission of early adult pterygium of the conjunctiva. *J Med Genet.* 1990 Jun 1;27(6):392–4.
6. Pajic B, Greiner RH. Long term results of non-surgical, exclusive strontium-90 beta-irradiation of pterygia. *Radiother Oncol.* 2005 Jan;74(1):25–9.
7. Carlock BH, Bienstock CA, Rogosnitzky M. Pterygium: Nonsurgical Treatment Using Topical Dipyrindamole - A Case Report. *Case Reports in mology.* 2014 Mar 25;5(1):98–103.
8. Ang LPK, Chua JLL, Tan DTH. Current concepts and techniques in pterygium treatment. *Curr Opin mol.* 2007 Jul;18(4):308–13.
9. Kaufman SC, Jacobs DS, Lee WB, Deng SX, Rosenblatt MI, Shtein RM. Options and adjuvants in surgery for pterygium: a report by the American Academy of mology. *mology.* 2013 Jan;120(1):201–8.
10. Mohammed I. Treatment of pterygium. *Annals of African Medicine.* 2011;10(3):197.
11. Mahar PS, Nwokora GE. Role of mitomycin C in pterygium surgery. *Br J mol.* 1993 Jul;77(7):433–5.
12. Youngson RM. Recurrence of pterygium after excision. *Br J mol.* 1972 Feb;56(2):120–5.
13. Rao SK, Lekha T, Mukesh BN, Sitalakshmi G, Padmanabhan P. Conjunctival-Limbal autografts for primary and recurrent Pterygia: Technique and results. *Indian Journal of mology.* 1998 Oct 1;46(4):203.
14. Ti S-E, Tseng SCG. Management of primary and recurrent pterygium using amniotic membrane transplantation. *Curr Opin mol.* 2002 Aug;13(4):204–12.
15. Shrestha S, Shrestha SM. Comparative study of prevalence of pterygium at high altitude and Kathmandu Valley. *J Nepal Health Res Counc.* 2014 Oct;12(28):187–90.
16. Anguria P, Ntuli S, Carmichael T. Young patient's age determines pterygium recurrence after surgery. *Afr Health Sci.* 2014 Mar;14(1):72–6.
17. Rohatgi S. Pterygium: an epidemiological study in India. *International J. of Healthcare & Biomedical Research,* Volume: 1, Issue: 4, July 2013, Pages 297-301.
18. Nangia V, Jonas JB, Nair D, Saini N, Nangia P, Panda-Jonas S. Prevalence and Associated Factors for Pterygium in Rural Agrarian Central India. *The Central India Eye and Medical Study.* PLOS ONE. 2013 Dec 4;8(12):e82439.
19. Krishnam K. Prevalence and Pattern of Pterygium. *The Internet Journal of mology and Visual Science.* 2013

- Oct 11;10(1).
20. Lawrence W Hirst. Treatment of pterygium Australian and New Zealand Journal of Ophtalmology.1998;26: 269-270.
 21. Fotouhi A, Hashemi H, Khabazkhoob M, Mohammad K. Prevalence and risk factors of pterygium and pinguecula: the Tehran Eye Study. Eye (Lond). 2009 May;23(5):1125–9.
 22. Pandey AN, Marken N, Marken R, Pandey BC. A Clinical Study of Pterygium and Results of Treatment by Excision and Limbal Autograft or Augmented with Post-Op Mitomycin C. Open Journal of ology. 2013;03(04):97–102.
 23. Col KN Jha. Conjunctival-Limbal Autograft for Primary and Recurrent Pterygium. MJAFI, 2008;64(4).
 24. Ma Hui-Kang David. Comparison of Amniotic membrane grafts alone or combined with intraoperative Mitomycin C to prevent recurrence after excision of recurrent pterygia. Cornea 2005;24:141-50.
 25. Yadav A, Bhattad K, Sen P, Jain E, Sen A, Jain B. Outcome of different techniques of pterygium excision with conjunctival autografting in pediatric population: Our experience in central India. Indian Journal of ology. 2015;63(6):491.
 26. M.V.D.L. Sathyanarayana, M.V. Sailaja. Efficacy of Fresh Amniotic Membrane Graft Vs conjunctival Auto graft with Stem Cell Transplantation in Management of Pterygium IOSR Journal of Dental and Medical Sciences (IOSR-JDMS) 2015 Feb;14(2):96-102.