

Outcomes of canalicular tear repair using a Mini-Monoka silicone stent: Results from a tertiary care centre

Nayana Potdar^{1*}, Shruti Shirwadkar², Amol Ganvir³, Swaranjali Gore⁴, Chhaya Shinde⁵

¹Professor/Additional, ²Lecturer, ^{3,4}Resident, ⁵Professor and Head, Dept. of Ophthalmology, Lokmanya Tilak Municipal Medical College & General Hospital, Sion, Mumbai, India

***Corresponding Author:**

Email: nayanapotdar@yahoo.com

Abstract

Aim: To evaluate the outcomes of canalicular tear repair performed by using self-retaining monocanicular Mini-Monoka silicone stent.

Setting: Retrospective study at a tertiary referral centre.

Materials and Methods: 20 patients who underwent surgical repair for canalicular laceration using Mini Monoka silicone stent from April 16 to July 17 were reviewed. Apart from demographic data, the mode of injury, injury location, complications and outcomes were analysed. Patients were followed up.

Results: The mean age of the patients was 28 years (range 2–66 years), 17 patients (85%) had involvement of the lower canaliculus. The most common cause of canalicular tear was road traffic accident in 10 patients (50%) followed by projectile-object 5(25%), blouse hook injury during breast feeding-3 (15%), Metal rod and dog bite – accounting for 1 (5%) cases each. All cases were operated within 24 hours of injury with insertion of Mini Monoka stent. Stent removal was done at 6 weeks. At last follow up, 19/20 cases had functional and anatomical success in terms of absence of epiphora & patent syringing. One case reported with stent extrusion and subsequently developed canalicular obstruction and epiphora. No other long term stent related complications were noted.

Conclusions: Early (within 24 hours) repair of canalicular tears with a self-retaining Mini Monoka silicone stent gives good success rates with anatomical and functional success.

Keywords: Canalicular laceration, Eyelid trauma, Epiphora, Mini Monoka Stent.

Introduction

Canalicular lacerations are the most commonly reported form of trauma to the lacrimal system. Repairing the cut canaliculus includes identification of both the cut ends of the canaliculi; aided by high magnification and good hemostasis. But there is lack of consensus on the need to repair a cut canaliculus with some practitioners preferring to repair only if the lower canaliculus was involved and some authors proposing that not repairing a monocanicular lesion is a valid approach that results in little or no morbidity.

The lacrimal excretory pathway begins at a 0.3mm opening on the medial portion of each eyelid termed the punctum. The lower eyelid punctum being located slightly lateral to the upper eyelid punctum.⁽¹⁾ The punctal opening widens into the ampulla, which is 2 mm in height and directed perpendicular to the eyelid margin, before making a sharp turn into the canaliculi.⁽²⁾ The canaliculi measure 8–10 mm in length and 0.5–1.0 mm in diameter, and course parallel to the eyelid margins. The canaliculi are lined with stratified squamous epithelium and surrounded by orbicularis muscle. In more than 90% of individuals, the superior and inferior canaliculi merge to form a common canaliculus before entry into the nasolacrimal sac.⁽³⁾ A common canaliculus was present in 94% of lacrimal drainage systems. The upper and lower canaliculi joined at the wall of the lacrimal sac without a common canaliculus in an additional 4%, with only 2% of

systems having completely separate drainage of the upper and lower canaliculi into the lacrimal sac.⁽⁴⁾

Given that canalicular lacerations, if left untreated can lead to epiphora, which can be an socially embarrassing. With this background, this study was conceived with an aim to evaluate the outcomes of canalicular laceration repair performed using monocanicular Mini-Monoka silicone stent.

Materials and Methods

This retrospective study was done at a tertiary eye care centre of patients who underwent Mini Monoka stent placement for the management of monocanicular lacerations between April 2016 and July 2017. All Data were collected from hospital records including patients' demographic details, mode of trauma, associated ocular injuries, time interval between injury and surgical intervention, postoperative complications, and follow up findings. All repairs were done within 24 hours of injury under local anaesthesia with 2% Lignocaine with adrenaline under aseptic conditions except four children in whom general anaesthesia was required. Preoperative injectable antibiotics were administered in all cases and in unimmunized cases, anti-tetanus vaccine was also given. The one dog bite case received all necessary Anti Rabies Vaccine/ immunization and local immunoglobulin prophylaxis. Preoperative CT scan orbit done to check fractures of orbital walls in cases of road traffic accidents that necessitated imaging. The cornea, conjunctiva, sclera, lens status were assessed on

slit lamp and dilated fundus examination was performed on all patients the same medial and lateral end of lacerated canaliculus were identified under high magnification of operating microscope. In cases in which we could not identify the distal end of the lacrimal canaliculus, trypan blue dye was introduced into the uncut opposite canaliculus & observed the flow of the dye from the cut end of the laceration and located the nasal end of the canaliculus. For canaliculus laceration repair, we dilated the involved punctum using a Nettleship punctum dilator. The distal end of the self retaining Mini Monoka stent cut to create a beveled edge for its smooth insertion through the punctum and it was pulled out through the lateral cut end of the canaliculus so that collar is seated flush with punctal ampulla and gets anchored in the punctum. Using an atraumatic forceps, the stent was then passed through the severed opening of the canaliculus on nasal side and guided in till the tip of the stent reached the lacrimal sac. After securing the stent through lacerated ends we used purse string suture through surrounding subcutaneous tissue around the stent with 6-0 vicryl to secure it. Later skin and subcutaneous tissue closed in layers by interrupted suture by 6-0 silk & 6-0 vicryl. All patients were prescribed topical steroid and antibiotic eye drops four times a day, patients were instructed not to rub their eyes in order to prevent early tube extrusion. Skin sutures were removed at the first postoperative week. The wound was assessed on post-operative day 1 and then followed up after one week, six weeks, and three months. The stent was removed at 6 weeks and patency of the canaliculus was assessed by syringing.

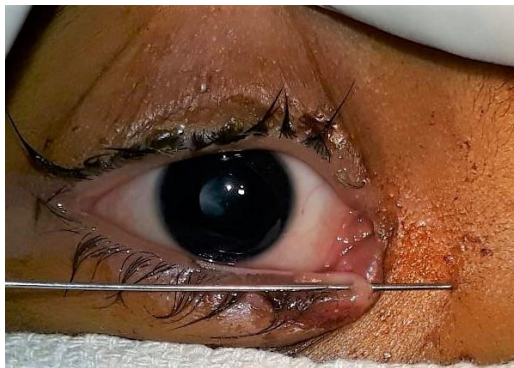


Fig.1: Bowman's probe showing cut in lower canaliculus

Results

The mean age of the patients was 28 years (range 2–66 years). Patients had directly come in Casualty. Location wise, the lower canaliculus was involved in 17/20 (85%) An equal sex-distribution was noted with 10 (50%) of the cases being male & 10 Female. The most common cause was road traffic accident in 10 patients (50%) followed by canalicular tear with blouse hook during breast feeding in 3 patients (15%) and

projectile associated injury with stone & knife 5 patients (25%) Metal rod and dog bites: 1 (5%) each. All cases were operated within 24 hours of injury. Subconjunctival haemorrhage was the most common associated ocular co-morbidity, and was seen in 7/20 (35%) of the cases. Orbital fracture was the second most frequent ocular co-morbidity and fracture Orbital floor was noted in 2/20 (10%). All stents were removed at six weeks. One patient returned at 3 weeks with a prolapsed stent – irrigation suggested a canalicular obstruction – he denied any intervention. Irrigation was performed in 16/16 adults and fluorescein dye disappearance test was performed in the four children. The lacrimal system showed no obstruction in 19/20 (95%) cases with 1 case presenting with tube extrusion (5%) being the sole failure. No punctal granuloma, slit-like punctum or complications were seen in the entire cohort.

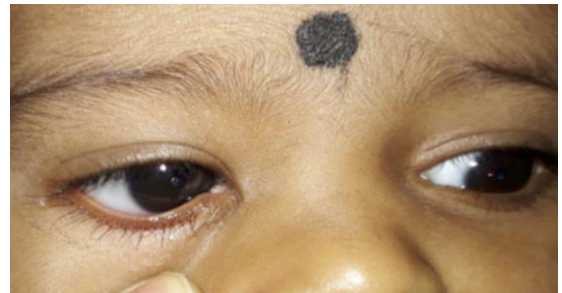

Fig. 2: Shows 2yr old child who came with feeding associated canalicular trauma due to blouse hook injury underwent a canalicular repair with a Mini Monoka silicone stent. The stent is seen in situ in lower punctum

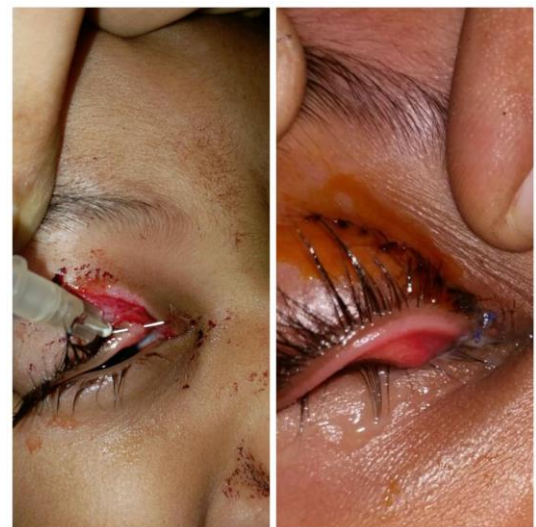

Fig. 2: A shows upper canalicular laceration by knife, Fig. 2 B shows upper canaliculus repair with Mini Monoka stent insertion

Discussion

Canalicular lacerations are breaks in the normal tear duct system. Lesions of the lacrimal drainage system occur in up to 16% of all eyelid injuries.⁽⁵⁾ Canalicular lacerations are the most common injury of lacrimal drainage system because of their exposed position in the upper and lower lid. The canalicular lacerations are commonly associated with trauma to the eyelids. Since the dense fibrous tissue of the tarsus is much stronger than the medial canalicular portion of the eyelid, any tractional force along the eyelid margin can result in medial eyelid avulsion with canalicular involvement. Canalicular tears can involve the upper canaliculus alone, lower alone or both simultaneously. It can be lateral tear (within 8mm from the punctum) or medial (more than 8mm) from the punctum.⁽⁵⁾

The current concept is to repair any canalicular lesions since we cannot predict which patients will become symptomatic; so early repair with modern surgical techniques has good success according to reports in literature. Also, there have been various materials used to stent canalicular tears such as Teflon, suture, silver wire and silicone, which continues to be the most popular material used.⁽⁶⁾ Silicone is the preferred material of choice owing to its low bio-reactivity, inert nature, ease of handling.

Canalicular trauma is known to be more common in children as compared to adults (5 from other) However, in our study 4/20 (20%) of the cases were in the paediatric age group. In the three children who had canalicular lacerations, the mode of trauma was injury from the mother's blouse hook which engaged in the lower lid and upon being pulled caused a laceration through the canaliculus. One child was attacked by dog leading to upper canalicular tear.

Singh and colleagues studied the factors predicting outcomes of canalicular lacerations.⁽⁷⁾ They reported that Overall patency by irrigation was seen in 74.4% at a median follow-up of 19.89 weeks (range 21-910). Anatomical outcome was different among the stents and best after Mini-Monoka monocanalicular stent (17/19; 89.5%) followed by bicanalicular annular stents (n = 6; 60%) and 20G Silicone rod (8/14, 57%). The factors predictive of poor outcome were related to the mode of injury (road traffic accidents; Hazard ratio (HR)19.57; p = 0.048) and the type of stent (20G silicone rod (HR 35.7; C.I 3.04 - 419.14; p = 0.004)) by multivariate analysis. Skill of the surgeon was critical as the outcome for fellows-in-training showed a trend towards failure (HR 6.66, p = 0.07). Complications included stent extrusion (n = 28.2%), punctal granuloma (n = 5.1%) and stent exposure (n = 2.5%). The mode of injury-road traffic accidents and type of stent - 20 G silicone rod were risk factors predictive of poorer outcome after canalicular laceration repair. Individual skill of operating surgeon may be a critical factor suggesting a review of training protocols.

Comparatively our study had a surprisingly lower number of complications.

With regards to the time gap between injury and repair, Chu et al studied if delayed repair of traumatic canalicular laceration affects the final outcome.⁽⁸⁾ In their paper, there were 23 failed cases among 301 patients (7.6%) who had a repair within 48 hours and 3 failed cases among 33 patients (9.1%) who had a repair after 48 hours (P = .732). The mean operation time was 62 minutes in the early group and 66.3 minutes in the delayed group, which showed no significant difference (P = .371). The major cause of delayed surgery was traumatic brain injury, followed by facial or orbital fracture, long bone fracture, and chest injury. They concluded that delayed canalicular repair in unstable patients did not lead to poor results. An elective scheduling surgery, instead of an urgent repair, is feasible for an experienced surgeon.⁽⁸⁾

With regards to the use of a mono-canalicular stent, Naik et al. conducted a similar retrospective study where they found that Mini-Monoka stent extrusions occur within one month. With an 11.1% extrusion rate, Mini-Monoka stents achieved good anatomical (90%) and functional (100%) success in the management of canalicular injury.⁽⁹⁾ We believe that our data further strengthens the idea that a monocanalicular stent gives acceptable outcomes in canalicular lacerations.

In our study, all cases were repaired within 24 hours of trauma and while we do not have a control arm in which delayed repair was done, it may be possible to assume that the absence of scarring, edema and tissue swelling aided in proper visualisation of distal cut end and repair. Our study did have some inherent limitations. This study was done at a tertiary referral centre, thereby a referral bias does seep in with simpler, less complicated cases being not referred as they would have been treated at the centre where they initially sought help. Other features such as visual outcome were not included in the study, neither did we assess the association of the presence of other ocular injuries in affecting the outcomes of canalicular tear repair.

In conclusion, in our cohort, no complications related to the Mini-Monoka tube, such as punctal plug migration, eye irritation, inflammation, granuloma formation, or erosion, occurred during the follow-up period. Generally speaking, the ultimate goal of reconstructing a lacerated canaliculus is approximation of the cut end of the canaliculus and placing a stent through the anastomosed canaliculus in order to facilitate mucosal healing and to prevent a canalicular obstruction. Our report shows that microscopic Canalicular reconstruction with a Mini-Monoka tube is a safe, reliable, and simple technique, avoids injury to the uninvolved canaliculus, and does not require any nasal manipulation or endoscopic assistance with low complications. .

References

1. Whitnall SE. The Anatomy of the Human Orbit and Accessory Organs of Vision. New York: Oxford University Press;1932:1-252.
2. Jones LT. An anatomical approach to problems of the eyelids and lacrimal apparatus. Arch Ophthalmology 1961;66:111-124.
3. Lemke BN. Lacrimal anatomy. Adv Ophthalmology Plastic Reconstructive Surgery 1984;3:11-23.
4. Yazici B, Yazici Z. Frequency of the common canaliculus: a radiological study. Arch Ophthalmology 2000;118(10):1381-1385.
5. Dronvsek B, Beltram M. Trauma of lacrimal drainage system Retrospective study of 32 patients. Croat Med J.2004;45:292- 294.
6. Reifler DM. Management of canalicular laceration. Surv Ophthalmol. 1991;36(2):113-32.
7. Singh S, Ganguly A, Hardas A, Tripathy D, Rath S. Canalicular lacerations: Factors predicting outcome at a tertiary eye care centre. Orbit. 2017;36(1):13-18.
8. Chu YC, Wu SY, Tsai YJ, Liao YL, Chu HY. Early Versus Late Canalicular Laceration Repair Outcomes. Am J Ophthalmol. 2017;182:155-159.
9. Naik MN, Kelapure A, Rath S, Honavar SG. Management of canalicular lacerations: epidemiological aspects and experience with Mini-Monoka monocanicular stent. Am J Ophthalmol. 2008;145(2):375-380.