

Ocular manifestations associated with microcephaly

Archana Kamalapurker^{1,*}, Devika P², Sudhir Hegde³

^{1,2}Assistant Professor, ³HOD & Professor, Dept. of Ophthalmology, ¹ESIC Medical College Gulbarga, Karnataka, ^{2,3}A. J. Institute of Medical Sciences, Mangalore, Karnataka, India

***Corresponding Author:**

Email: archana.kamlapurkar@gmail.com

Abstract

Aim: Microcephaly is a neurodevelopmental disorder and eye being a derivative of neural tube is most commonly affected. This study describes ocular manifestations associated with microcephaly.

Materials and Methods: A prospective study was conducted which included 16 children referred from department of paediatrics with diagnosis of microcephaly. Detailed history followed by Ocular examination with assessment of visual acuity, strabismus evaluation, slit lamp examination and fundoscopy were performed. Visual acuity assessment was done by Snellen's and Jaeger's chart for distance and near vision respectively in verbal children and fixation behaviour assessment for preverbal children.

Result: Mean age of children was 5yrs. All children showed delayed development of visual system. The ocular manifestations observed were myopia in 7, delayed fixation in 4, strabismus in 5, and horizontal nystagmus in 2 children.

Conclusion: Myopia (7/18 as per our results) and strabismus (5/18 as per our result) being the ocular manifestations most often associated with microcephaly require early detection, prompt management and follow-up so as to reduce visual morbidity that results from these conditions

Keywords: Microcephaly, Nystagmus, Strabismus.

Introduction

Microcephaly is a neurodevelopment disorder and eye being a part of neural tube derivative is commonly affected in microcephalics.^(5,6) Variety of ocular abnormalities are associated with microcephaly, the most common being squint and optic atrophy.^(1,3)

Microcephaly is defined by cranial parameters at least two standard deviation below the mean for the age and sex, considered in a given population.⁽³⁾ Microcephaly is usually autosomal recessive but can also be autosomal dominant.

In various studies conducted it was stated that microcephaly has a significant association with ocular manifestations, especially the true microcephaly also known as "Giacomini's disease" is a rare form of hereditary microcephaly, its frequency being estimated to be one in 50,000 births.⁽⁵⁾ Its most commonly associated with squint and optic atrophy.^(1,3)

Microcephaly is usually autosomal recessive but when associated with chorioretinal dysplasia transmission is through autosomal dominant mode.^(4,7)

Most children with cerebral palsy as a result of ischemic insult to brain are microcephalic with developmental delay, and two important ocular findings in such patients are strabismus and myopia.⁽¹⁾

There are various syndromes where in microcephaly can be associated with ocular abnormalities such as Down's syndrome, Patau syndrome, Edward syndrome, Wolf-Hirschhorn syndrome,⁽⁹⁾ Williams syndrome, DeGeorge syndrome, sickle cell syndrome,⁽²⁾ holoprosencephaly, Rett syndrome, Cohen syndrome, Cockayne syndrome, Aicardi-Goutieres syndrome⁽⁸⁾ etc.

The eye and the brain both being derivatives of neural tube most of the microcephalics present with

ocular abnormalities. Thus this is a prospective study that describes the ocular manifestations associated with microcephaly.

Aims

- i. To detect ocular abnormalities in children with microcephaly.
- ii. For early diagnosis, treatment and follow up of the ocular abnormalities seen in children with microcephaly.

Materials and Methods

A prospective study was conducted at our institution which included 18 children referred from department of paediatrics with diagnosis of microcephaly. Duration of the study was six months. Detailed history followed by ocular examination with assessment of visual acuity, complete strabismus evaluation, slit lamp examination and fundoscopy were performed. Visual acuity assessment was done by Snellen's and Jaeger's chart for distance and near vision respectively in verbal children and fixation behaviour assessment for preverbal children.

The ethical committee clearance was granted after which children were subjected to the study. Total of 18 children were subjected to the study. Patient profile, head circumference, birth history, developmental delay, and ocular findings were documented and the data were analyzed. Visual assessment and visual developmental delay associated with microcephaly were noted and treated accordingly.

Table 1: Causative factors in microcephaly

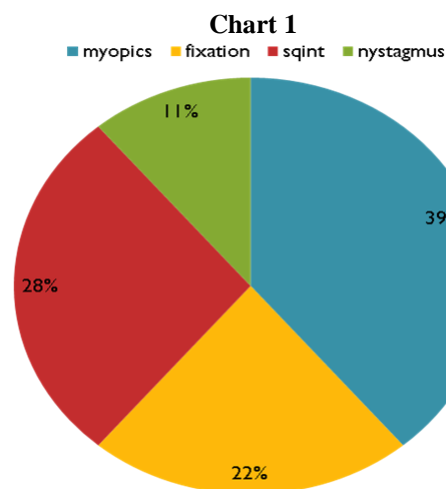
Cause of microcephaly	Number of subjects
Cerebral palsy	9
Severe malnutrition	4
Downs syndrome	2
congenital	3
Total	18

Statistical Analysis

Total of 18 children (n=18) with microcephaly were examined as per above method and sorted into percentages with pie chart.

Table 2: Observation and analysis

Ocular Findings	No. of subjects N=18
Myopia	7
Delayed fixation	4
Strabismus	5
Nystagmus	2

**Result and Discussion**

Mean age of children in the study was 5yrs. All children (n=18) showed delayed development of visual system. In addition all subjects were detected to have one or more of the ocular manifestations with myopia being observed in 7, delayed fixation in 4, strabismus in 5, and horizontal nystagmus in 2 children.

Microcephaly and Refractive Error: The most common type of refractive error noticed in children with microcephaly is myopia followed by hypermetropia and astigmatism.⁽¹⁾

In a study by Sasmal NK, Maiti P out of 140 microcephalics 12.9% children were myopic while 8.6% showed hypermetropia and astigmatism in 3.6% cases.⁽¹⁾

In our study it was found that there were 7 myopics out of 18 microcephaly children accounting for about 39%. There were no hypermetropic or astigmatism noticed in these subjects.

Table 3:

	Sasmal NK, Maiti p	Present study
No. of subjects	140	18
% of myopia	12.9%	39%
% of hypermetropia	8.6%	nil
% of astigmatism	3.6%	nil

Microcephaly and delayed fixation: As microcephaly can result in developmental delay or microcephaly by itself may be the result of developmental delay, the eyes are most frequently affected in their growth and development.⁽¹⁾

Many syndromes as described above show microphthalmos or microcornea in such children due to abnormality in neural crest cells which is a source of both brain and the eyes.⁽³⁾

Hence delayed fixation is often noticed in the children with microcephaly accounting for about 22% in our study.

Table 4:

	Sasmal NK, Maiti P	Present study
No. of subjects	140	18
% of delayed fixation	20.7%	22%

Microcephaly and strabismus: Strabismus is one of the most common association found in several studies. Squint- an aetiological marker in microcephaly.⁽¹³⁾

In the study, ocular manifestations in children with cerebral palsy, the percentage of squint was noted to be 36.4% out of 140 microcephalics.⁽¹⁾

In a study by Rustom and Fiskien, out of 50 microcephalics 35 of them showed to have convergent squint.⁽¹³⁾

Where as in our study we found 28% of the microcephalics with squint. All of them were observed to have convergent squint.

Table 5:

	Sasmal NK, Maiti P	Rustom and Fiskien	Present study
No. of subjects	140	50	18
% of strabismus	36.4%	70%	28%

Microcephaly and nystagmus: Nystagmus doesn't manifest as a single entity but is usually associated with syndromes.

In our study the two children with nystagmus and microcephaly were diagnosed to have downs syndrome.

Table 6:

	Ljubic A, Trajkovski V	Sasmal NK, Maiti P	Present study
No. of subjects	134	140	18
% of nystagmus	9.7%	9.3%	11%

Conclusion

Myopia (7/18 as per our results) and strabismus (5/18 as per our result) being the ocular manifestations most often associated with microcephaly require early detection, prompt management and follow-up so as to reduce visual morbidity that results from these conditions.

This study can be a significant contribution in the field of pediatric ophthalmology with regular screening and treatment of visual impairment in microcephalics due to any cause. This in turn would reduce the burden of ocular morbidity in such children.

References

1. Sasmal NK, Maiti P, Mandal R, Das D, Sarkar S, Sarkar P, Biswas MC, Dey AK, Chatterjee S. Ocular manifestations in children with cerebral palsy. *J Indian Med Assoc* 2011;109:318-323.
2. McLaughlin BN, Martin RW, Morrison JC. Clinical management of sickle cell hemoglobinopathies during pregnancy. *Clin Perinatol* 1985;12:585-97.
3. Alzial C, Dufier JL, Aicardi J, de Grouchy J, Saraux H. Ocular abnormalities of true microcephaly. *Ophthalmologica* 1980;180:333-9.
4. Robitaille JM, Gillett RM, LeBlanc MA, Gaston D, Nightingale M, Mackley MP, Parkash S, Hathaway J, Thomas A, Ells A, Traboulsi EI, Héon E, Roy M, Shalev S, Fernandez CV, MacGillivray C, Wallace K, Fahiminiya S, Majewski J, McMaster CR, Bedard K. Phenotypic overlap between familial exudative vitreoretinopathy and microcephaly, lymphedema, and chorioretinal dysplasia caused by KIF11 mutations. *JAMA Ophthalmol* 2014;132:1393-9.
5. Shi Y, Li J, Chen C, Gong M, Chen Y, Liu Y, Chen J, Li T, Song W, Mol Brain. 5-methyltetrahydrofolate rescues alcohol-induced neural crest cell migration abnormalities. *JAMA Ophthalmol* 2014;7:67.
6. Seltzer LE, Paciorowski AR. Genetic disorders associated with postnatal microcephaly. *Am J Med Genet C Semin Med Genet* 2014;166:140-55.
7. Jones GE, Ostergaard P, Moore AT, Connell FC, Williams D, Quarrell O, Brady AF, Spier I, Hazan F, Moldovan O, Wieczorek D, Mikat B, Petit F, Coubes C, Saul RA, Brice G, Gordon K, Jeffery S, Mortimer PS, Vasudevan PC, Mansour S. Microcephaly with or without chorioretinopathy, lymphoedema, or mental retardation (MCLMR): review of phenotype associated with KIF11 mutations. *Eur J Hum Genet* 2014;22:881-7.
8. Merchant R, Verma M, Shah A, Kulkarni S, Jalan A. Aicardi-Goutières Syndrome. *Indian J Pediatr* 2016;83:882-3.
9. Battaglia A, Carey JC, South ST, Wright TJ. In: Pagon RA, Adam MP, Ardinger HH, Bird TD, Dolan CR, Fong CT, Smith RJH, Stephens K. *Wolf-Hirschhorn Syndrome*. University of Washington, Seattle;1993-2014.
10. Siddiqui AM, Everman DB, Rogers RC, DuPont BR, Smith BT, Seaver LH, Morales A, Varn M, Cohen B, Traboulsi EI. Microcephaly and congenital grouped pigmentation of the retinal pigment epithelium associated with submicroscopic deletions of 13q33.3-q34 and 11p15.4. *Ophthalmic Genet* 2009;30:136-41.
11. Taban M, Memoracion-Peralta DS, Wang H, Al-Gazali LI, Traboulsi EI. Cohen syndrome: report of nine cases and review of the literature, with emphasis on ophthalmic features. *J AAPOS*. 2007 Oct;11(5):431-7.
12. Brackeen A, Babb-Tarbox M, Smith J. Pigmentary changes and atopic dermatitis in a patient with Seckel syndrome. *Pediatr Dermatol*. 2007 Jan-Feb;24(1):53-6.
13. Rustom and Finken. Squint - an aetiological marker in microcephaly. *Journal of the Royal Society of Medicine*. 1994;87:761.