

A comparative study to evaluate the clinical outcome between dry amniotic membrane and conjunctival limbal autograft after excision of primary pterygium

Meghana P. Patil^{1,*}, Ravindra B.², Manjunath BH³, Anitha S. Maiya⁴

¹Assistant Professor, ²Professor & HOD, ³Professor, ⁴Associate Professor, Dept. of Ophthalmology, JJM Medical College, Davangere, Karnataka

***Corresponding Author:**

Email: drmeghana14@gmail.com

Abstract

Objectives: To assess the efficacy and safety of dry amniotic membrane graft after pterygium excision in primary pterygium and compare the clinical outcome with conjunctival limbal autograft.

Materials and Methods: This randomized clinical trial was done on 60 patients with primary pterygium attending ophthalmology outpatient department. Patients who fulfil inclusion and exclusion criteria were randomized to receive conjunctival limbal autograft (CLAG) or dry amniotic membrane graft (dry AMG) after surgical excision. Intraoperatively, the clinical outcomes assessed were button hole and graft tear. Post operatively, we evaluated graft loss, graft edema and recurrence after surgery on postoperative day one, 1 week, 1 month and 3rd month. The standard procedure was followed for pterygium excision by single surgeon and one of the above graft was used to cover the bare sclera and sutured.

Results: The patient's age ranged from 32-71 years (mean age, 47.7 years). 39 males and 21 females were included in the study. Majority of pterygium patients were elderly males (51.28%) and outdoor working population (71.6%). The intra operative complications noted were button hole (3.3%) and graft tear (2.85%). Immediate post operative complications were graft oedema (26.6%) and graft loss (10.0%). Recurrence rate was (6.66%) in CLAG and (16.66%) in dry AMG group.

Conclusion: Dry amniotic membrane graft is beneficial, safe and has few complications. It can be used as an adjunctive therapy in patients with conjunctival scarring, double headed pterygium and glaucoma patients requiring filtering surgery.

Keywords: Conjunctival limbal autograft, Dry amniotic membrane graft, Pterygium

Introduction

Pterygium is a wing shaped fibrovascular conjunctival fold that proliferates over the ocular surface. It is a common conjunctival degeneration characterized by elastotic degeneration of collagen and fibrovascular proliferation.⁽¹⁾ The prevalence of pterygium globally is 0.3% to 29% and highest in countries closer to equator.^(2,3) The risk factors include excessive exposure to sunlight, males, elderly and outdoor activity.⁽⁴⁾ The invasion of pterygium on the corneal surface can lead to significant visual morbidity due to irritation of the ocular surface, irregular astigmatism, obstruction of the visual axis and loss of corneal transparency.⁽⁵⁾ The most common indications for surgery are persistent discomfort, chronic irritation, recurrent inflammation, visual distortion, irregular astigmatism, restricted ocular motility and cosmesis.⁽⁶⁾ As of now, a wide spectrum of treatment strategies have been described for pterygium treatment which includes pterygium excision with bare sclera, conjunctival autograft, amniotic membrane transplantation, adjunctive use of mitomycin-C and beta radiation.⁽⁷⁻¹¹⁾

Recurrence is the most common complication after pterygium excision and various techniques have been implemented to reduce its recurrence. Several studies have observed decreased recurrence rates with conjunctival limbal autograft as limbal stem cells promote healing.⁽¹²⁻¹⁴⁾ The use of amniotic membrane as an adjunctive therapy in pterygium surgery is beneficial in certain conditions, such as pre-existing conjunctival

scarring, double headed pterygia and glaucoma patients requiring future filtering surgery.⁽¹⁵⁾ Many studies using cryopreserved amniotic membrane after pterygium excision have reported higher recurrence rate due to loss of beneficial factors and decreased efficacy of the graft during the process of cryopreservation.⁽¹⁶⁻¹⁸⁾

Dry amniotic membrane is made by freeze-drying the fresh AM without damaging the physical and biochemical properties and retaining the beneficial factors, such as epidermal growth factor and TGF- β 1.⁽¹⁹⁾ Allen et al compared dried and cryopreserved AM for ocular surface dressing and found that dried AM was superior to cryopreserved AM due to the effect of the preservation process on the tissue.⁽¹⁹⁾ Thus, the aim of the study is to assess the efficacy and safety of dry amniotic membrane after excision of primary pterygium and compare the clinical outcome with conjunctival limbal autograft.

Objectives

1. To study the efficacy and safety of dry amniotic membrane graft after excision of primary pterygium.
2. To compare the clinical outcome between dry amniotic membrane graft and conjunctival limbal autograft.

Materials and Methods

This randomized control trial included 60 patients attending ophthalmology outpatient department over a

period of one year. Institutional review board approval was obtained and the study followed the tenets of the declaration of Helsinki. The inclusion and exclusion criteria are as follows

Inclusion criteria

- Patients of either sex above 18 years.
- Patients with primary pterygium

Exclusion criteria

- Patients with recurrent pterygium.
- Double headed pterygium
- Patient with known immunodeficiency status.
- Patients with acute ocular infections
- Patients with associated systemic conditions like DM, HTN, TB.

A written informed consent was obtained from patients who fulfil the inclusion and exclusion criteria. Comprehensive ophthalmic examination including uncorrected and best corrected visual acuity measurement, refraction, tonometry, slit lamp biomicroscopy and dilated fundus examination was done. Patients were randomized to receive either CLAG or dry AMG (Amniocare, Biocover laboratories) after excision of primary pterygium. The clinical outcomes were evaluated intraoperatively for button hole, graft tear, and graft loss (graded as yes/no) and postoperatively for graft oedema, graft loss, graft infection, graft rejection and recurrence (graded as yes/no) on day 1, at 1 week, 1 month and 3rd month.

Surgical technique: All surgeries were performed by the same surgeon and peribulbar anaesthesia was used for all patients (3ml lignocaine 2% +2ml bupivacaine 0.5%). The eye undergoing surgery was prepared and draped in the usual sterile fashion. After insertion of a lid speculum, intrapterygial injection of 0.1ml lignocaine was injected to delineate the fibrovascular tissue. The head of the pterygium was peeled off using blunt dissection and body excised. The subconjunctival fibrovascular tissue over the sclera within exposed area

was removed by scissors and the cornea was polished. The bare sclera was measured with calliper and a same sized conjunctival graft was harvested from the superotemporal bulbar conjunctiva after subconjunctival injection of anaesthetic. Meticulous dissection was done around the limbus to harvest conjunctiva without damaging the limbus and the graft was placed on the bare sclera with orientation of limbal side in the graft towards limbus and sutured with absorbable 8-0 vicryl suture. For dry AMG transplantation, the pre processed freeze dried amniotic membrane (Amniocare, biocover labs) was cut to the size 0.5mm greater than the bare sclera. The graft was placed over bare sclera and hydrated with saline, edges were buried below the conjunctiva and sutured with 8-0 vicryl. The eye was bandaged for next 24 hours and postoperatively analgesic tablets were prescribed. On postoperative day 1, all patients received an identical regimen of antibiotic steroid combination (moxifloxacin 0.5% + dexamethasone phosphate 0.1% ophthalmic solution) four times per day, and tapered off within 1 month.

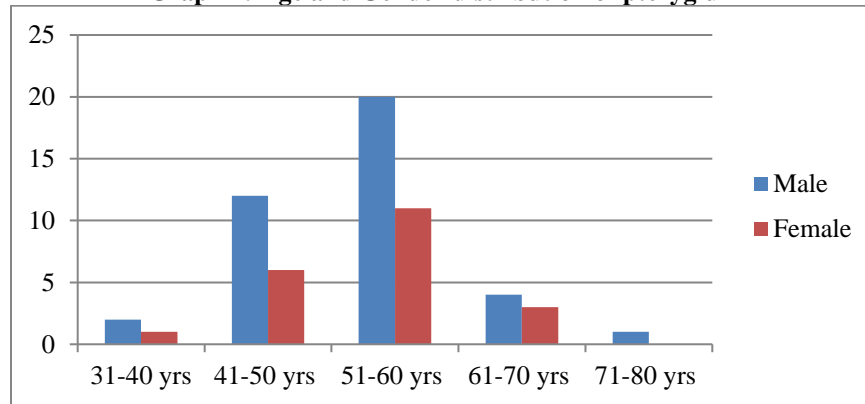
Statistical analysis: All demographic data including age, sex, occupation and the clinical outcomes were compared between conjunctival autografts and amniotic membrane grafts using the chi square (χ^2) test, SPSS software version 14.

Results

A total of 60 eyes of 60 patients were included in the study. Patient's age ranged from 32-71 years with mean patient age of 47.7 years. The male to female ratio was 1.85: 1 with 39 (65%) males and 21(35%) females. Majority of the patients with pterygium were in 5th decade (51.6%) with 33.3% males and 18.3% females and minimal in 3rd decade(5%) and 7th decade(1.66%). In our study, pterygium was more prevalent in elderly males(Table 1)

Table 1: Age and Gender distribution of pterygium

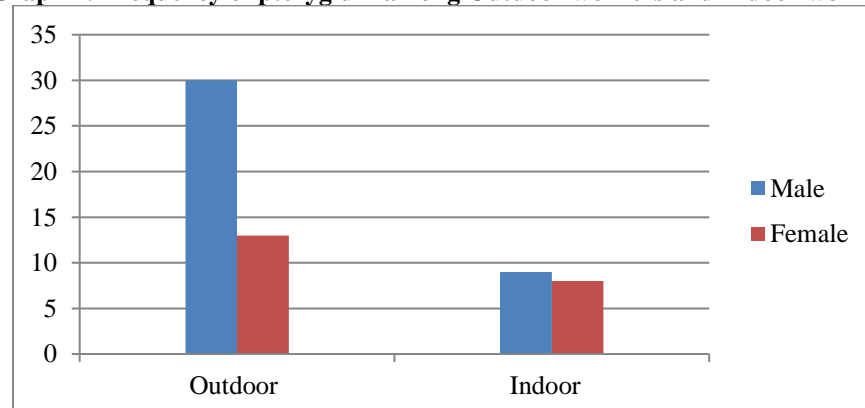
	Age in years				
	31-40	41-50	51-60	61-70	71-80
Male	2 (3.33%)	12 (20%)	20 (33.3%)	4 (6.66%)	1 (1.66%)
Female	1 (10%)	6 (10%)	11(18.33%)	3(5%)	0
Total (%)	3(5%)	18(30%)	31(51.6%)	7 (11.6%)	1 (1.66%)

Graph 1: Age and Gender distribution of pterygium

In our study, majority of patients with outdoor activity 43(71.6%) had pterygium with 30 males (50%) and 13 females (21.66%) and minimal in indoor workers (15%) males and (13.3%) females.(Table 2)

Table 2: Frequency of pterygium among Indoor worker and Outdoor worker

	Outdoor	Indoor
Males	30 (50%)	9 (15%)
Females	13(21.66%)	8(13.3%)
Total	43	17

Graph 2: Frequency of pterygium among Outdoor workers and Indoor workers

Complications

Intraoperatively: CLAG group had 3cases (10%) of button hole in the graft of which one case had less than 1mm button hole which was observed and 2 cases had more than 2mm button hole which was sutured with 8-0 vicryl suture. In dry AMG group 2 cases(6.66%) of graft tear was noted which were less than 1mm and managed conservatively. There was no statistical significance between the groups (p 0.667).

Immediate post-operative period

Graft edema: 9 cases in CLAG group and 5 cases in dry AMG had graft edema on postoperative day one which was managed by increasing the frequency of antibiotic steroid drops. At 1week follow up, 4 cases in CLAG group and 2 cases in dry AMG had graft edema which were observed 2 weekly for 1month. At follow

up visit 1month and 3rd month, none of the cases in either group had graft edema. (Table 3)

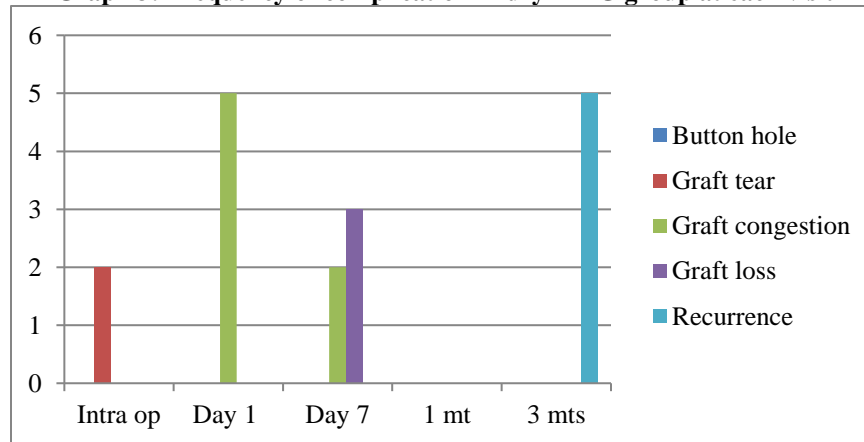
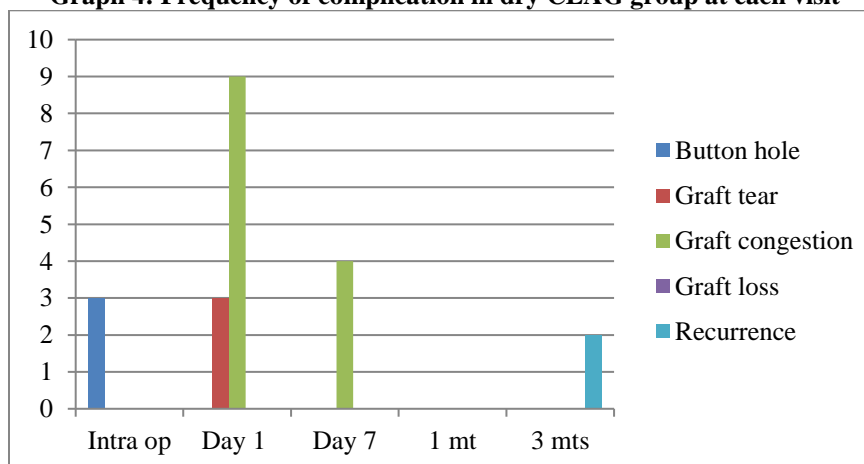
Graft loss: 3 cases in dry AMG group had graft loss at 1 week follow up and none in CLAG group. No further intervention was done in these patients and the course was observed with weekly follow up visits upto 1month. At 3rd month follow up, 2 cases of graft loss had recurrence which could be due to exposed sclera. (Table 3)

Late post-operative period

Recurrence: In our study, we had 5 cases of recurrence in dry AMG group and 2 cases in CLAG group at 3rd month follow up. The recurrence rate was 16.66% in amniotic group and 6.66% in conjunctival autograft group. We found no significant differences in the recurrence rate between the two groups (p=0.282). (Table 3)

Table 3: Frequency of postoperative complication in both the groups at each visit

Complications Visits	Graft edema		Graft loss		Recurrence	
	Dry AMG	CLAG	Dry AMG	CLAG	Dry AMG	CLAG
Day 1	5	9				
1 week	2	4	3	0		
1 month						
3 rd month					5	3
P value	0.436		0.33		0.282	

Graph 3: Frequency of complication in dry AMG group at each visit**Graph 4: Frequency of complication in dry CLAG group at each visit**

Discussion

An ideal pterygium surgery has no complication. It is safe and effective with less recurrence rate and perfect cosmesis. Although several surgical techniques have been described over the decades to reduce the complications after pterygium excision, conjunctival limbal autograft or AMT have gained worldwide acceptance for treatment of pterygium with good postoperative outcome.⁽²⁰⁾ AM has several biological properties, including antiangiogenic, anti-inflammatory and anti-scarification property which makes it an ideal graft for ocular surface reconstruction.^(10,21-22)

In our study we observed elderly males (33.3%) with outdoor activity(50%) had higher occurrence of

pterygium as UV exposure is one of the risk factor for pterygium. Similar findings were observed by Srinivas Marmula et al (59% above 55 years and 46.4% males had more prevalence of pterygium).⁽²³⁾ Zhong H et al, Asokan R et al and Salagar K M et al had 74.8%,16.2% and 80% pterygium occurrence in outdoor working population respectively.⁽²⁴⁻²⁶⁾

Immediate post operative complications noted in our study were graft oedema (p 0.335) and graft loss(p 0.61) which resolved without any adverse effects except two out of 3 cases of graft loss had recurrence which was managed conservatively. Mutla et al. observed that graft edema was the most frequent complication in limbal conjunctival autograft transplantation. Similar

observation was made in our study (30%) graft edema in CLAG group.⁽²⁷⁾ A study by Sheppard JD et al had similar findings and observed that minor complications had no significance in graft survival.⁽²⁸⁾

Recurrence is a most common complication after pterygium excision and represents significant surgical problem.⁽²⁹⁾ Several techniques have been tried to reduce the fibro vascular activity aiming to reduce rate of recurrence such as B-irradiation, conjunctival and limbal auto-grafting, anti-mitotic drugs and amniotic membrane transplantation.⁽³⁰⁾ In our study we noted 5(16.66%) recurrences in dAMG group and 3 (10%) in CLAG group(p 0.282). The recurrence rate was not statistically significant between the groups in our study. Zheng K, et al and Ozer A et al observed less recurrence with conjunctival autograft technique.^(31,32) Tananuvat N, et al and Salman AG et al observed less recurrence rate with conjunctiva autograft as compared to cryopreserved amniotic membrane graft.^(33,34)

Noureddin GS et al observed that dry AM has better biochemical integrity, retains beneficial factors, associated with less complications, can be quarantined for infectious diseases, less expensive and easily accessible when compared to cryopreserved AM. In our study similar observations were made and both the treatments were well tolerated with no adverse effects.

Limitations in our study include small sample size and short term follow up to monitor the recurrence rate. We observed 3 cases of graft loss during 1 week follow up visit which was conservatively managed and lead to recurrence in 2 cases. This can be prevented by surgical intervention in graft loss cases with either CLAG or AMT.

Conclusion

Dry amniotic membrane grafting is a novel technique after pterygium excision which has many benefits with less complications, inexpensive and readily available. This makes its more useful in developing countries and military environments. Dry AM may not be the ideal choice routinely in every case of pterygium. However, in cases of conjunctival scarring, double headed pterygia and glaucoma patients requiring future filtering surgery can be considered as ideal choice and surgeons should keep this technique in their armamentarium of treatment options.

Disclosure

The authors report no conflicts of interest in this work.

References

1. Wright KW. Conjunctival degenerations. In: Cooke DB, Klass FM, editors. Text Book of Ophthalmology. Vol. 1. USA: RR Donnelley; 1997. pp. 681–2.
2. Oldenburg JB, Garbus J, McDonnell JM, McDonnell PJ. Conjunctival pterygia. Mechanism of corneal topographic changes. *Cornea*. 1990;9:200–4.

3. Razeghinejad MR, Banifatemi M. Subconjunctival bevacizumab for primary pterygium excision; a randomized clinical trial. *J Ophthalmic Vis Res*. 2014;9:22–30.
4. Sun LP, Lv W, Liang YB, Friedman DS, Yang XH et al. (2013). The prevalence of and risk factors associated with pterygium in a rural adult Chinese population: the Handan Eye Study. *Ophthalmic Epidemiol* 20:148-154.
5. Rong SS, Peng Y, Liang YB, Cao D, Jhanji V. Does cigarette smoking alter the risk of pterygium? A systematic review and meta-analysis. *Invest Ophthalmol Vis Sci*. 2014;55(10):6235–6243.
6. Detorakis ET, Spandidos DA. Pathogenetic mechanisms and treatment options for ophthalmic pterygium: Trends and perspectives (Review). *Int J Mol Med* 2009;23:439-47.
7. Ang LP, Chua JL, Tan DT. Current concepts and techniques in pterygium treatment. *Curr Opin Ophthalmol* 2007;18:308-313.
8. Hirst LW. The treatment of pterygium. *Surv Ophthalmol* 2003;48:145-180.
9. Tekin NF, Kaynak S, Saatci AO, Cingil G. Preserved human amniotic membrane transplantation in the treatment of primary pterygium. *Ophthalmic Surg Lasers* 2001;32:464-469.
10. Ti SE, Tseng SC. Management of primary and recurrent pterygium using amniotic membrane transplantation. *Curr Opin Ophthalmol* 2002;13:204-212.
11. Lewallen S. A randomized trial of conjunctival autografting for pterygium in the tropics. *Ophthalmology* 1989;96:1612-1614.
12. Masters JS, Harris DJ Jr. Low Recurrence Rate of Pterygium after Excision with Conjunctival Limbal Autograft: A Retrospective Study With Long-Term Follow-Up. *Cornea*. 2015 Dec;34(12):1569-72.
13. Fernandes M, Sangwan VS, Bansal AK, Gangopadhyay N, Sridhar MS, Garg P, Aasuri MK, Nutheti R, Rao GN. Outcome of pterygium surgery: analysis over 14 years. *Eye (Lond)*. 2005 Nov;19(11):1182-90.
14. Mahdy MAES, Bhatia J. Treatment of primary pterygium: Role of limbal stem cells and conjunctival autograft transplantation. *Oman Journal of Ophthalmology*. 2009;2(1):23-26.
15. Solomon A, Pires RT, Tseng SC. Amniotic membrane transplantation after extensive removal of primary and recurrent pterygia. *Ophthalmology*. 2001;108(3):449–460.
16. Rahman I, Said DG, Maharajan VS, Dua HS. Amniotic membrane in ophthalmology: indications and limitations. *Eye (Lond)*. 2009;23(10):1954–1961.
17. Ma DH, See L, Liao S, Tsai RJ. Amniotic membrane graft for primary pterygium: comparison with conjunctival autograft and topical mitomycin C treatment. *The British Journal of Ophthalmology*. 2000;84(9):973-978.
18. Luanratanakorn P, Ratanapakorn T, Suwan-apichon O, Chuck RS. Randomised controlled study of conjunctival autograft versus amniotic membrane graft in pterygium excision. *The British Journal of Ophthalmology*. 2006;90(12):1476-1480.
19. Allen CL, Clare G, Stewart EA, et al. Augmented dried versus cryopreserved amniotic membrane as an ocular surface dressing. *PLoS One*. 2013;8(10):e78441.
20. de Roth A. Plastic repair of conjunctival defects with fetal membranes. *Arch Ophthalmol Chic* 1940;23:522-525.

21. Kim JC, Tseng SC. Transplantation of preserved human amniotic membrane for surface reconstruction in severely damaged rabbit corneas. *Cornea* 1995;14:473-484.
22. Dua HS, Gomes JA, King AJ, Maharajan VS. The amniotic membrane in ophthalmology. *Surv Ophthalmol* 2004;49:51-77.
23. Marmamula S, Khanna RC, Rao GN. Population-Based Assessment of Prevalence and Risk Factors for Pterygium in the South Indian State of Andhra Pradesh: The Andhra Pradesh Eye Disease Study. *Investigative ophthalmology & visual science*. 2013;54(8):5359-66.
24. Zhong H, Cha X, Wei T, Lin X, Li X, Li J, et al. Prevalence of and risk factors for pterygium in rural adult Chinese populations of the Bai nationality in Dali: the Yunnan Minority Eye Study. *Investigative ophthalmology & visual science*. 2012;53(10):6617.
25. Asokan R, Venkatasubbu RS, Velumuri L, Lingam V, George R. Prevalence and associated factors for pterygium and pinguecula in a South Indian population. *Ophthalmic and Physiological Optics*. 2012;32(1):39-44.
26. Salagar KM, Biradar KG. Conjunctival Autograft in Primary and Recurrent Pterygium: A Study. *Journal of clinical and diagnostic research: JCDR*. 2013;7(12):2825.
27. Mutlu FM, Sobaci G, Tatar T, Yildirim E. A comparative study of recurrent pterygium surgery: limbal conjunctival autograft transplantation versus mitomycin C with conjunctival flap. *Ophthalmology*. 1999 Apr;106(4):817-21.
28. Sheppard JD, Mansur A, Comstock TL, Hovanesian JA. An update on the surgical management of pterygium and the role of loteprednol etabonate ointment. *Clinical Ophthalmology (Auckland, NZ)*. 2014;8:1105-1118.
29. Yaisawang S, Piyapattanakorn P. Role of post-operative topical corticosteroids in recurrence rate after pterygium excision with conjunctival autograft. *J Med Assoc Thai*. 2003 Jun;86 Suppl 2:S215-23.
30. Kawasaki S, Uno T, Shimamura I, Ohashi. Outcome of surgery for recurrent pterygium using intra-operative application of mitomycin C and amniotic membrane transplantation. *Japan Journal of Ophthalmology* 2015. 47(6),625-626.
31. Zheng K, Cai J, Jhanji V, Chen H. Comparison of pterygium recurrence rates after limbal conjunctival autograft transplantation and other techniques: meta-analysis. *Cornea*. 2012;31(12):1422-7.
32. Ozer A, Yildirim N, Erol N, Yurdakul S. Long-term results of bare sclera, limbal-conjunctival autograft and amniotic membrane graft techniques in primary pterygium excisions. *Ophthalmologica*. 2009;223(4):269-73.
33. Tananuvat N, Martin T. The results of amniotic membrane transplantation for primary pterygium compared with conjunctival autograft. *Cornea*. 2004;23(5):458-63.
34. Salman AG, Mansour DE. The recurrence of pterygium after different modalities of surgical treatment. *Saudi Journal of Ophthalmology*. 2011;25(4):411-415.
35. Nouredin GS, Yeung SN. The use of dry amniotic membrane in pterygium surgery. *Clin Ophthalmol*. 2016 Apr 18;10:705-12.