

Conjunctival reactive lymphoid hyperplasia – a rare case report

Pratheebadevi Nivean^{1,*}, M. Nivean², Ayshwaria B³

¹Medical Director, Dept. of Oculoplasty Surgeon, ²Academic Director, Dept. of Retinal Surgeon, ³PG Student, MN Eye Hospital Pvt. Ltd., Chennai

***Corresponding Author:**
Email: nivean69@gmail.com

Abstract

Ocular adnexal lymphoproliferative lesions can appear in the conjunctiva, orbit, eyelid and lacrimal gland. They can be both primary or secondary and range from benign lymphoid hyperplasia (BLH) to malignant lymphoma. Nodular lesions in conjunctiva are not very common in childhood. So a high index of suspicion of these lesions should be in mind while evaluating them. We present this case to create awareness about this lesion and the need for follow up in such children.

Keywords: Benign lymphoid hyperplasia, Conjunctival nodular lesions, Lymphoma

Introduction

Benign lymphoid hyperplasia of the conjunctiva is rare in children. Its presentation, clinical course and appropriate management are not well established. We describe a child who presented with nasal conjunctival mass that on pathological examination was suggestive of benign lymphoid hyperplasia. Although the natural history of extranodal lymphoid hyperplasia in children is poorly documented, most cases of nodal lymphoid hyperplasia in children are at very low risk of malignant transformation. Careful observation for local and systemic disease is indicated for ocular adnexal lymphoid hyperplasia in children. We present this case for the rare nature of the disease and to create awareness among ophthalmologist that these lesions would need a biopsy and proper follow up to rule out systemic involvement.

Case Report

A 17 year old male came to our clinic with complaints of growth in the nasal aspect of the left eye since 3 months. He had no pain, defective vision or double vision. No previous history of similar swellings in the eye. There was no history of intraocular surgeries in the past. On examination his best corrected visual acuity was 6/6, n6 in both eyes respectively. Anterior and fundus examination of the right eye was normal. Anterior segment examination of left eye showed a fleshy growth in the nasal conjunctiva lateral to the caruncle measuring about 5mm x 3 mm (Fig. 1). There was no proptosis of the left eye. Retrobulbar resistance was normal. Fundus examination of the left eye was within normal limits. Patient was advised to undergo excision biopsy and he underwent the same under topical anaesthesia. Conjunctiva was approximated with 6-0 vicryl sutures intermittently. Post operatively he was started on antibiotic steroid eye drops and was tapered slowly. Histopathology was suggestive of conjunctival reactive lymphoid hyperplasia of left eye. Patient was not ready for immunohistochemistry as they were not financially stable. He was also given a

course of oral steroids according to his weight and tapered. We also did not insist them as histopathology was more in favour of allergic etiology with lot of eosinophils (Fig. 2, 3). We explained them that they would have to take the same if there is recurrence. Chest X ray and ultrasonogram abdomen was normal. Patient is on follow up for more than 2 years with no recurrence. (Fig. 4)

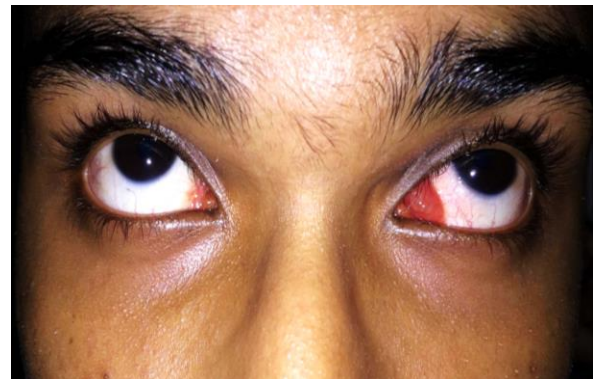


Fig. 1: External photograph of the patient showing nodular conjunctival lesion in the left eye

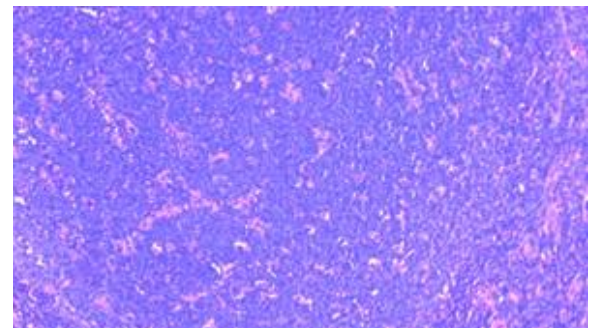


Fig. 2: Microphotograph showing the reactive follicle with numerous macrophages in the central portion of the follicle. (hematoxylin and eosin stain, magnification, 20x, inset showing the lower magnification of the reactive follicles)

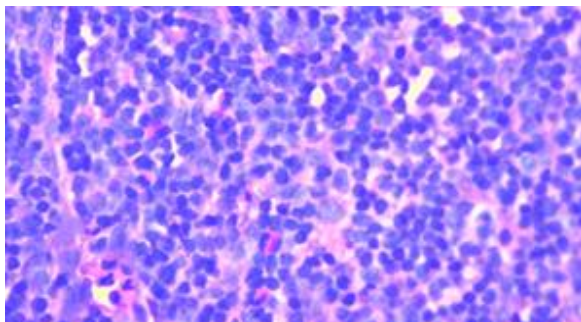


Fig. 3: Microphotograph showing the reactive follicle with numerous eosinophils. (hematoxylin and eosin stain, magnification 40x)

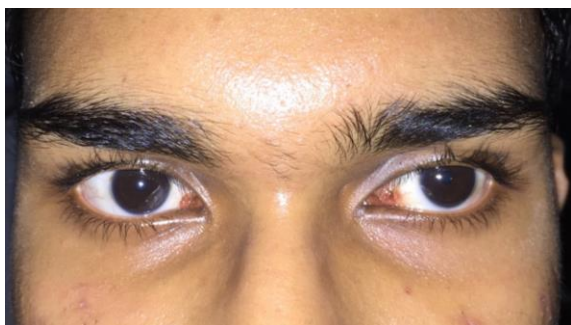

Fig. 4: External photograph of the patient at the end of 2 years

Discussion

Nodular lesions in the conjunctiva are not very common in childhood. The differentials which should be borne in mind are lymphoma and lymphoid hyperplasia⁽¹⁾ as they both resemble each other. Histopathological diagnosis is the key to differentiate both. Presence of cytologic atypia or Dutcher bodies is pathognomonic of malignant lymphoma.⁽²⁾

Ocular adnexa is the common site for the development of benign lymphoid hyperplasia. It can occur in the orbit, conjunctiva, lid and adnexa. Conjunctival lymphoproliferative lesions have the best prognosis among them.⁽³⁾ It has been reported that more than 90% of these lesions do not develop into systemic lymphoma.⁽⁴⁾ Lymphoid hyperplasia commonly affects males and for some unknown reason nasal bulbar conjunctiva is commonly affected.

The ocular adnexal lymphoproliferative lesions seem to have association with autoimmune diseases. They believed to be a consequence of chronic inflammatory response of lymphoid cells.^(5,6) The first phase during the immune response of inflammation involves IgE - mast cell sensitization and degranulation.⁽⁷⁾ It is followed by an intermediate phase which has neovascularization. Finally, it is the chronic response where there is induction of massive lymphoid hyperplasia, follicular formation with germinal centers, increased swollen goblet cells, extensive epithelial thickening and angiogenesis.

These lesions requires confirmation of diagnosis by

histopathological evaluation, immunophenotyping using either flow cytometry or immunohistochemistry (IHC) and molecular studies, such as immunoglobulin heavy chain PCR (IgH-PCR).⁽⁸⁾ We understand the importance of the phenotyping but our patient had classical signs of allergic lymphoid hyperplasia in histopathology and was not financially willing to undergo IHC. The characteristic feature in benign lymphoid hyperplasia is reactive follicles with numerous macrophages in the centre.⁽⁸⁾

There is no definitive recommended treatment for conjunctival BLH. Current treatments include cryotherapy, radiotherapy or surgical excision with steroids. In our case we had done excision biopsy and started on oral and topical steroids.⁽⁷⁾ Radio and chemotherapy has its own disadvantages of scarring and vascularization which is well documented. Doo Hwan Ho et al have tried subconjunctival bevacizumab in the treatment of such lesions.⁽⁹⁾

In cases associated with infectious etiologies (confirmed by PCR), antimicrobial therapy appears to be beneficial. However, reactive lymphoid hyperplasia associated with chronic Epstein - Barr virus infection is expected to produce a lymphoma in future compared with other etiologies.

We do imaging only if there is proptosis, diffuse lesion and resistance to retropulsion. In cases of lymphoma we do MRI to see for orbital involvement. In this patient we did not do imaging due to the above reason. MRI is ideal because there is no radiation hazard and soft tissue involvement will be delineated well.

Systemic involvement should be ruled out by evaluating complete blood count, serum protein electrophoresis, erythrocyte sedimentation rate, chest x-ray and ultrasonogram abdomen. Development of systemic lymphoma is associated with extent of disease at presentation and bilaterality.⁽¹⁰⁾ No consensus exists regarding guidelines specific to benign, localized conjunctival lesions in children that might be expected to have an extremely low probability of malignant transformation and extraocular extension. Therefore, the authors have recommended repeated evaluation for local recurrence every 6 months for 5 years.

Conclusion

Though rare nodular conjunctival lesions can occur in paediatric age. Reactive lymphoid hyperplasia in children tends to have a benign, self limited course. Surgical excision gives complete resolution. However, chance of recurrence and malignant transformation though minimal warrants periodic long term follow up for these patients. We present this case for its rarity and to insist the fact that immunohistochemistry may not be mandatory in all cases when there is a clear histopathological picture.

References

1. Frenkel S, Gaitonde SS, Azar N. Conjunctival marginal zone B-cell lymphoma in a 13-year-old child. *J Pediatr Ophthalmol Strabismus* 2011.
2. Medeiros L.J, Harris N.L. Lymphoid infiltrates of the orbit and conjunctiva A morphologic and immunophenotypic study of 99 cases. *Am J Surg Pathol* 1989;13: 459-71.
3. Knowles DM, Jakobiec FA, McNally L, et al. Lymphoid hyperplasia and malignant lymphoma occurring in the ocular adnexa (orbit, conjunctiva, and eyelids): a prospective multi parametric analysis of 108 cases during 1977 to 1987. *Hum Pathol* 1990;21:959–73.
4. Jo YJ, Yim JH, Park KS. MALT (mucosa associated lymphoid tissue) type lymphoma of the ocular adnexa. *J Korean Ophthalmol Soc* 2002;43:357-62.
5. Kubota, T, Moritani, S. High incidence of autoimmune disease in Japanese patients with ocular adnexal reactive lymphoid hyperplasia. *The American Journal of Ophthalmology* 2007;144:148.
6. Stacy, R.C, Jakobiec, F.A, Schoenfield, L, Singh, A.D. Unifocal and multifocal reactive lymphoid hyperplasia vs follicular lymphoma of the ocular adnexa. *American Journal of Ophthalmology* 2010;150:412 – 426.
7. Oh, D.E, Kim, Y.D. Lymphoproliferative diseases of the ocular adnexa in Korea. *Arch Ophthalmol* 2007;125:1668–73.
8. Al Akeely AG, Alkatan HM, Alsuhaibani AH, et al. Benign reactive lymphoid hyperplasia of the conjunctiva in childhood. *Br J Ophthalmol* 2016;:1–7.
9. Doo Hwan Oh, Yeoun Sook Chun, Jae Chan Kim .A Case of Ocular Benign Lymphoid Hyperplasia Treated with Bevacizumab Injection. *Korean J Ophthalmol* 2011;25:57-59.
10. Demirci H, Shields CL, Karatza EC, Shields JA. Orbital lymphoproliferative tumors: analysis of clinical features and systemic involvement in 160 cases. *Ophthalmology* 2008;115:1626-31.