

Incidence of dry eye, refractive error changes and recurrence rate in the management of pterygium by conjunctival auto grafting with or without mitomycin – C in a tertiary eye care center

Piyali Sarkar^{1,*}, Malsawmtluanga², Kumares Chandra Sarkar³

¹Associate Professor, North Bengal Medical College, West Bengal, ²PG Student, ³Assistant Professor, Dept. of Ophthalmology, Calcutta National Medical College, Kolkata

***Corresponding Author:**

Email: drpsar@yahoo.co.in

Abstract

Objectives: To compare dry eye changes, refractive error changes and recurrence rate of pterygium between the two techniques of conjunctival autografting and conjunctival autografting with intra operative application of mitomycin-c.

Materials and Methods: It was a hospital based prospective, randomized, interventional comparative study of 40 eyes of 38 patients among whom 20 eyes underwent pterygium excision with conjunctival autografting (group A) and rest 20 eyes underwent pterygium excision with conjunctival autografting and intra operative application of mitomycin-c (group B). The preoperative and postoperative one month Schirmer I test, tear film break up time (TBUT), best corrected visual acuity, spherical error and astigmatism were noted. They were followed up for six months and observed for recurrence of the pterygium. Statistical analyses were used to compare the two groups.

Results: 38 patients (40 eyes) diagnosed with primary pterygium were evaluated. 20 eyes with pterygium were treated with conjunctival autografting and 20 eyes with conjunctival autografting combined with intra operative application of mitomycin-c (0.02% for two minutes). At postoperative one month, there were one positive Schirmer I test in group A and two positive in group B which were not significant on comparison ($p=1.000$). There were three positive TBUT test in group A and one positive TBUT test in group B which was not significant ($p=0.598$).

For changes in astigmatism, 10 cases improved, seven cases showed no changes and 3 cases worsened in group A. In group B, 12 cases improved, seven cases showed no changes and one case worsened. On comparing the two groups it was statistically not significant ($p=0.541$). For spherical error changes, six cases improved, 11 cases showed no change and three cases worsened in group A. In group B, 5 cases improved, 10 cases showed no change and 5 cases worsened which was not significant ($p=0.725$). For BCVA (Best corrected visual acuity) change, 11 cases improved, 7 cases showed no change and 2 cases worsened in group A. In group B, there were 10 cases which improved and 10 cases showed no change. On comparing the two results, $p = 0.187$ which is not significant. There was a 5% recurrence rate (one eye) from the conjunctival autograft group. There were no significant difference in the rate of recurrence ($p=1.000$) between the 2 groups. No mitomycin-c related complication was observed during the length of the study.

Conclusion: Intra operative application of mitomycin-c does not induce dry eye. On refractive error changes, based on visual acuity, astigmatism and spherical error, there is no difference of outcome on using intra operative mitomycin-c. Conjunctival autograft surgery alone for primary pterygium is effective and safe in reducing the rate of recurrence of pterygium within six months.

Keywords: Pterygium, Refractive error changes, Recurrence, Conjunctival autografting, Mitomycin-C.

Introduction

Pterygium is a triangular fibrovascular subepithelial growth of degenerative bulbar conjunctival tissue encroaching over the limbus onto the cornea located commonly horizontally in the interpalpebral fissure on either nasal or temporal side of cornea or sometimes on both sides. It is considered as an elastotic degeneration of the subconjunctival tissues which proliferate as vascularized granulation tissue to invade the cornea destroying the superficial stroma and Bowman's membrane, the whole being covered by conjunctival epithelium. In early stages, it is thick and vascular, and becomes thin and pale when it ceases to progress. The real problem is in its successful management which is indicated either for cosmetic reasons or progression towards the visual axis or inflammatory changes or induced astigmatism.

The word pterygium means wings (Greek). The etiopathogenesis may be the degenerative process or chronic inflammation of the conjunctiva due to irritation from the elements like wind, dust and sunlight. Other factors may be heredity and occupation. UV-mediated inflammation may lead to ocular surface damage and tear film instability, ultimately resulting in epithelial cell apoptosis, goblet cell loss, a reduction in mucus secretion, and tear hyperosmolarity. Eventually, a vicious cycle develops in which tear hyperosmolarity itself leads to ocular surface inflammation.

Pterygium may cause flattening of the cornea. An induced astigmatism was explained by several mechanisms: Pooling of the tear film at the leading edge of the pterygium, and mechanical traction exerted by the cornea. Pterygium results in high corneal astigmatism, which decreases following an excision. The main challenge to successful surgical treatment of

pterygium is recurrence, evidenced by fibrovascular growth across the limbus onto the cornea. Regardless the technique used, excision of the pterygium is the first step for repair.

In this study we aim to evaluate if there is any beneficial effect of applying intraoperative mitomycin-C on dry eye, refractive error changes and recurrence rate after pterygium excision with conjunctival autografting.

Aims and Objectives

To compare the incidence of dry eye, the changes in refractive error and the recurrence rate after the excision of pterygium with conjunctival autografting with or without mitomycin-C.

Materials and Method

It was a prospective observational study conducted in department of Ophthalmology, Calcutta National Medical College & Hospital, Kolkata. The study period was one year (May '2014 to April '2015). 40 eyes of 38 patients were randomly distributed into two groups equally according to the technique of management. Group A: 20 patients by conjunctival autografting. Group B: 20 patients by conjunctival autografting with intraoperative mitomycin-C application(0.02% for 2 mins). Parameters studied were: Preoperative and postoperative tear break up time (TBUT) test, Schirmer- I test (Whatmann filter paper number 41), refraction (autorefractometer), best corrected visual acuity (BCVA) using Snellen's chart and keratometry reading (keratometer, Bausch & Lomb type).

All cases were studied according to the parameters stated above. Patients were enrolled within first six months of the study and each patient were followed up upto six months after treatment. Patients were enrolled after taking informed consent in their respective language. Inclusion criteria: All patients present with the primary pterygium willing to participate in the study were included. TBUT of less than 10 seconds were considered positive. TBUT of greater than or equal to 10 seconds were considered negative. Schirmer- I test less than 10 mm. of wetting were considered positive. More than or equal to 10 mm of wetting were considered negative. Recurrence was diagnosed when a fibro vascular growth in the position of previously excised pterygium crossing the limbus and extending on to the cornea for at least a distance of 0.5 mm. Statistical analysis was done by using SPSS (Statistical Package for Social sciences), version 20.0. Data was analyzed using standard statistical technique like tabulation, proportions, percentage, mean and standard deviation. Comparative analysis was performed using Chi-Square test. A probability value ('p' value) of < 0.05 was considered as statistically significant.

Results

The study population comprised of 38 patients (40 eyes). All the 40 pterygia were primary cases. They were subjected to two methods of management and followed up for a duration of six months.

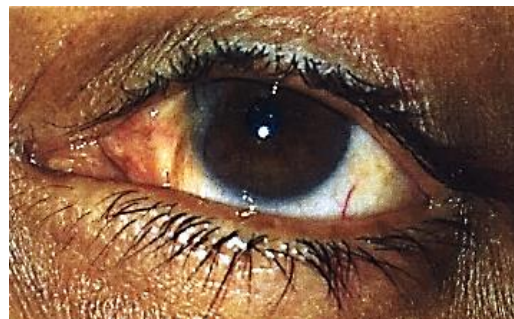

Fig. 1: Pre-operative

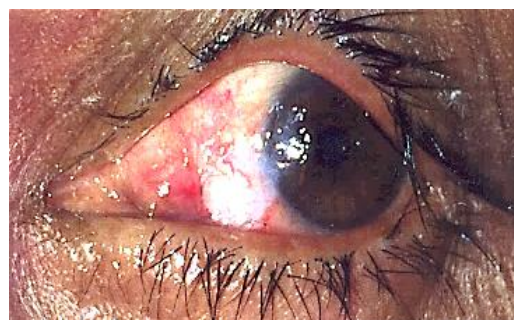

Fig. 2: Post-operative

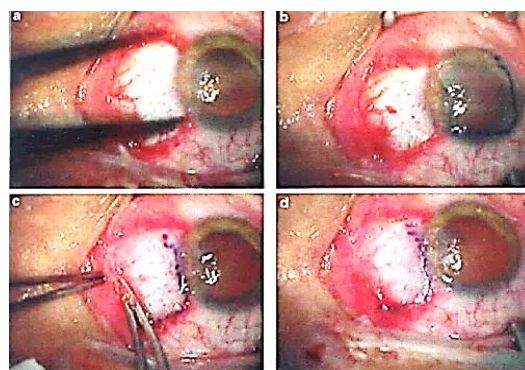


Fig. 3: Conjunctival Autograft Transplant (a) Measuring sclera bed size, (b) Placing the graft on the cornea, (c) Suturing graft to conjunctiva, (d) Graft fixed

Table 1: Sex distribution

Sex	No. of Pterygium	Percentage
Male	25	62.50%
Female	15	37.50%

The table shows that male patients were more than female patients.

Table 2: Age distribution

Age (in years)	No. of Patients	Percentage
21-30	13	32.50%
31-40	11	27.50%
41-50	12	30.00%
51-60	3	7.50%
>= 61	1	2.50%

The study shows pterygium was more common in younger and middle age group and decreased with the increase in age. Both eyes were equally involved. Among the 38 patients bilateral pterygium was present

in two patients which were taken for this study. In the remaining 36 cases, only right eye pterygium was taken for study in 18 cases and only left eye pterygium was taken in 18 cases.

Table 3: Occupational incidence of pterygium

Occupation	No. of Eyes	Percentage
Outdoor	23	57.50%
Indoor	17	42.50%

The study shows pterygium was seen more commonly in outdoor workers than in indoor workers.

Table 4: Relation between type of management and changes in Schirmer I test after four weeks of management using chi square test

Type of Management	Schirmer I (at 4 weeks)		Total	P value (using Yates' correction)
	Positive	Negative		
Conjunctival autografting without mitomycin-C	1	19	20	1.000
Conjunctival autografting with mitomycin-C	2	18	20	
Total	3	37	40	

Of the 40 pterygium cases, Schirmer I test at post-operative four weeks was compared between two groups. There were one positive Schirmer I test in group A and 2 positive in group B. On comparing the two results, P value = 1.000 was obtained by Chi square test which is not statistically significant. Based on Schirmer I test, the result shows that there is no significant difference of outcome between the two techniques.

Table 5: Relation between type of management and changes in TBUT after four weeks of management using Chi square test

Type of Management	TBUT (4 weeks)		Total	P value (using Yates' correction)
	Positive	Negative		
Conjunctival autografting without mitomycin-C	3	17	20	0.598
Conjunctival autografting with mitomycin-C	1	19	20	
Total	4	36	40	

Of the 40 pterygium cases, TBUT test at post operative four weeks was compared between two groups. Based on TBUT test, the result shows that there is no significant difference of outcome in the two technique of pterygium management.

Table 6: Relation between type of management and change in astigmatism after management using Chi square test

Type of Management	Change in Astigmatism			Total	P value (using Yates' correction)
	Improve	No Change	Worsen		
Conjunctival autografting without mitomycin-C	10	7	3	20	0.541
Conjunctival autografting with mitomycin-C	12	7	1	20	
Total	22	14	4	40	

Based on astigmatic changes, the result shows that there is no significant difference of outcome in the two techniques of pterygium management.

Table 7: Relation between type of management and change in spherical error after management using Chi square test

Type of Management	Change in Spherical error			Total	P value (using Yates' correction)
	Improve	No Change	Worsen		
Conjunctival autografting without mitomycin-C	6	11	3	20	0.725
Conjunctival autografting with mitomycin-C	5	10	5	20	
Total	11	21	8	40	

Based on spherical error changes, the result shows that there is no significant difference of outcome in the two technique of pterygium management.

Table 8: Relation between type of management and changed in BCVA after management using Chi square test

Type of Management	Change in BCVA			Total	P value (using Yates' correction)
	Improve	No Change	Worsen		
Conjunctival autografting without mitomycin-C	11	7	2	20	0.187
Conjunctival autografting with mitomycin-C	10	10	0	20	
Total	21	17	2	40	

Based on BCVA, the result shows that there is no significant difference of outcome in the two technique of pterygium management.

Table 9: Relation between type of management and recurrence of pterygium

Type of Management	Recurrence		Total	P value (using Yates' correction)
	Present	Absent		
Conjunctival autografting without mitomycin-C	1	19	20	1.000
Conjunctival autografting with mitomycin-C	0	20	20	
Total	1	39	40	

There is no significant relationship between type of management and recurrence of pterygium.

Discussion

40 pterygium cases (38 patients) were included in our study. They underwent pterygium excision and conjunctival autograft technique with and without intraoperative mitomycin-C application.

- Age distribution:** In our study, the patients were in the ages between 23-70 years. Highest numbers of patient were in the age group 21-30 years (32.5%). Lowest number of cases in the age group more than 60 years (2.50%). Mean age was 38.42 years in our study. In a study done by Riordan-Eva et al (1993),⁽¹⁾ ages of patients range from 25-77 years. Mean age in that study was 47 years. In another study done by Philip Chen et al (1995),⁽²⁾ ages of patients range from 23-79 years. Mean age in that study was 45.6 years. This correlates with the present study.
- Sex distribution:** In our study number of males included is 25 (62.50%) and females are 15 (37.50%), probably owing to the fact that males in the rural area working in the farms, and their counterparts from the urban area also working in outdoors and getting exposed to the UV rays, dust

and wind. In a study done by Riordan-Eva et al (1993),⁽¹⁾ 66 cases (61%) was males and 42 cases (38.89%) were females.

- Laterality:** In our study, 2 cases (5%) of pterygium were bilateral and 38 cases (95%) of pterygium were unilateral.
- Operated eye:** In our study, 20 cases (50%) operated were right eye and 20 cases (50%) were left eye. In a study done by Riordan-Eva et al (1993)¹, 65 cases (60.19%) operated were right eye and 52 cases (48.15%) operated were left eye.
- Dry eye changes:** In our study, postoperatively there were one positive Schirmer I in group A and two positive in group B. On comparing group A and group B, we obtained p=1.00 which is not statistically significant. There were three positive TBUT test in group A and one positive TBUT test in group B. On comparing group A and group B, p=0.598 which is not statistically significant. Lam J et al (2015)⁽³⁾ study of 12 glaucoma patients for ocular surface disease in post-trabeculectomy with mitomycin-C patients found that mean tear breakup time (TBUT) was 5.32 seconds and mean Schirmer

score was 6.14 mm. They concluded that possible major risk factors for ocular surface disease in the cases include limbal stem cell deficiency occurring from exposure to anti-metabolites (mitomycin-C). Farahi A et al. (2013)⁽⁴⁾ studied 27 patients to assess the effects of adjuvant mitomycin-C on tear function tests after photo refractive keratectomy (PRK) for myopia. They concluded that intraoperative use of mitomycin-C during PRK did not induce tear deficiency. Kemal Turkyilmaz et al. (2013)⁽⁵⁾ suggested that tear hyperosmolarity and abnormal tear film function are associated with pterygium. Pterygium excision improved tear osmolarity and tear film function. However, tear osmolarity deteriorated again with the recurrence of pterygium.

6. **Refractive error changes:** In our study, refractive error changes of group A and group B were compared based on astigmatic changes, spherical error changes and BCVA. On comparing astigmatic changes of group A and group B, we obtained $p=0.541$ which is not significant. Spherical error changes of group A and group B were compared with $p=0.725$ (not significant). On comparing BCVA changes of group A and group B, $p=0.187$ which is not significant. Yilmaz S, et al (2008)⁽⁶⁾ in a study to evaluate effects of different pterygium surgeries on corneal topography, pre and post-operative computerized videokeratography was performed on 120 eyes of 115 patients undergoing pterygium removal. The amount of corneal steepening was 0.06 ± 0.5 for conjunctival autograft and 1.70 ± 0.4 for mitomycin-C. The mitomycin-C group produce the maximum induced astigmatism and the limbal-conjunctival autograft group produced the least induced astigmatism. Although pterygium surgery significantly reduces refractive astigmatism and topographic irregularity, spherical power increases and the cornea become steeper. Claus Pommerencke, et al (1998)⁽⁷⁾ studied the outcome of single application of mitomycin-C in primary pterygium surgery. Corneal astigmatism were generally reduced, average was 1.2 D, after surgery (subtraction method). The astigmatism was reduced in 12 eyes (63%), increased in five eyes (26%), while no change was observed in one eye and not measurable in another eye.
7. **Recurrence of pterygium:** In our study there was a recurrence of one case (2.5%) in conjunctival autograft technique and no recurrence in conjunctival autograft with intra operative mitomycin-C application with no significant difference ($p=1.000$) in recurrence rates between the two groups. Archimedes, et al (2014)⁽⁸⁾ in a study to compare the recurrence rate after conjunctival autograft alone versus conjunctival autograft with mitomycin-C in the treatment of

pterygium, there was no significant difference in the rate of recurrence ($p=0.53$) between the two treatments for both primary and recurrent pterygium. Wong, et al (1998)⁽⁹⁾ compared conjunctival autografting alone versus conjunctival autografting with intraoperative MMC in primary pterygium and reported a significant difference ($p<0.03$) in recurrence rates between the two groups.

Singh G, et al (1990)⁽¹⁰⁾ in a study of 48 patients for 7-21 months concluded that placebo treated pterygium showed 73% recurrence rate compared to 6.6% with conjunctival autograft technique and 1.7% with mitomycin-C. Chen P, et al (1995)⁽¹¹⁾ concluded that recurrence rate after mitomycin-C and conjunctival autograft was 38% and 39% respectively after a mean follow up 12.3 months. Sanchez-Thorin JC, et al (1998)⁽¹²⁾ concluded that odds for pterygium recurrence following surgical treatment of primary pterygium are closed to 6 and 25 times higher if no conjunctival autografting is done or if no intraoperative mitomycin-C is used respectively.

8. **Complains:** In our study, the most frequent complaint was ocular irritation followed by redness and defective vision. There were no cases with complaints of post-operative diplopia.
9. **Complications:** In the present study we didn't encounter any intra-operative complication. Minor post-operative complications included two cases of loose suture(vicryl-8-0) which didn't require removal.

Summary

40 pterygia in 38 patients were selected for comparative study of dry eye changes, refractive error changes and recurrence rate of pterygium between the two techniques of pterygium excision with conjunctival autografting with or without intra operative application of mitomycin-C after obtaining informed consent from the patient. They were followed up for a period of six months. In this study, 40 cases were divided randomly into two groups of 20 each. First group underwent pterygium excision with conjunctival autografting, second group underwent pterygium excision with conjunctival autografting with 0.02% of intraoperative mitomycin-C for two minutes. In all the eyes, pterygium head was separated from the cornea by peeling technique. This resulted in a smooth corneal surface, which speeded up the epithelization of cornea and resultant in minimum or no opacity of the cornea after excision.

Males outnumbered females and constituted 62.50% of the patients. The maximum number of patients (13 cases, 32.50%) were present in the age group of 21-30 years. Both eyes were equally involved. Outdoor workers were commonly affected (23 cases, 57.50%) compared to indoor workers (17cases, 42.50%). On comparing dry eye changes between the

two groups at post-operative 4 weeks, there was one positive Schirmer I test in group A and two positive in group B ($p=1.000$) and there were three positive TBUT test in group A and one positive in group B ($p=0.598$), there were no significant differences. On comparing refractive error changes at post-operative four weeks, for BCVA 11 cases improved, seven cases showed no change and two cases worsened. In group B, 10 cases improved and 10 cases showed no change ($p=0.187$), which is statistically not significant.

For spherical error changes, 6 cases improved, 11 cases showed no change and 3 cases worsened in group A and five cases improved, 10 cases showed no change and 5 cases worsened in group B ($p=0.725$) which is not statistically significant. For astigmatic changes, 10 cases improved, 7 cases showed no changes and 3 cases worsened in group A and 12 cases improved, 7 cases showed no changes and 1 case worsened in group B ($p=0.541$), there was no significant differences. There was 1 recurrence in conjunctival autografting group, while there was no recurrence in intra operative mitomycin-C group ($p=1.000$) which is not significant. There was no intra operative and post-operative major complication. Minor complications like foreign body sensation, irritation and watering were present in few eyes managed by both the methods, because of exposed sutures.

Conclusion

The results obtained in the present study were analyzed and the following conclusions were reached:

- Intraoperative application of mitomycin-C does not induce dry eye.
- On refractive error changes based on visual acuity, astigmatism and spherical error, there is no difference in outcome on using intraoperative mitomycin-C.
- Incidence of recurrence after pterygium surgery with conjunctival auto grafting is very low making the use of antimetabolites unnecessary.

References

1. Riordan – Eva P, Kielhorn I, Ficker LA. Conjunctival autografting in the surgical management of pterygium. *Eye* 1993;7:634-638.
2. Chen Philip Reginald G Ariyasu, Venu Kaza. A randomized trial comparing Mitomycin C and conjunctival autograft after excision of primary pterygium. *American Journal of Ophthalmology* 1995;120:151-160.
3. Lam J, Wong TT, Tong L. Ocular surface disease in post trabeculectomy/mitomycin C patients. *Clin Ophthalmol*. 2015 Jan 29;9:187-91.
4. Farahi A, Hashemi H, Mehravaran S. The effects of mitomycin C on tear function after photorefractive keratectomy: a contralateral comparative study. *J Refract Surg*. 2013 Apr;29(4):260-4.
5. Kemal Turkyilmaz, Veysi Oner, Mehmet Sahin Sevim. Effect of pterygium Surgery on Tear Osmolarity. *Journal*

- of *Ophthalmology* Volume 2013 (2013), Article ID 863498, 5 pages.
6. Yilmaz S , Yuksel T, Maden A. Corneal topographic changes after four types of pterygium surgery. *J Refract Surg*. 2008 Feb; 24(2):160-5.
7. Claus Pommerencke. Single application mitomycin C in primary pterygium surgery. *Acta Ophthalmol. Scand*. 1998; 75: 360-362
8. Archimedes L.D. Agahan, MD, Pamela P. Astudillo, MD. Comparative Study on the Use of Conjunctival Autograft with or Without Mitomycin-C in Pterygium Surgery. *Philipp J Ophthalmol* 2014;39:73-77.
9. Wong VA, Law FC. Use of mitomycin-C with conjunctival autograft in pterygium surgery in Asian-Canadians. *Ophthalmology* 1999;106:1512-5.
10. Singh G, Wilson MR, Foster CS. Long term follow-up study of mitomycin eye drops as adjunctive treatment for pterygia and its comparison with conjunctival autograft transplantation. *Cornea* 1990;9:331-4.
11. Chen PP, Ariyasu RG, Kaza MD, et al. A randomized trial comparing mitomycin C and conjunctival autograft after excision of primary pterygium. *Am J Ophthalmol* 1995;120:151-60.
12. Juan Camilo Sanchez-Thorin, Guillermo Rocha, Julie B Yelin. Meta-analysis on the recurrence rates after bare sclera resection with and without mitomycin C use and conjunctival autograft placement in surgery for primary pterygium. *Br J Ophthalmol* 1998;82:661-665.