

Intraocular cysticercosis with macular hole – an unusual presentation

Manmath Kumar Das^{1,*}, Priyanka Chaudhary², Abhishek Varshney³

^{1,3}Consultant, ²Fellow, Vitreo-Retina Services, CL Gupta Eye Institute, Moradabad,

***Corresponding Author:**

Email: drmanmathkumar@yahoo.com

Abstract

We report a case of a 23-year-old young male who was diagnosed with multiple intracranial cysticercus lesions and was on antiepileptic drugs, after which he presented with painless decrease of vision in his left eye with a BCVA of 20/250. Indirect ophthalmoscopic examination showed vitritis with live intravitreal cyst over macula with a visible scolex in this eye. Ultrasound B-scan confirmed the well-circumscribed cyst with its hyperechoic scolex. Right eye fundus examination was normal. Patient underwent a standard three-port pars plana vitrectomy for cyst removal. Surprisingly after cyst aspiration a full thickness macular hole was noted intraoperatively for which ILM peeling was done followed by 14% C3F8 gas tamponade.

Keywords: B-scan ultrasonography, Full thickness macular hole, Intraocular cysticercosis, Vitrectomy

Introduction

Cysticercosis, a well-known cause of infection in developing countries like India is caused by *Cysticercus cellulosae*, the larval form of the pork tapeworm, *Taenia solium*. It is contracted by ingestion of under-cooked pork, contaminated water or vegetables.⁽¹⁾ Cysticercosis may be located anywhere in the body, but are most commonly found in the skeletal muscle, subcutaneous tissue, and brain causing neurocysticercosis. Ocular cysticercosis can involve the ocular adnexa, the subconjunctival space, anterior and posterior segments of the eye, but most commonly seen in the vitreous cavity or subretinal space.⁽²⁾ Though, vitritis, macular scarring, retinal vasculitis and retinal detachment are well known complication of intraocular cysticercosis,⁽³⁾ macular hole as a complication of intraocular cysticercosis has not been reported in literature. The accepted treatment for intraocular cysticercosis is complete surgical removal of the intact cyst.⁽⁴⁾ To the best of our knowledge this is the first report of full thickness macular hole due to intraocular cysticercosis.

Materials and Methods

Retrospective review of medical case record.

Results

A 23-year-old vegetarian male, presented with a history of painless decrease of vision in his left eye for 18 days. He was diagnosed with neurocysticercosis and MRI brain revealed multiple small cystic intraparenchymal lesions in bilateral parietal lobe and right temporal lobe. Patient had episodes of seizures and was on antiepileptics. Best corrected visual acuity in his right eye was 20/20 and left eye was 20/250. Intraocular pressure by applanation tonometer was 14 and 12 mm Hg in the right and the left eye, respectively. Slit lamp examination of the right eye was normal. Left eye examination revealed circumcorneal congestion with anterior uveitis and mild vitritis. Fundus examination of

left eye showed a live cyst with a visible scolex projecting into the vitreous cavity and adherent to the retina over macula (Fig. 1A). Ultrasound B-scan confirmed the well-circumscribed cyst with its hyperechoic scolex. There was no evidence of adnexal, orbital or extraocular muscle involvement. Right eye fundus examination was normal. Based on the above findings a clinical diagnosis of live intraocular cysticercosis with neurocysticercosis was made. Patient underwent a standard three-port 23 gauge pars plana vitrectomy for cyst removal. Intraoperatively after cyst excision a full thickness macular hole was noted, so ILM peeling was done after induction of complete PVD. Brilliant blue dye was used to stain the ILM. 5 weeks postoperatively, vitritis resolved and BCVA improved to 20/160 (Fig. 1B). Spectral-domain optical coherence tomography (SD-OCT) demonstrated type 2 closure of macular hole (Fig. 2).

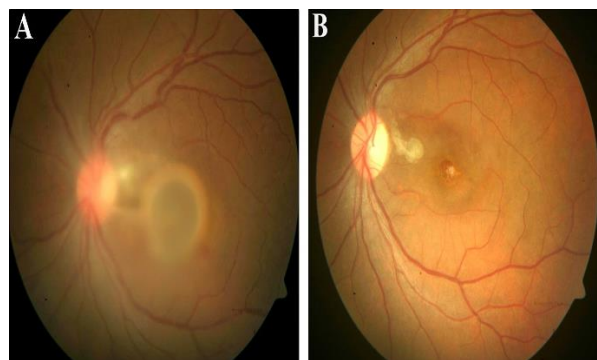


Fig. 1: Fundus Photo. (A) showing live intraocular cyst over macula preoperatively and (B) showing full thickness macular hole after cyst removal

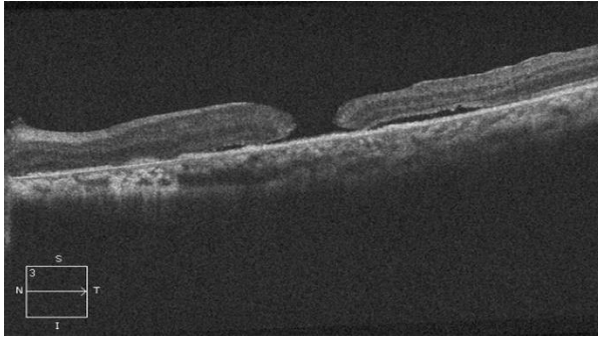


Fig. 2: Optical Coherence Tomography (OCT) of macula demonstrating Type 2 closure of full thickness macular hole postoperatively

Discussion

Co-infection of neuro-cysticercosis and intraocular cysticercosis is a common presentation. Our patient had history of seizures as epilepsy is the most frequent symptom of neurocysticercosis.⁽⁵⁾ Ocular cysticercosis may involve extraocular structures such as subconjunctival or orbital tissue as well as intraocular tissues including vitreous, subretinal space, or anterior chamber.

Intraocular cysticercosis may result in severe visual loss either because of compression from enlarging cyst or inflammatory reaction to cyst wall. Also toxin released from ruptured or dying cyst can incite a severe inflammatory reaction.⁽⁶⁾ Among the intraocular cysts, 60% are found intravitreally and 40% are subretinal. In our case also cyst was present in the vitreous cavity lying adherent to macula.

However intraocular cyst may result in retinal detachment, macular scarring, retinal vasculitis and vitritis but macular hole as a complication have never been reported before. Chronic ocular inflammation can lead to neovascular glaucoma.⁽⁷⁾ Rarely, vitreous hemorrhage may occur due to rupture of damaged blood vessels due to severe inflammatory reaction.⁽⁵⁾

Although destruction of the larvae in situ by photocoagulation, cryotherapy, and diathermy has been attempted with some success, early surgical removal of the parasite is the treatment of choice.⁽³⁾ Antihelminthic therapy is contraindicated because lysis of cyst may induce severe intraocular inflammation resulting in marked visual loss. If there is coexisting neurocysticercus, even then surgical removal of intraocular cyst must be done first, followed by cysticidal drugs and corticosteroids.

Posterior segment intraocular cysticercosis could be successfully removed, either by a transscleral or transvitreal route, depending on location. For intravitreal and subretinal cysts posterior to the equator transvitreal approach is preferred.⁽⁵⁾ In present case also, standard three port pars plana vitrectomy via transvitreal route was done with cyst aspiration along with ILM peeling, fluid air exchange followed by gas tamponade (14% C3F8). Cyst was separated from all vitreous attachments

and removed by aspiration only, without cutting as cutting the cyst in situ may release the toxic contents leading to postoperative inflammation as compared to intact cyst excision. Natarajan et al in his study also supported intact cyst aspiration without cutting. However, Sharma et al found no difference in the anatomic or functional outcome between the two.

It is postulated that the parasite enters the retina either through central retinal artery or through high flow choroidal circulation which subsequently migrates to the subretinal space and then into the vitreous through a hole in the retina resulting in a chorioretinal scar.^(3,5) Our patient had cyst over the macula, so the parasite presumably gained access into the vitreous through fovea and there is a possibility that during its passage had created a hole over there. Though macular hole was not visible preoperatively as cyst was lying over it, but intraoperatively after cyst excision it was clearly seen.

Our patient had Type 2 closure of macular hole demonstrated by OCT, which might have contributed to reduced visual acuity post operatively. Usually parasite or cyst damages the choroid, retina and vessels at their site which might possibly prevent the apposition of retinal layers resulting in incomplete closure of macular hole.

Our patient had simultaneous coinfection of brain and eye along with macular hole, which has not been reported so far.

References

1. White A, Weller P. Cestodes. In: AS Fauci EB, E Braunwald, DL Kasper, editors. Harrison's Principles of Internal Medicine, 17th ed. New York: McGraw-Hill; 2008.
2. Wender J, Rathinam S, Shaw R, Cunningham ET. Intraocular Cysticercosis: Case Series and Comprehensive Review of the Literature. *Ocular Immunology and Inflammation* 2011;19(4):240-245.
3. Sharma T, Sinha S, Shah N, Gopal L, Shanmugam MP, Bhende M et al. Intraocular cysticercosis: clinical characteristics and visual outcome after vitreoretinal surgery. *Ophthalmology* 2003;110(5):996-1004.
4. Natarajan S, Malpani A, Kumar NP, Dutta B. Management of intraocular cysticercosis. *Graefes Arch Clin Exp Ophthalmol* 1999;237:812-814.
5. Jain R, Bhana I, Kumar S. Ocular cysticercosis with vitreous hemorrhage: a rare complication of a common disease. *Springer Plus* 2015;4:217
6. Rath S, Honavar SG, Naik M, Anand R, Agarwal B, Krishnaiah S et al. Orbital cysticercosis: clinical manifestations, diagnosis, management, and outcome. *Ophthalmology* 2010;117(3):600-605.
7. Ratra D, Phogat C, Singh M, Choudhari NS. Intravitreal cysticercosis presenting as neovascular glaucoma. *Indian J Ophthalmol* 2010;58:70-73.