

Sclerotic Fibroma of the Orbit

Jayanta Kumar Das¹, Richa Shrivastava^{2,*}, Dipankar Das³, Apurba Deka⁴

^{1,3,4}Sri Sankaradeva Nethralaya, Guwahati, Assam, ²BRDMC, Gorakhpur, Uttar Pradesh

***Corresponding Author:**

Email: shri.rich.shri.rich@gmail.com, shri.rich@yahoo.co.in

Abstract

Solitary sclerotic fibroma is a rare benign tumor affecting skin and other underlying tissues. These tumors occur mostly in adult persons and involve face and limbs. Multiple tumors are also associated with Cowden syndrome. We present a case of solitary sclerotic fibroma in a 28 years old female with clinical and pathological documentation.

Keywords: Cowden syndrome, Hamartoma, Multiple hamartoma syndrome, Sclerotic fibroma

Introduction

Solitary sclerotic fibroma is a rare, benign and localized tumor comprising of hypo-cellular areas, spindle cells and fibro-collagenous structures. These fibromas occur mostly in adult population and affect both sexes almost equally. Solitary forms have no site predilection. These fibromas occur mostly in the head & neck region and extremities.⁽¹⁾ Clinical differentiation of this tumor has been often difficult but histopathological evidences help in definite diagnosis and to differentiate it from other similar lesions. Multiple sclerotic fibromas are known to be associated with Cowden syndrome. Cowden syndrome is also known as 'multiple hamartoma syndrome' and is characterized by multiple hamartomas involving skin, mucus membrane, thyroid gland, breast tissue and other organs. Though hamartomas are benign, increased risk of malignancy involving breast, thyroid gland, uterus and kidney has been found.⁽²⁾

Case Report

A 28 years-old female presented with a swelling on the nasal side of the right eye (OD) for one year duration in December 2015. The swelling was painless and was gradually increasing in size. There was no history of trauma, surgery, any other significant ocular or systemic history. Personal and family history was unremarkable. On examination, best corrected visual acuity in both eyes (OU) was 6/6. Ocular motility on examination was normal. A mass was noted on the medial wall of right orbit which was firm in consistency, non-tender and was adherent to underlying bone. On slit-lamp examination; lids, adnexa, anterior segment and part of posterior segment were normal. Intraocular pressure was 18mmHg in OU. Syringing was done which showed patent nasolacrimal duct (NLD) in OU. Fundus examination was unremarkable in OU.

Computerized tomography (CT) scan of orbit and brain showed a round to oval soft tissue density mass, measuring 10mm X 6mm over the medial wall of the right orbit.

Patient was counselled and anterior orbitotomy was planned under local anaesthesia. A curvilinear incision of 10mm was made just over the lesion. Mass was visible in operative field just below the skin (Fig. 1 a). With adequate blunt dissection, whole extent of mass was identified. It was attached to underlying lacrimal bone. Anterior limb of medial palpebral ligament (MPL) was not separately identifiable. Mass was successfully dissected from bone by blunt dissection. It was (10 X 8 X 6) mm approximately, solid and hard in consistency. Both canaliculi, lacrimal sac, posterior limb of MPL and NLD were intact. Intra-operative and postoperative period was uneventful. On subsequent follow-ups, patient maintained normal vision, with no symptoms and without any recurrence till last follow-up.

The specimen was examined in the ocular pathology laboratory at the institute. Grossly, it was greyish lobular lesion measuring (9.9 X 7.8 X 5.2) mm. Cut section showed greyish white lesion at the center (Fig. 1). Microscopically, the lesion was hypo-cellular with few spindle cells embedded in fibro-collagenous matrix arranged in form of whorls and fascicles. Some hyaline changes were also found in the specimen. Tumor had nodular arrangement containing those structures with multiple clefts within them and had plywood like appearance (Fig. 2). Masson's trichrome stain showed bluish color in the collagen throughout (Fig. 2). Lesion was histopathologically reported as sclerotic fibroma of right orbit. Patient was screened for presence of similar or any other type of lesion in other parts of body. Referral to other specialties was also done. No finding suggestive of cowden syndrome could be found.

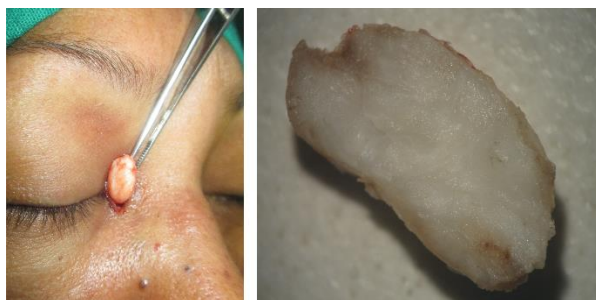

Fig. 1: Showing gross per-operative appearance and cut section of the tumour

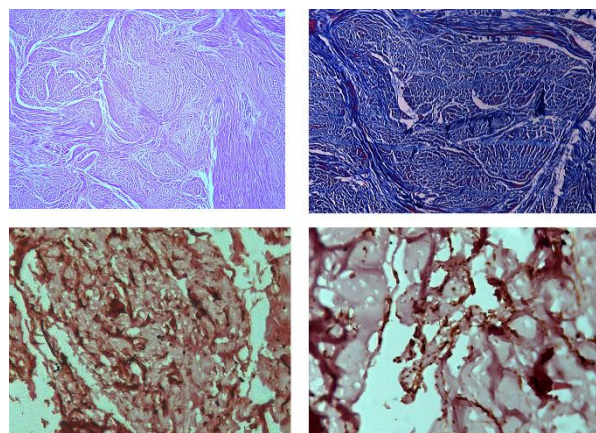


Fig. 2: Showing a cellular fibro-collagenous tissue in a plywood like appearance in H&E stain (X200) (upper left); Masson's trichrome stain showing blue colour background of fibro-collagenous structures in the same tumour (X200) (upper right); IHC showing vimentin (+) (Mouse monoclonal antibody, V-9, BioGenex, Fremont; CA 94538, USA, X200) (lower left); IHC showing focal positivity with CD34 (Mouse monoclonal antibody, QBEnd/10, BioGenex, Fremont; CA 94538, USA) (lower right)

For further confirmation, Immunohistochemistry (IHC) was done. Specimen was positive for vimentin (Mouse monoclonal antibody, V-9, BioGenex, Fremont; CA 94538, USA) (Fig. 2), focally positive for CD34 (Mouse monoclonal antibody, QBEnd/10, BioGenex, Fremont; CA 94538,

USA) (Fig. 2) and negative for S100 (Mouse monoclonal antibody, 15E2E2, BioGenex, Fremont; CA 94538, USA).

Patient was screened for presence of similar or other kind of lesions in other parts of body. Patient was referred to various other speciality clinics to rule out any other sign of Cowden syndrome. No finding suggestive of Cowden syndrome could be found at the time of presentation of the patient.

The tenets of the Helsinki declaration were followed. Informed consent for surgical intervention and case report was taken from the patient.

Discussion

Solitary sclerotic fibroma is a benign tumor seen in sub-cutis and found in young patients. Solitary sclerotic fibroma in patients without evidence of Cowden syndrome was first described in medical literature by Rapini and Golitz 1989.⁽³⁾

Clinically, the tumor is usually painless and present as nodule or papule. Mostly, skin is involved in this type of tumor but there are few cases of tendon sheath and oral involvement.^(4,5) One rare case of nasolacrimal duct involvement has been reported by Prasher.⁽⁶⁾ In present case, lesion was located in sub-dermal space, adherent to lacrimal bone. Differential diagnosis for this tumor included lacrimal sac lesions which could be easily ruled out by patency on syringing and healthy lacrimal sac per-operatively.

Tumor appeared to be of fibrous origin on histopathology. Tumor showed pauci-cellularity with spindle cells in dense collagenous matrix. Prominent clefts were present within nodular arrangement of matrix. Other benign, locally aggressive and low grade malignant soft tissue tumors consisting of stellate or spindle-shaped cells in a myxo-collagenous matrix include fibromatosis, fibroma of tendon sheath, collagenous fibroma, neurofibroma, solitary fibrous tumor, low-grade fibromyxoid sarcoma and solitary fibrous tumor. Hypocellularity, absence of any other cell type and demonstration of prominent clefts in plywood appearance as reported in previous studies, guided to the diagnosis. On review of literature, it was found that this lesion classically presents with similar features.⁽⁷⁾

Histogenesis of sclerotic fibroma is uncertain till now. Due to its association with Cowden syndrome it appears to have hamartomatous origin.⁽⁷⁾ Similarity to dermatofibroma has also been noted by some researchers.⁽³⁾ Due to increased cellularity in some cases, possibility of neoplasm development in later stages of lesion is also suspected.⁽⁸⁾ Whether it has true hamartomatous origin or degenerating end of various other fibrous lesions or a middle stage in neoplasm development is still controversial.

On immunohistochemistry, sclerotic fibroma is positive for Vimentin and CD34, negative to S100, Neuron specific enolase, Carcino embryonic antigen and Epithelial membrane antigen.⁽⁹⁾

Treatment of choice in this type of tumor is excision. Till now, recurrences have been reported in two cases. Increased cellularity of the lesion and incomplete excision might be the cause for recurrences in these reports.^(8,10) Till date malignant transformation and metastasis have not been reported.

Sclerotic fibroma involving sub-dermal space is unique of its kind. This tumor may rarely present as a swelling in lacrimal fossa region. Thus, sclerotic fibroma is a rare tumor with varied presentations posing a clinical and pathological challenge to diagnosis.

Declaration of interest

The authors report no conflict of interest. The authors alone are responsible for the content and writing of the paper.

References

1. Pernet C, Durand L, Bessis D, Guillot B, Dereure O. Solitary sclerotic fibroma of the skin: a possible clue for Cowden syndrome. *Eur J Dermatol.* 2012;22(2):278-9.
2. Weary PE, Gorlin RJ, Gentry WC, et al. Multiple hamartoma syndrome (Cowden's disease) *Arch Dermatol.* 1972;106.
3. Rapini RP, Golitz LE. Sclerotic fibromas of the skin. *J Am Acad Dermatol.* 1989;20(2 Pt 1):266–271.
4. Alawi F, Stratton D, Freedman PD. Solitary fibrous tumor of the oral soft tissues: a clinicopathologic and immunohistochemical study of 16 cases. *The American journal of surgical pathology.* 2001 Jul 1;25(7):900-10.
5. Watanabe T, Sasaki T, Ogata F, Okochi H, Furue M. Sclerotic fibroma of tendon sheath. *Dermatology.* 1997;195(3):263-5.
6. Prasher P. Solitary sclerotic fibroma as a rare cause of nasolacrimal duct obstruction. *Orbit.* 2008 Jan 1;27(6):441-3.
7. Donati P, Amantea A, Carducci M, et al. Sclerotic (hypocellular) fibromas of the skin. *Br J Dermatol.* 1991;124(4):395–396.
8. McCalmont TH. Sclerotic fibroma: a fossil no longer. *Journal of cutaneous pathology.* 1994 Feb 1;21(1):82-5
9. Hanft VN, Shea CR, McNutt NS, et al. Expression of CD34 in sclerotic (“plywood”) fibromas. *Am J Dermatopathol.* 2000;22(1):17–21.
10. Cohen PR, Tschen JA, Abaya-Blas R, Cochran RJ. Recurrent sclerotic fibroma of the skin. *Am J Dermatopathol.* 1999;21:571–574.