

En bloc excision of optic nerve sheath meningioma of the orbit preserves the eyeball and ocular motility when the tumor has not spread beyond the orbit

Ramesh Murthy^{1,*}, Himika Gupta²

¹Consultant Oculoplasty Surgeon, ²Clinical Associate, Oculoplasty Service, Axis Eye Clinic & Deenanath Mangeshkar Hospital, Pune, Maharashtra

***Corresponding Author:**

Email: drrameshmurthy@gmail.com

Abstract

A 53 year old lady presented with gradually progressive proptosis of the left eye and complete vision loss. Imaging was suggestive of optic nerve sheath meningioma confined to the orbit with no intracranial component. Total excision of the tumor along with the optic nerve was performed, sparing the eyeball. At two years follow up the patient was disease free with good ocular motility. En bloc excision is a good option compared to exenteration in intraorbital optic nerve sheath meningiomas with preservation of the eyeball and ensuring good cosmesis.

Introduction

Tumors of the optic nerve can be broadly classified into intrinsic tumors and those of the optic nerve sheath. While glioma is the most common intrinsic optic nerve tumor, meningiomas are the commonest in the latter group. Primary optic nerve sheath meningioma is a neoplasm originating from the cap cells of the arachnoid surrounding the optic nerve.⁽¹⁾ Treatment options depend on the extent and severity of the lesion. Common indications for surgery include intracranial extension and complete visual loss with associated proptosis.⁽²⁾ Though visual prognosis remains poor, surgery aims at removing disease and giving the most appropriate cosmetic outcome. The authors report a case of primary optic nerve sheath meningioma managed with en bloc excision of the tumor with optic nerve, by lateral orbitotomy approach, preserving the eyeball and ocular motility.

Case Report

A 52 year old lady presented with left sided loss of vision and proptosis noticed since 6 months. On examination her right eye vision was 20/20 and anterior and posterior segment was normal. The left eye had no perception of light, and fundus examination revealed optic atrophy. She had 2 mm of proptosis and restricted ocular movements in all gazes (Fig. 1). There was no lagophthalmos and corneal sensations were preserved.

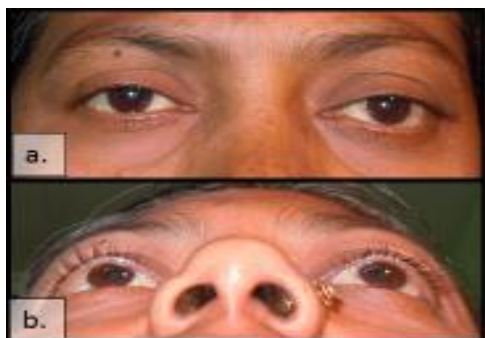

Fig. 1a, b: Left sided mild proptosis

Imaging revealed a calcified mass involving intra orbital optic nerve with tram track appearance (Fig. 2). There was no involvement of the eyeball, orbital apex or intracranial course of optic nerve. The patient underwent lateral orbitotomy using Berkes approach. En bloc excision of the tumor with optic nerve was performed. Proximally 4mm tumor free margin was taken and distally optic nerve was transected just before its insertion into the eye ball. Care was taken to preserve the extraocular muscles and orbital apex structures. Post operatively, patient had ptosis which resolved spontaneously over 6 weeks.

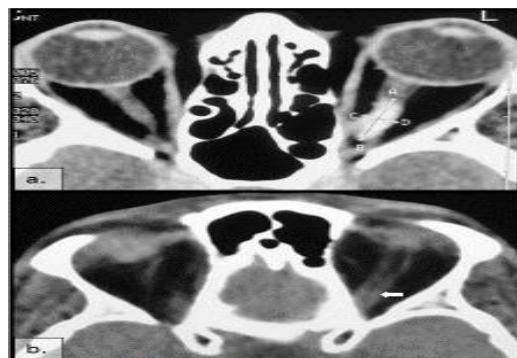


Fig. 2a: Computed tomography of orbit showing a diffuse calcified mass in left optic nerve, sparing the apex & the eye ball, b: Tram track appearance of the tumor

Histopathology of the tumor revealed meningothelial cells arranged in syncytial pattern with clear nuclei and psammoma bodies (Fig. 3a). At 12 months follow up, patient was disease free with satisfactory cosmesis and preserved ocular motility (Fig. 3c).

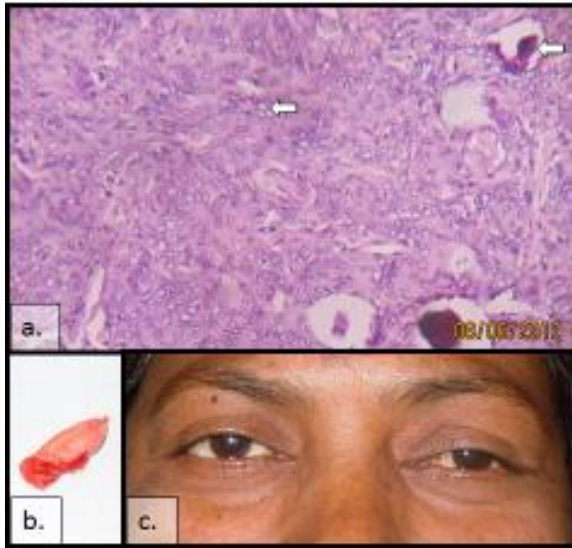


Fig. 3a: Histopathology showing meningotheelial cells having clear nuclei in a syncytium with psammoma bodies, b: Gross specimen of excised tumor, c: Post-operative appearances

Primary optic nerve sheath meningiomas are generally benign and slow growing, producing progressive visual loss. Their management is not straight forward and choice of treatment depends on age, location, visual affection and extent of tumor.⁽³⁾ For meningiomas confined to orbit alone, surgery is indicated when there is complete visual loss, or threatened intra cranial extension. Various surgeries like en bloc excision, exenteration, craniotomy, optic nerve decompression have been described.⁽²⁾ Tumor excision sparing the optic nerve is generally not feasible due to the diffuse and infiltrative nature of tumor. The visual outcome in optic nerve meningiomas remain grave with very few exceptions.^(2,4) Conformal or stereotactic radiation therapy tends to delay the visual loss in primary optic nerve sheath meningiomas, but indications and long term benefits are yet to be clearly established.⁽¹⁾

In orbital meningiomas with no vision, as in current case, surgery is indicated for removal of tumor and relieving proptosis. Eyeball sparing en bloc excision is preferred over exenteration since it is a less mutilating surgery, and achieves a good cosmetic outcome as well as in to tumor removal.

References

1. Miller NR. Primary tumours of the optic nerve and its sheath. *Eye (Lond)*. 2004 Nov;18(11):1026-37.
2. Saeed P, Rootman J, Nugent RA, White VA, Mackenzie IR, Koornneef L. Optic nerve sheath meningiomas. *Ophthalmology*. 2003 Oct;110(10):2019-30.
3. Dutton J. Optic nerve sheath meningiomas. *Surv Ophthalmol*. 1992 Nov-Dec;37(3):167-83.
4. Mark LE, Kennerdell JS, Maroon JC, et al. Microsurgical removal of a primary intraorbital meningioma. *Am J Ophthalmol* 1978;86:704–9.