

## Retained Intra orbital Foreign Bodies (IOFB)

Syed Mehbub Ul Kadir<sup>1</sup>, Golam Haider<sup>2</sup>

<sup>1</sup>Consultant, Sheikh Fazilatunnesa Mujib Eye Hospital & Training Institute, Bangladesh, <sup>2</sup>Professor & HOD, Dept. of Oculoplasty, National Institute of Ophthalmology & Hospital, Bangladesh

**\*Corresponding Author:**

Email: mehbubkadir@gmail.com

### Abstract

**Purpose:** To assess the pattern of foreign bodies, types of injuries, different types of clinical presentations, radiological appearance, visual status, and management strategies of intra orbital foreign bodies.

**Methodology:** This observational case series study was done in a tertiary eye care centre included all cases with IOFB irrespective of age and sex. CT scan of orbit helped to identify the position, size and pattern of IOFB.

**Results:** We evaluated 27 cases of IOFB including 23 male (85.2%) and 04 female (14.8%) patients. The mean age  $\pm$  SD was  $26.68 \pm 12.55$  years. The types of injuries were accidental (40.7%), political clash (26%), social clash (22.2%) and surgical fault (11.1%). The metallic FB and vegetative FB were found in the same number of cases (12) which was (44.4%), Gauze piece in 2 cases (7.4%) and 1 case (3.7%) was of Retained DCR tube. The mean duration of presentation is 28.16 days. Left orbit was involved in highest cases (80%) in compared to right. The Location of Foreign bodies was in extraconal (44.4%), intraconal (26%) and extraconal to intraconal (29.6%). In 14.8% cases of foreign bodies reached in the apex of the orbit. Surgeries were performed in 25 (92.6%) cases and conservative treatment was given only for 2 cases (7.4%). The intra orbital foreign bodies were removed in 25 (92.5%) cases. The improvement of visual acuity after 6 weeks of treatment was highly significant (P value  $< 0.001$ ).

**Conclusion:** Early diagnosis, surgical exploration and extraction, when indicated, greatly influence visual prognosis & final outcome.

**Keywords:** Computed tomography, Foreign body, Orbit, Vision.

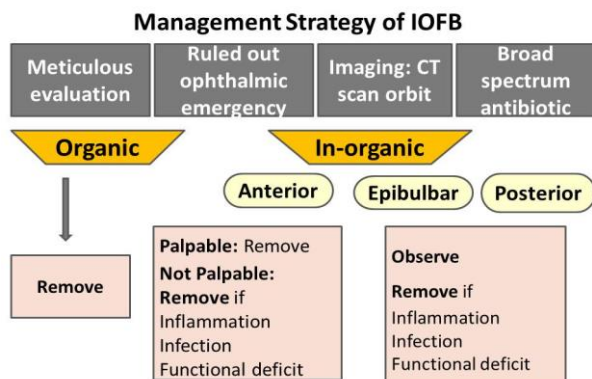
### Introduction

An intra orbital foreign body is an important cause of ocular morbidity usually in the younger age group than in older patients. The term of intra orbital foreign body is foreign body within the orbit but outside the globe.<sup>(1,2)</sup> It usually occurs after a high velocity injury such as a Road traffic accident, fall over objects, physical assault, gunshot injuries, political & social violation but even relatively trivial trauma can cause orbital trauma and foreign body may retained in the orbit. Loss of vision is usually a result of the initial trauma. Orbital foreign bodies are more commonly observed in males than in females.<sup>(2,3)</sup> They can be classified according to their composition into a) metallic inorganic such as steel, pellet, iron, lead b) nonmetallic inorganic such as glass, silicone, plastic & concrete; c) organic such as wood or vegetable matter. In general, metal and glass are well tolerated, and if not causing any symptoms or signs, may be left in situ, while organic matter like wood and vegetable matters are poorly tolerated, elicits an intense inflammatory reaction, abscess, chronic discharging sinus, and need to be removed urgently.<sup>(1,3)</sup> Surgery is planned based on certain aspects that include the nature of the intra orbital foreign body (poorly tolerated organic objects such as wood and vegetable matter, or well tolerated objects such as stone, glass, plastic, iron, steel and aluminum); location of the foreign body (anterior or posterior orbit), and presence of other injuries or foreign body related complications (such as optic nerve

compression, infections, and extra ocular muscle involvement).<sup>(4,5)</sup> We attempt to describe the pattern of foreign bodies, types of injuries, different types of clinical presentations, radiological appearance, visual improvement following management, and management strategies of intra orbital foreign bodies.

### Methodology

An observational case series study was done in department of oculoplasty in National institute of ophthalmology & hospital between 2007 and 2013. Patients with different types of presentations of retained intra orbital foreign body had been treated. Details of ocular history including age, gender, nature of injury and location of intra orbital foreign bodies, imaging studies obtained, preoperative ocular examination, initial and final visual acuity, length of follow up period, treatment modalities, surgical procedure and subsequent management, related adverse reactions and or complications were recorded. We preferred computed tomography scan of the orbit to identify the types and location of intra orbital foreign bodies. Magnetic Resonance Imaging is contraindicated in suspected ferromagnetic foreign body. Conservative treatment including broad spectrum antibiotic were given prior to surgery. Surgeries were planned based on the nature, location of foreign bodies, and presence of other injuries or foreign body-related complications. Appropriate test of significance was done.

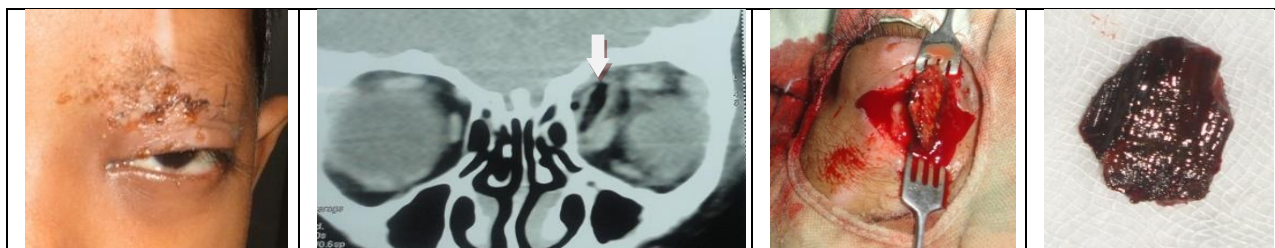

Parameter	No	%
Male	23	85.2
Female	04	14.8
Mean age (yrs) ± SD	26.68 ± 12.55	
Median age (yrs)	25	
Mean Duration (days) ± SD	28.60 ± 7.90	
≤40 yrs	22	81.5
>40 yrs	05	18.5
Mode of IOFB:		
Accidental injury	11	40.7
Political and social injury	13	48.2
Iatrogenic injury	03	11.1
Discharging sinus	10	37.3
Rupture globe	03	11.1
Pattern of IOFB		
Metallic	12	44.4
Wood or Vegetative	12	44.4
Nonmetallic inorganic	03	11.1

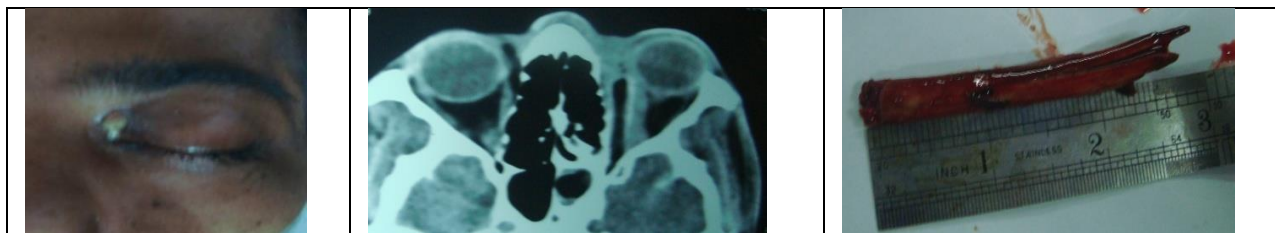
**Results**

We evaluated twenty seven cases involving twenty three male and four female patients ranging in age from one to through fifty nine years. Male patients were twenty three (85.2%) highest in this study than female patients (14.8%). The age of the twenty two cases were below forty years that was 81.5% of all patients. Male patients were usually young but most of the female

patients (75%) were more than forty years of age. The Mean age of all patients was 26.68 years. Orbital foreign bodies were commonly found in pediatric and younger age group. The common cause of intra orbital foreign bodies were accidental injuries like as fall from height, road traffic accident, occupational injury and sport injury. The accidental injury was found in eleven numbers of cases (40.7%). Seven cases (26%) were the result of political unrest. We found six (22.2%) retained foreign bodies in the orbit due to social clash. Three cases (11.1%) were from iatrogenic cause (default surgery). Eighteen cases had done CT scans of the orbit to assess the injury, seven cases had MRI and two patients had plain radiographs. Left orbit was frequently involved that was 80% in compared to involvement of right orbit (16%). Both orbits were involved in one case (4%). The mean duration of presentation to us was 28.16 days. The range of the duration was 1 to 240 days. The median days of duration were fifteen. We assessed associated injuries like as fracture of the orbit (18.5%), Face injury (15%), Head injury (11%) and chest injury (7.4%) along with intra orbital foreign bodies. Common presenting features were chronic discharging sinus (37.3%), entry wound (26%), non healing ulcer/ infection (22.2%), loss of vision (22.2%), proptosis (15%), ptosis (11.1%) and periocular ecchymosed (11.1%). Among the 22 cases with no ocular involvement, only three (11.1%) patients had ruptured globe, two patients had retinal detachment, 3 patients had both retinal hemorrhage and optic neuropathy, and three patients had restricted ocular movement. IOFBs were located in the extraconal space in 40% of cases, 32% were involved both extraconal and intraconal space and 28% cases only involved the intraconal space of the orbit. Surgeries were performed in 92.6% patients of IOFB. Only conservative management was given in only two cases (7.4%) because metallic foreign body (pellet) was in the posterior orbit near to orbital apex. Foreign bodies were extracted from twenty five cases. The surgical approaches were Orbitotomy in twenty one cases (84%), evisceration (8%), enucleation (4%) and exenteration (4%). The metallic foreign bodies and vegetative foreign bodies were found in the same number of cases (12) which was (44.4%).



**Fig. 1-4:** 11 years girl presented chronic discharging sinus, coronal CT image shows hypodensity foreign body in the left orbit, removing the wooden IOFB, extracted wooden foreign body

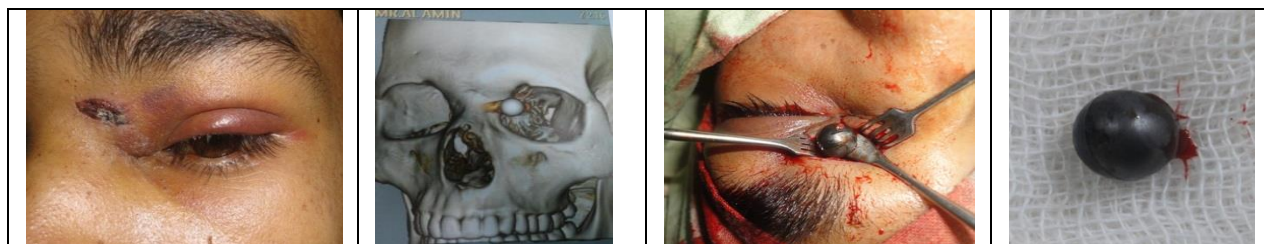


**Fig. 5-7: 34 yrs old male patient presented chronic discharging sinus from medial aspect of left upper eyelid, Axial CT image showing the longitudinal hypodensity IOFB between medial rectus muscle and medial wall of the orbit with surrounding inflammatory change, Extracted wooden foreign body from the left orbit through orbitotomy**

Gauze piece in 2 cases (7.4%) and 1 case (3.7%) was of silicone material (retained DCR tube). Intra orbital foreign bodies were more than single foreign body in 22.2% cases. Initial visual acuity ranged from 20/20 to no light perception. Six patients had no light perception at initial vision of presentation, as did final visual acuity. Improving of vision was statistically very highly significant following management of the patients. Irrigation was done by normal saline mixed with gentamicine solution and 5% povidone iodine solution following extraction of the orbital foreign bodies.

### Discussion

27 cases of intra orbital foreign body involving 12 (44.4%) metallic, 3 (11.1%) nonmetallic inorganic and 12 (44.4%) organic (wood or vegetative material). A retained foreign body can result to devastating complications, the most serious of which is loss of the eye. Mean age of all patients was 26.68 years, median age was 24 years and the age of 81.5% cases were less than 40 years. Assessment through radiological images assists in the proper localization of the foreign body, estimation of its consistency and size, and evaluation of the response of surrounding orbital tissue. Additionally, it is useful in determining the integrity of the globe.



**Fig. 8-11: 19 years old young patient presented an entry wound with swollen and tender left upper eyelid, 3-D X-ray shows radio-opaque rounded IOFB in the supero-medial quadrant of the left orbit, metallic IOFB is extracting from the orbit, removed round, smooth, medium sized pellet**

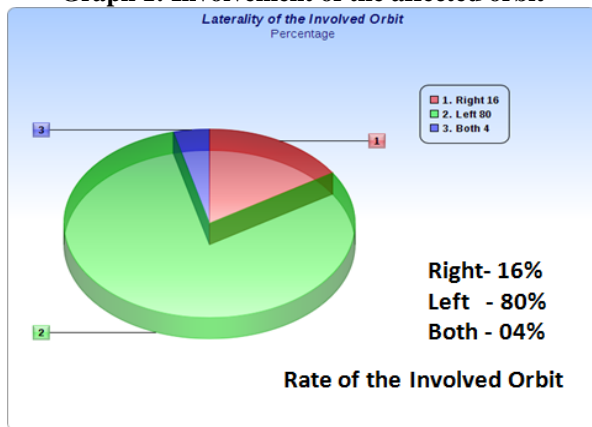
The choice of imaging modality usually depends on the pattern of the suspected foreign body. We ordered CT scans of the orbit in eighteen cases to assess the all types of injury, MRI of the orbit was done in seven cases to clear cut outlined the organic vegetative foreign bodies and only plain radiographs were done in 2 cases due to patient's economic condition. Plain X-ray is useful to localize radiopaque objects. However, plain x-ray is not to sufficient demonstrating the object details, their actual location in relation to surrounding structures and tissue response or damage. CT scan of the orbit is the imaging modality of choice in this situation. Ideally, thin axial and coronal views of 1.0-1.5 mm cuts of the orbit are extremely useful to delineate the shape and for determining the composition of the foreign body. However, despite being highly sensitivity and specific outlined for detection of foreign bodies, CT scans may produce false negative results, particularly if the size of the foreign body is less than

0.5 mm, and especially in the case of wooden objects. In the first few days (acute stage), the density of wooden foreign body is low and may mimic air in attenuation on CT images at window width of 200-250 HU and window level of 15 to 30 HU for orbit. But at 1000 HU window width and window level of -500 HU may used to distinguish wooden or vegetative foreign body from air. After few weeks or months, the density of wooden foreign bodies becomes higher than that of orbital fat. It appears as homogeneous mass surrounding the dense wooden foreign body due to inflammation and edema. Magnetic resonance imaging (MRI) does have utility in detecting organic foreign body in the orbit that are often missed on CT scan or in the evaluation of optic nerve injuries. MRI is not recommended as part of the initial evaluation of intra-orbital foreign bodies.<sup>(3,7,8)</sup>

**Table 2: Status of visual condition at initial presentation and 6 weeks after conservative and / or surgical management**

Visual Status	At presentation	6wks of Rx	X <sup>2</sup> test df p-value
6/6 to 6/12	07	14	
6/18 to 6/36	09	06	19.667
6/60 to 1/60	05	01	3
NPL	06	06	<0.001***

**Graph 1: Involvement of the affected orbit**



However, an MRI is contraindicated if the suspected foreign body is ferromagnetic metallic foreign bodies can remain entrapped in the orbit. MRI can cause blindness if performed prior to ruling out the presence of metallic foreign body in the orbit. Vegetative or wooden foreign body with its porous consistency and organic nature provides a good culture medium for microbial agents and lead to complications like orbital cellulites, abscess formation, chronic discharging sinus, noninfectious inflammation, and fibrosis. They can migrate intra cranially leading to chronic brain abscess or undergo spontaneous extrusion.<sup>(9,10)</sup> We were tried to find out the cause of the intra orbital foreign bodies. Political & social unrest was significant for orbital trauma. Accidental injury was 40.7%, injury due to Political clash was 26%, social injury was 22.2%, and iatrogenic cause found in 11.1% cases. The iatrogenic cause was default surgery, two cases were gauze piece in the orbit with history of previous DCR surgery in one case and Orbitotomy for lacrimal gland tumor in one case. Another one case had metallic DCR tube introducer. Meticulous surgery should be done at every case that will be reduced the rate IOFBs. Twenty one cases had stable or improved vision following management. Visual improvement was statistically significant. Six patients had no light perception at initial vision of presentation. 93% of IOFBs were extracted from the orbit. Foreign bodies removed from the orbit in twenty five cases and we managed conservatively only in two cases who had pellet (metallic IOFB) with history of gunshot injuries in posterior orbit near to orbital apex.

Fulcher et al. studied on forty retrospective consecutive case series conducted over ten years, foreign body composition were classified as metallic, organic (wood) and non-metallic inorganic (glass, plastic, fiberglass, concrete). Most common associated ocular morbidities was perforating eye injury, occurring in 25% (10 of 40) of patients. Others included infection (orbital cellulites, orbital abscess, and cerebral abscess), ophthalmoplegia, ptosis, optic neuropathy and orbital fracture. 85% (34 of 40) of patients underwent surgical removal. All 6 cases that did not had posterior located IOFBs. In reviewing the surgical indications, the most important factors were foreign body location and composition.<sup>(2)</sup>

Finkelstein et al. reviewed 27 consecutive patients over 7 years. All cases involved metallic foreign bodies, the majority of which were BB gun injuries (20 of 27). 13 of the foreign bodies were located in the anterior orbit, 4 epibulbar and 10 posterior. Practically all (94%, 16 of 17) anterior and epibulbar foreign bodies were surgically removed, whereas only 20% (2 of 10) of those located posterior were extricated (which occurred during ruptured globe repair). Most common associated ocular morbidities included local trauma (subconjunctival hemorrhage, corneal abrasion, chemosis), ophthalmoplegia, retinal or vitreous hemorrhage, traumatic optic neuropathy, orbital fracture, retinal detachment, retinal tear and choroidal rupture. Final visual acuity correlated to location of foreign body. 85% (11 of 13) of patients with anterior IOFBs retained final visual acuity greater than 20/40, compared to only 30% (3 of 10) of patients with posterior IOFBs. Additionally, of the 3 patients who developed NLP vision, all had posterior IOFBs. It was deemed that management of each case was dependent on location of the projectile, and foreign bodies not readily surgically accessible may be left safely in place.<sup>(3)</sup>

If inflammatory signs persist and limited of ocular movement after a patient presented with a history of an ocular injury caused by organic material such as wood, the possibility of a retained orbital foreign body must be considered.<sup>(11)</sup>

Peralt R.J et al presented a case report a 20 year old male presented to one day after a high velocity projectile injury (BB pellet) to the right orbit. Clinical examination revealed an entrance wound 10 mm inferior to the right medial canthus but no exit wound, mild pain and limitation of extra ocular movements, mild relative afferent pupillary defect (APD) and complete loss of color vision on Ishihara testing in right eye.<sup>(6)</sup> CT scan showed a metallic foreign body deep in the posterior orbit near the orbital apex and right optic nerve. They managed the case with an inert, well tolerated metallic foreign body located deep in the posterior orbit conservatively with observation and appropriate supportive care, thus avoiding potential

iatrogenic injury to vital structures adjacent to the orbital apex.<sup>(12,13)</sup>

## Conclusion

Management of intra orbital foreign bodies should include an accurate and detailed history as well as a CT scan of the orbit, which is the best initial mode of imaging. Early diagnosis, management and extraction of the foreign body if indicated, greatly influence the final outcome. All patients should have antibiotic therapy because of the high incidence of secondary orbital infections. Surgical removal is indicated for all organic IOFBs. Posterior located inorganic inert IOFBs should be left alone, unless they are causing significant orbital complication.

## References

1. Fulcher TP, McNab AA, Sullivan TJ. Clinical features and management of intra orbital foreign bodies. *Ophthalmology*. 2002;109:494-500.
2. Al-Mujaini A, Al-Senawi R, Ganesh A, Al-Zuhaibi S, Al-Dhuhli H. Intraorbital Foreign Body: Clinical Presentation, Radiological Appearance and Management. *Sultan Qaboos university medical journal*, 2008, 8:1,69-74.
3. Finkelstein M, Legmann A, Rubin PAD. Projectile metallic foreign bodies in the orbit. *Ophthalmology*. 1997;104:96-103.
4. Ho V, Wilson MW, Fleming JC, Haik BG. Retained intraorbital metallic foreign bodies. *Ophthal Plast Reconstr Surg*. 2004;20:232-6.
5. Van Thong Ho, James F, Mc Guckin Jr, Smerge IEM. Intra orbital wooden foreign body: CT and MR Appearance. *Am J Neuro Surg*. 1996;17:134-136.
6. Peralta R.J, Zoumalan C, Lelli Jr G.J. Posterior Intraorbital Foreign Body: Take it or Leave it? *Open Reconstructive and Cosmetic Surgery*. 2008;1:1-3 1.
7. Lo Bue TD, Deutsch TA, Lobick J, Turner DA. Detection and localization of nonmetallic intraocular foreign bodies by magnetic resonance imaging. *Arch Ophthalmol*. 1988;106:260-261.
8. Wilson WB, Dreisbach JN, Lattin DE, Stears JC. Magnetic resonance imaging of nonmetallic orbital foreign bodies. *Am J Ophthalmol*. 1988;105:612-617.
9. Nasr AM, Haik BG, Fleming JC, Al-Hussain HM, Karcioğlu ZA. Penetrating orbital injury with organic foreign body. *Ophthalmology*. 1999;106:523-532.
10. Shinder R, Gutman J, Gunasekera CD, Connor M, Nakra T. Occult orbital organic foreign body. *Ophthal Plast Reconstr Surg*. 2011;27:463-4.
11. Macrae J.A. Diagnosis and management of a wooden orbital foreign body: case report. *BJO*. 1979;63:848-851.
12. Michon J, Liu D. Intraorbital foreign bodies. *Semin Ophthalmol*. 1994;9:193-9.
13. Panda B.B, Kim U.R. Complications of retained intra orbital wooden foreign body. *Oman Journal of Ophthalmology*. 2014;7(1):38-39.