

Apocrine adenocarcinoma arising in the Gland of Moll – a brief clinico-pathological case report

Debanshu Bhattacharya¹, Saptagirish Rambhatla^{2,*}, Jayaram Iyengar³, Samrat Bordoloi⁴

¹Fellow, ²Dean & HOD, Dept. of Orbit & Oculoplasty, Sankara Eye Hospital, ³Director, ⁴Consultant, Anand Diagnostic Laboratory, Bangalore

***Corresponding Author:**

Email: saptagirishr@sankaraeye.com

Abstract

A 85 year old lady came with a recurrent eyelid swelling since last 5 years with a previous history of surgery at the same site. The present swelling was excised and sent for histopathological examination. Apocrine adenocarcinoma arising in the Glands of Moll was diagnosed after histopathological examination.

Materials and Methods: Routine histochemical stains and light microscopy were used for diagnosis. As the morphology was evident on light microscopy, immunohistochemistry was not required.

Conclusion: Malignant tumours arising in the Glands of Moll are a rare occurrence and their early clinical and histopathological diagnosis is of utmost importance for a favorable outcome.

Keywords: Apocrine adenocarcinoma, Glands of Moll, Eyelid tumor

Introduction

Tumours originating in sweat glands are rare.^(1,2) In the eyelids they may arise from eccrine or apocrine glands. Moll's glands are apocrine sweat glands at the lid margin from which both benign and malignant tumours may occur.^(1,2) Although cysts of Moll's glands are common, true neoplasms are rare.⁽¹⁾ The Moll's glands open into follicles of the cilia, the duct of the Zeis glands, or directly on to the lid margin. They differ from eccrine sweat glands in that they are larger, contain eosinophilic cytoplasm, and show decapitation secretion of apical cytoplasmic processes.

Apocrine adenocarcinomas originating from ocular region are generally considered to pursue a relatively indolent course, but few cases showing aggressive biological behaviour have been reported.

Case History

An 85 year old lady presented with a history of recurrent swelling in the lower lid of left eye since 5 years. She underwent cyst excision 5 years ago following which the swelling completely resolved. She had a recurrence of the swelling 3 years ago when she was diagnosed as having a tarsal cyst and an excision biopsy revealed a benign lesion (details are not available).

On presentation she gave a history of recurrence of the lid swelling since the past couple of months that has been gradually increasing in size. There was no associated pain or redness. The lesion was involving the left lower lid margin (Fig. 1). It measured 5 mm across and was involving the full thickness of the lid margin. It was a pale bluish coloured firm mass with a cystic component medially. There was an associated loss of lashes. The conjunctiva showed mild congestion. There was no evidence of conjunctival

spread clinically. There was no palpable regional lymphadenopathy. With a clinical suspicion of a lid malignancy she underwent wide excision of the lesion followed by lid reconstruction. The specimen was sent for histopathological analysis.

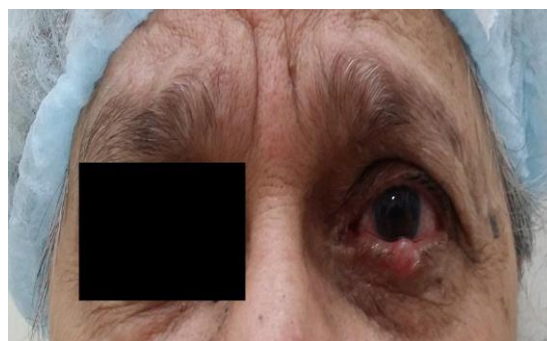

Fig. 1: Nodular swelling present in the margin of the lower lid measuring about 5 mm in diameter. The surface is smooth and there is loss of eyelashes

Grossly a skin covered tissue was received measuring 0.8X0.8X0.5 cm. Histopathological examination revealed a tissue fragment lined by stratified squamous epithelium with underlying cystic tumour composed of closely packed papillary structures with fibrovascular cores (Fig. 2). These papillae were lined by cells having round to oval pleomorphic nuclei, prominent nucleoli and eosinophilic cytoplasm. Many of the tumour cells showed apocrine differentiation in the form of apical snouts (Fig. 3). Based on the histomorphology a diagnosis of papillary apocrine adenocarcinoma was given.

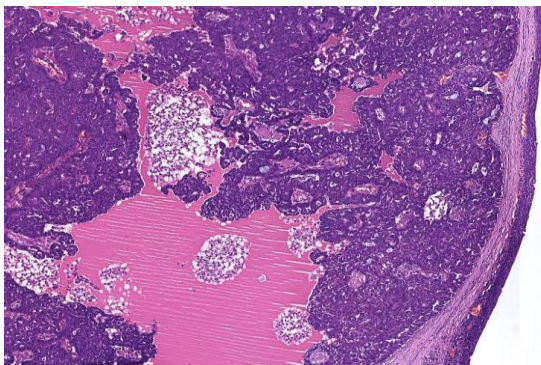


Fig. 2: Tissue lined by stratified squamous epithelium with a solid and cystic tumour in the subepithelium. The tumour is composed of cells arranged in papillary architecture and acinar pattern. (40X)

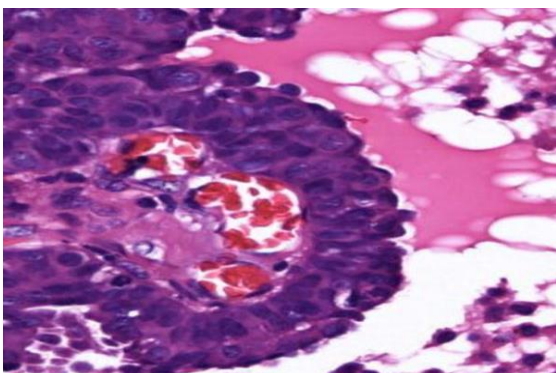


Fig. 3: The cells lining the papillae are cuboidal to columnar with hyperchromatic nuclei and eosinophilic cytoplasm. Many of these cells show apical snouts suggestive of an apocrine origin. (400X)

On follow up the patient was doing well and was clinically healthy.

Discussion

This case describes an apocrine adenocarcinoma most probably originating from the glands of moll at the lid margin. Aurora and Luxenberg⁽³⁾ postulated three criterias to designate a tumor of ocular adnexa to be of apocrine origin. According to them, firstly, the tumor should be located at the lid margin. Secondly, histologically the cells should be seen to have an eosinophilic cytoplasm with apocrine decapitation areas. Thirdly, presence of iron positive intracellular granules in one-third of the tumours. Very few cases of adenocarcinoma arising from the gland of Moll have been reported in literature.⁽³⁻⁹⁾ In a series by Stout and Cooley,⁽¹⁰⁾ of 11 sweat gland carcinomas, 3 were accepted as belonging to gland of Moll. Whorton and

Patterson⁽¹¹⁾ have reported one case of Moll's gland carcinoma.

Chuo Ni, Michael Wagoner et al⁽¹²⁾ reported four cases of tumors arising from Moll's glands – two benign mixed cell tumors of the skin and two adenocarcinomas. They found that contrary to the common assumption of moll's gland tumors as being low grade malignant tumors, the adenocarcinomas described were highly malignant. Despite vigorous treatment including orbital exenteration and lymph node resection, one was rapidly fatal within one year due to intracranial extension, and the other recurred with extensive involvement of the paranasal sinuses.

Anne C. Hunold, Martina C. Herwig, Frank G. Holz et al⁽¹³⁾ reported a case of a pigmented nodular lesion present on the left lower lid, which was confirmed to be apocrine adenocarcinoma, most probably originating from the glands of Moll. Differential diagnoses to be considered are mainly simple apocrine hidrocystoma, apocrine cystadenoma, and metastatic lesions.

References

1. Duke-Elder S, MacFaul P. System of Ophthalmology. London, Kimpton 1974;13:458-73.
2. Gates O, Warren S, Warvi WN. Tumors of sweat glands. Am J Pathol. 1943 Jul;19(4):591-631.
3. Aurora AL, Luxenberg MN. Case report of adenocarcinoma of glands of moll. Am J Ophthalmol. 1970 Dec;70(6):984-90.
4. Weizenblatt S. Basal-cell carcinoma of cyst of Moll: report of a case. Am J Ophthalmol. 1957;43:968-710.
5. Coats G. Three tumours arising in sweat glands. R Loidon Ophthalmic Hosp Rep. 1912;18:266-79.
6. Zeeman, W.P.C. Hydatis and carcinoma of a cyst of Moll. Nederl. Tijdschr. Geneesk. 1923;67:1194-8.
7. Seregard S. Apocrine adenocarcinoma arising in Moll gland cystadenoma. Ophthalmology. 1993 Nov;100(11):1716-9.
8. Barker-Griffith AE, Streeten BW, Charles NC. Moll gland neoplasms of the eyelid: a clinical and pathological spectrum in 5 cases. Arch Ophthalmol. 2006;124(11):1645.
9. Futrell J, Krueger G, Chretien P, Ketcham A. Multiple primary sweat gland carcinomas. Cancer 1971;28(3):686-91.
10. Stout A, Cooley S. Carcinoma of sweat glands. Cancer 1951;4(3):52 1-36.
11. Whorton CM, Patterson JB. Carcinoma of Moll's glands with extramammary Paget's disease of the eyelid. Cancer 1955;8(5):1009-1015.
12. Ni C, Wagoner M, Kieval S, Albert D. Tumors of the Moll's glands. British Journal of Ophthalmology. 1984;68(7):502-506.
13. Hunold A, Herwig M, Holz F, Fischer H, Loeffler K. Pigmented Tumour of the Eyelid with Unexpected Findings. Case Reports in Pathology. 2012;2012:1-3.