

LPS recession in permanent 7th nerve palsy to protect cornea

Mohammed Ather^{1,*}, Kesava Rao², MR Florence³, T. Sai Shreya⁴, Raheel Raza⁵

¹Professor, ²Assistant Professor, ^{3,4}Junior Resident, Dept. of Ophthalmology, ⁵Junior Resident, Dept. of Pathology, Sarojini Devi Eye Hospital, Gandhi Medical College

***Corresponding Author:**

Email: ather11258@gmail.com

Abstract

Aim: To study the effect of LPS recession in permanent 7th nerve palsy to protect cornea.

Materials & Methods: This is a Prospective interventional study conducted at the Department of Oculoplasty and Orbital diseases of Sarojini Devi Eye Hospital which is attached to Gandhi Medical College between 2012-2014. 36 eyes of 33 patients who had lagophthalmos due to permanent type of 7th nerve palsy were included in the study. Patients who had temporary type of facial palsy like Bell's palsy and those patient with permanent palsy having paralytic ectropion and patients who already underwent any procedure to correct lagophthalmos were excluded from the study. All patients were clinically examined to establish the cause of lagophthalmos. MRD1, amount of Lagophthalmos was measured and exposure keratopathy was documented by staining cornea with Flourescien sodium. Surgical profile was done in all patients. LPS recession was done under local anaesthesia. Patients were followed up on 1st day, 1st week, 2nd week and 4th week after LPS recession. On every visit MRD1, amount of lagophthalmos was measured and corneal staining was done to see the healing effect.

Results: There was mean reduction of 3.89 mm in MRD1 and 5.47 mm in the amount of lagophthalmos in all cases after 1st week. At the end of 2nd week all cases started showing healing of cornea. By the end of 4th week 28 cases showed total healing of exposure keratopathy. Only 8 cases showed non-healing of cornea after 4th week. These cases had neurotrophic keratopathy because of Hansens.

Discussion: LPS recession achieve results similar to Gold weight implant. It is cheap and can be used as an alternative to gold weight implant.

Keywords: 7th Nerve palsy, MRD1 (Mean reflex distance), LPS (Levator palpebral superioris), Exposure keratopathy, Lagophthalmos.

Introduction

Lower motor type of 7th Nerve palsy is caused by any lesion in the pathway of nerve. 8th nerve Schwannoma at Cerebello- pontine angle compresses 7th nerve and causes lagophthalmos.⁽¹⁾ Iatrogenically while operating CP angle tumour Neuro surgeon can injure 7th nerve or has to sacrifice it for removing tumor completely.⁽²⁾ 7th Nerve while passing through petrous temporal bone is liable to get injured in Temporal bone fracture, CSOM, and Iatrogenically while performing Mastoidectomy ENT surgeon can injure it.⁽³⁾ While exiting the skull through Stylo-mastoid Foramen it is liable to get injured in road traffic accident by Fracture of Stylo-mastoid foramen.⁽⁴⁾ In Bell's Palsy edematous 7th nerve get compressed within stylo-mastoid foramen and causes lagophthalmos.⁽⁵⁾ In Parotid gland 7th nerve can get effected by Pleomorphic Adenocarcinoma of gland.⁽⁶⁾ Iatrogenically also surgeon has to sacrifice 7th nerve to completely remove the tumor.⁽⁷⁾

Surgical treatment for lagophthalmos include various operations like Tarsorrhaphy, Encirclement, Gold weight implant in upper lid, LPS recession, Medial and lateral canthoplasty.⁽⁸⁾

Aim

To study the effect of LPS recession in permanent 7th nerve palsy to protect cornea.

Materials and Methods

This is a Prospective interventional study conducted at the Department of Oculoplasty and Orbital diseases of Sarojini Devi Eye Hospital which is attached to Gandhi Medical College between 2012-2014. 36 eyes of 33 patients who had lagophthalmos due to permanent type of 7th nerve palsy were included in the study. Patients who had temporary type of facial palsy like Bell's palsy and those patient with permanent palsy having paralytic ectropion and patients who already underwent any procedure to correct lagophthalmos were excluded from the study. All patients were clinically examined by an Ophthalmologist to establish the diagnosis of permanent 7th Nerve palsy. Detail clinical examination was done, including CNS examination, ENT exam. Informed consent was taken by all cases included in the study.

Preoperative measurement of palpebral fissure height, marginal reflex distance 1, marginal reflex distance 2, amount of lagophthalmos taken and fluorescein staining of cornea done to see exposure keratitis.

After surgical profile investigations like CT, BT, CBP, RBS, CUE, CT scan brain in cases of trauma and intracranial space occupying lesion, nasal swab in cases of Hansen's disease was done. HIV test and HBS Ag test was done in all cases. The cases are then posted for surgery.

After cleaning the eyelids with Povidone Iodine lotion, patient was draped. Lid crease incision was marked and injection Lignocaine and adrenalin was injected sub cutaneously. Incision was given by 15 no. Bard Parker blade. Layers of the lid dissected by using Radio frequency cautery. LPS identified by pre aponeurotic pad of fat. Orbicularis fibres were separated from tarsal plate. 0.5 ml of normal saline was injected at mid tarsal level to delineate the insertion of LPS in the tarsal plate. Then LPS was disinserted from tarsal plate and turned on itself. Then it is sutured to itself away from the tarsal plate using 5/0 ethibond non absorbable suture. The skin and Orbicularis oculi was sutured by 6/0 Poly galactin sutures. Bite from LPS was taken to reform the lid crease.

The patient was followed up on 1st PO day, 1st week, 2nd week, 4th week after LPS recession. At every visit Palpebral fissure height, MRD1 and Amount of Lagophthalmos were recorded.

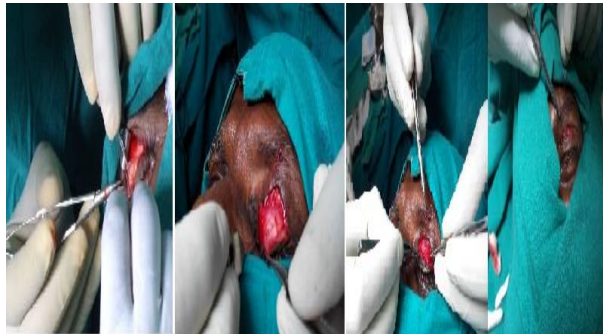

Fig. 1-4: Shows steps of LPS disinsertion and suturing it on itself

Results

Age distribution curve: 36 eyes of 33 patients were included in the study. Permanent facial palsy with Lagophthalmos was noted between age groups of 0-20 years 0%. 21-40 years 24%, 41-60 years 42%, 61-80 33%. The median age of presentation was 55 years.

Out of 36 eyes of 33 patients, 36 eyes underwent only LPS recession. The mean palpebral fissure height was 11.72[+/- SD 0.24] before surgery was reduced to 7.83[+/- SD0.22] after the surgery.

The mean difference in the palpebral height was 3.89 which was statistically significant. P < 0.0001. The mean percentage reduction in palpebral height was 33%.

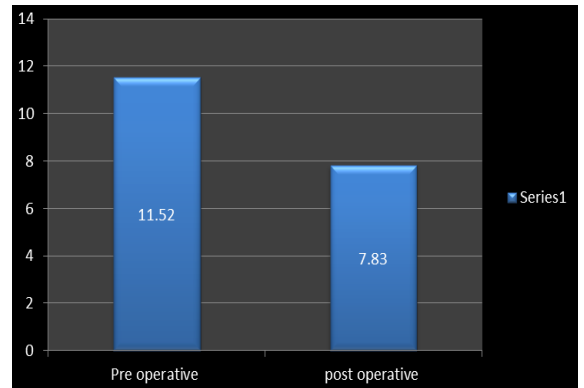


Fig. 5: Comparison between pre & post operative mean Palpebral fissure height

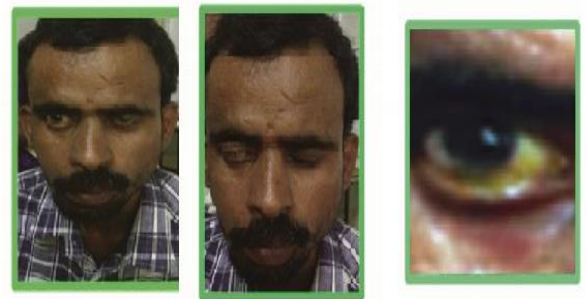

Fig. 6, 7, 8: Showing Pre op. Lagophthalmos & Corneal staining for Exposure keratopathy

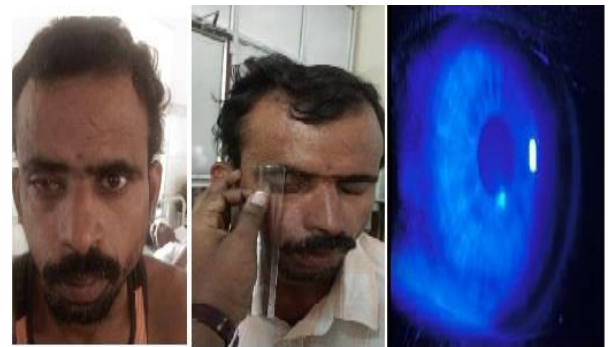

Fig. 9, 10, 11: Showing Post op pictures with reduced PFH & Lagophthalmos & Negative Corneal staining

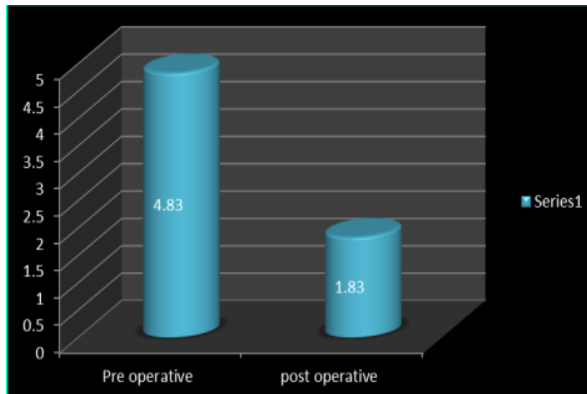


Fig. 12: Comparison between pre-operative and post-operative mean MRD1

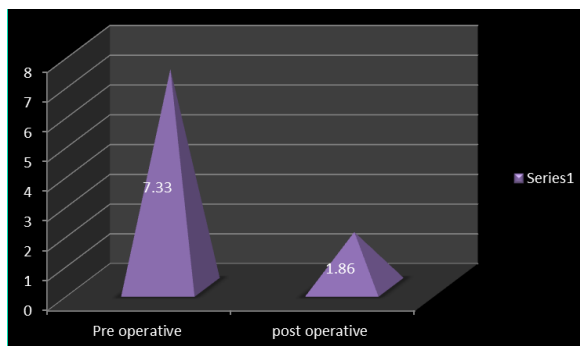


Fig. 13: Comparison between pre-operative and post-operative mean lagophthalmos

The mean amount of lagophthalmos before the surgery was 7.33[+/-SD2.27]and was reduced to 1.86[+/-1.14SD] at the end of 1week which is statistically significant with P value < 0.0001.

The mean difference in lagophthalmos was 5.47 which was statistically significant $p < 0.0001$. Out of 36 eyes of 33 patients all the cases achieved the reduction of mean palpebral fissure height was 3.89 and lagophthalmos was 5.47 at the end of 1st week.

At the end of 2nd week all the cases started improving in the exposure keratopathy and by the end of 4 weeks 28 eyes out of 36 eyes showed improvement in the exposure keratopathy with the fluorescein staining negative.

Only 8 eyes out of 36 eyes showed persistent exposure keratopathy without any healing.

The cases in which exposure keratopathy do not improve are leprosy cases who will have neurotropic keratitis with reduction in corneal sensation.

Whereas lagophthalmos cases due to traumatic, infective, iatrogenic facial palsy showed improvement in the exposure keratopathy.

Discussion

Main aim in the treatment of Lagophthalmos is protection of cornea & prevention of exposure keratopathy. Paralysis of Orbicularis oculi will effect

both upper lid and lower lid. The unopposed action of LPS will lead to retraction of upper eyelid.

As time progresses the lower eyelid will become lax and may develop paralytic ectropion. The combine effect will lead to lower scleral show. This progression in the course of facial nerve palsy is best graded by House and Brackman grading scale.

House & Brackman grading for facial palsy⁽⁹⁾

Grade 1 Normal function

Grade 2 Mild dysfunction

Grade 3 Reduced forehead movement, noticeable synkinesis and contracture

Grade 4 No forehead movement, incomplete eye closure, asymmetric mouth, disfiguring asymmetry

Grade 5 Minimal movement

Grade 6 No movement

In grade 1-3 no surgical intervention is required. In grade IV upper eyelid surgery will correct the Lagophthalmos. Preferred surgeries are:

1. Gold weight implant over tarsal plate in the upper eyelid.
2. Recession of LPS to bring down the upper eyelid.
3. Lateral & Medial tarsorrhaphy.

The gold weight implant is considered as Gold standard in western countries but it will lead to exposure of implant & extrusion in 30% of cases even though branded and patented gold is used. In our country cost will be major hurdle for usage of gold implant and non availability of branded & patented gold weight implant adds to the problem. This will increase the extrusion rate upto 50% as we are forced to use Gold implant made by local goldsmith which will not be pure gold.

Weakening procedures of LPS are recession of LPS using spacers like Cartilage of pinna, Muco-perichondrium of Hard palate or Tarso-conjunctiva from contralateral upper eyelid. This will also cause ptosis by bringing down the upper eyelid and reduces the Lagophthalmos thereby protecting cornea and preventing exposure keratopathy.

The lateral Tarsorrhaphy will reduce the palpebral aperture width and protect cornea. The disadvantage of this procedure are: loss of temporal field, Cosmetic disfigurement and in some cases medial exposure will not be corrected. In these cases where medial exposure of cornea has to be corrected by adding Medial tarsorrhaphy.

LPS disinsertion at tarsal plate and turning it upon itself and suturing it by 5'0 ethibond will weaken the LPS and cause minimal ptosis. As LPS has six insertions, the elevation of lid and pupillary clearance is still maintained. This not only protects the cornea and prevent exposure keratopathy but also gives patient a functioning eye. In this study 36 eyes of 33 patients were treated by surgery to reduce palpebral aperture width in primary gaze, reduction in Lagophthalmos on

attempted closure. and protection of cornea to prevent exposure keratopathy. All 36 eyes underwent LPS disinsertion and suturing on itself to bring down the upper eyelids to reduce PFH and reduction in lagophthalmos.

In all 36 eyes mean reduction in PFH is 3.89mm which is statistically significant (P value <0.0001).

The mean difference in pre and post operative MRD1 is 3.0mm (P value<0.001).

As we are cutting the insertion of LPS at tarsal plate, we are not disturbing its insertion at medial and lateral horns and fornix of conjunctiva. Elevation of lid is not disturbed and MRD-1 of ≥ 1 mm is maintained in all cases.

The mean reduction in pre and post operative lagophthalmos is 5.47mm (p value <0.0001).

28 eyes out of 36 eyes showed improvement in the exposure keratopathy with the fluorescein staining negative.

Only 8 eyes out of 36 eyes showed persistent exposure keratopathy without any healing.

The results of our study are comparable to study done by B. Leather Barrow and JRO Collin.⁽¹⁰⁾ The study conducted at Royal Eye Hospital, Moorfields eye hospital, London.

They used multiple procedures for correction of lagophthalmos. Lower lid ectropion, lower lid laxity in 65 patients with established permanent facial palsy.

The mean age of patients was 63 years.

The study carried over a period of 8 years and mean period of post operative follow up was 1 year.

LPS recession was performed on 21 of 46 patients suffering from lagophthalmos with exposure keratopathy. Lateral tarsal strip was performed in 16 patients suffering from lagophthalmos with lower lid ectropion.

Post operatively 70% showed resolved corneal staining, 15% improved corneal staining and 15% unchanged corneal staining.

They found LPS recession to be good and cheap procedure to correct lagophthalmos.

Other procedures performed by them is medial canthoplasty, lateral tarsorrhaphy for exposure keratopathy.

In cases with lower lid ectropion the procedure done by them are medial canthal resection, lazy T procedure, lower lid inverting sutures, skin graft / flap to the lower lid.

The other procedures done are free ipsilateral facial nerve grafting, hypoglossal nerve cross over, regional muscle transfer.

These procedures produced excellent results but are time consuming, require general anaesthesia and hospitalization. The second study conducted at Queen's Medical centre UK by Sadiq et al⁽¹¹⁾ used multiple procedures for correction of lagophthalmos in which one procedure was LPS recession. They performed this on 16 patients out of 64 and found to be good and cheap procedure to correct lagophthalmos. The other procedures performed by them were Gold weight implant, Lateral tarsorrhaphy, Medial canthoplasty, Lateral canthal sling.

Gold weight implant was done in 10 patients out of 64. Five patient had to undergo explantation due to exposure and extrusion of implant. This accounts for 50% extrusion of gold weight implant.

Conclusion

LPS disinsertion at tarsal plate partly weaken the LPS and causes Ptosis enough to reduce PFH and Lagophthalmos. This is sufficient to protect cornea from exposure keratopathy and also gives patient a functioning eye by reducing mean MRD1 to 1.83 mm after surgery. It can be concluded that LPS recession is cost effective method to protect cornea and prevent exposure keratopathy in the cases of facial nerve palsy during early period of palsy. However it has to be combined with LTS with or without spacer to correct lower eyelid laxity and ectropion which patient will develop over a period of time.

References

1. Logan Turner, Diseases of Nose Throat and Ear, 11th edition, 2016, 474 page.
2. Neurology and Neurochirology Pol. Journal 2011 Sep-Oct;45(5):480-8.
3. Logan Turner, Diseases of Nose, Throat and Ear, 11th edition 2016, 425 & 502-503 pages.
4. May M. Trauma to the facial nerve. *Otolaryngol Clin North Am.* 1983 Aug. 16(3):661-70.
5. Rahman, Sadiq SA ophthalmic management of facial nerve palsy a review, *Surv ophthalmol* 2007;52[2]:121-44.
6. Jecker P, Hartwein J: [Facial paralysis in parotid tumour: Case report and review of literature]. *Laryngo rhinotologic* 72;204-6, 1993.
7. Bailey and Love: Short practice of surgery, 26th Edition 2013, 733-734.
8. Lee. V. Currie, Collin. JR ophthalmic management of facial nerve palsy *Eye [lond]* 2004;18[12]:1225-34.
9. House JW, Brackmann, DE: Facial nerve grading system. *Otolaryngol Head Neck, Surg.* 93:146-7;1985.
10. B Leather Barrow⁴ and JRO Collin, eye lid surgery, in facial palsy. *Eye* (1991)5,585, 590.
11. S.A. Sadiq, R.N. Downes A Clinical algorithm for the management of facial nerve palsy from an oculoplasty perspective, *Eye* (1998)12, 219-223.