

## Hemolacria: A rare presentation of Munchausen Syndrome

Aparajita Chaudhary<sup>1\*</sup>, Mimansa Agasti<sup>2</sup>

<sup>1</sup>Associate Professor, <sup>2</sup>Junior Resident, Dept. of Ophthalmology, MLN Medical College, Allahabad, Uttar Pradesh

**\*Corresponding Author:**

Email: dr.aparajita.ald@gmail.com

### Abstract

Munchausen syndrome is a factitious disorder, a mental disorder in which a person repeatedly and deliberately acts as if he or she has a physical or mental illness when he or she is not really sick. Munchausen syndrome is considered a mental illness because it is associated with severe emotional difficulties. Hemolacria or “bloody tears” is a rare presentation of Munchausen Syndrome.

A 10 years old female child presented in OPD of ophthalmology department of MLN Medical college with the complain of bleeding from right eye of sudden onset. A complete physical, ocular, otolaryngological, dermatological and parasitological, haematological examination failed to reveal any clue towards a particular diagnosis. Hence a diagnosis of Munchausen syndrome was made by exclusion of other abnormalities.

**Keywords:** Hemolacria, Factitious disorder, Munchausen syndrome

### Introduction


Munchausen syndrome is a factitious disorder, a mental disorder in which a person repeatedly and deliberately acts as if he or she has a physical or mental illness when he or she is not really sick. Munchausen syndrome is considered a mental illness because it is associated with severe emotional difficulties.

It should be considered in the differential diagnosis of many disorders. The patient presents with a history of recurrent hospitalization along with an inconsistent but dramatic medical history. It named after the fictional character Baron von Munchausen, an 18th century German officer who was known for embellishing the stories of his life with dramatic, extremely improbable tales of his past experiences, it is the most severe type of factitious disorder. Haemolacria one of the rare presentation of Munchausen syndrome

Haemolacria is a physical condition that causes a person to produce tears that are partially composed of blood. It is a symptom of a number of diseases. It can be caused by diseases of the conjunctiva, eyelids and nasolacrimal system or trauma. Epistaxis with retrograde flow, vascular malformations, inherited bleeding disorders, acquired systemic coagulopathies, vicarious menstruation, drugs, hyperthyroidism, nasolacrimal tuberculosis, hysteria/stigmatization and malingering have also been implicated. Haemolacria can also be idiopathic. Hemolacria as a presentation for Munchausen syndrome should be considered as a diagnosis by exclusion when all the above causes are ruled out. It should be thought of when a patient presents with symptoms “difficult to explain” making it a diagnostic difficulty. Our patient presented with such interesting and improbable findings which makes this case worth mentioning.

### Case Report

A 10 years old female child presented to our OPD in ophthalmology department of MLN medical college with complaints of bloody discharge from right eye in evening, when patient was alone in dark room since 2 weeks. The bleeding was sudden in onset, bright red in colour, severe in intensity, not associated with pain or diminution of vision. The patient underwent cataract surgery in both the eyes, 8 years back as she was suffered with congenital cataract. She was pseudophakia with thick posterior capsule opacification in both the eyes. Such symptoms were mostly seen when she was alone, in the evening, and in the absence of any family member.



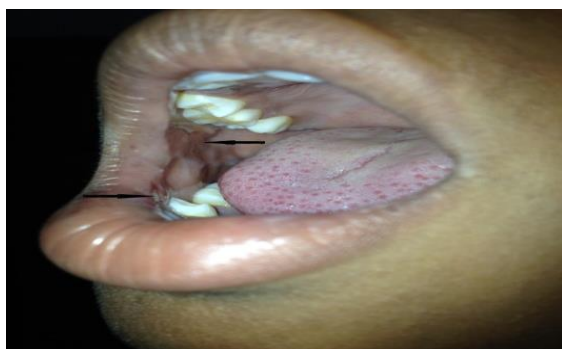**Fig 1: The patient with pseudophakia both eye with thick PCO formation, and no signs of any bleeding, abnormality or trauma near the eye**

A complete physical, ocular, otolaryngological and dermatological, haematological, radiological examination was done. The all above examination was normal otherwise for blood pouring of the right side. She was a normal, average built girl with streaks of blood from the fornices. General examination was

normal; with no signs of anaemia, dilated vessels, or bleeding from other sites, including the nose, gums, or skin; and no hepatosplenomegaly or lymphadenopathy. Ophthalmic examination was also normal, with no evidence of conjunctival injury or obvious site of bleeding near the eye. On examination, eyes were orthophoric with full extra ocular motility. The vision was Finger Count in the right eye where as it was 6/60 in the left eye due to thick PCO. Best Corrected Visual Acuity remained the same with no further acceptance. As patient was suffered with amblyopia. Her investigations, including full blood count, prothrombin time, partial thromboplastin time, and bleeding time were normal, too and failed to reveal any possible cause. The patient was kept on regular follow up every 3 days and was asked to present whenever “bleeding” occurred.

The patient presented to us after 4 days with her “emotionally distraught” father who said that bleeding had occurred from her right eye the previous evening when she was alone. He saw her cheeks streaked with tears linearly in the absence of any other trauma. The father was requested to leave the room and a diagnosis of “Munchausen Syndrome by proxy” was excluded by asking the child if her parents or anyone else in her family hurt her physically or abused her. She declined vehemently of any such thing.

Finally, when she was asked to open her mouth, her buccal mucosa on the right side showed signs of injury. There were bite marks and bleeding points in the inner side. When the child was confronted with the findings she declined of doing it deliberately. But on further asking and explaining it to her how much of emotional trauma it caused to her family, she finally admitted of biting off her mucosa, taking out the blood with her fingers, and dabbing it on her cheeks when no one was watching. She admitted of doing such to gain attention towards herself.



**Fig 2: The black arrow lines show the bite marks where the patient had chewed her buccal mucosa to induce bleeding**

### Discussion

Haemolacria is undoubtedly one of the most alarming and unusual complaints- in ophthalmology. Bleeding from any site in the humans is an alarming

symptom, and always attracts the attention of healthcare workers to request further investigations and leading to admission to hospitals; this is a reason why patients with factitious disorders present with bleeding from different sites including the gastrointestinal ,respiratory, as well as unusual sites It is a very rare entity, that has many causes, including tumours, conjunctivitis, trauma, retrograde epistaxis, inflammatory polyps, haemangioma, and chloromas to mention a few; but Munchausen syndrome can be seen with ophthalmic manifestations and should be considered in the differential diagnosis when ocular abnormalities cannot be explained after a thorough evaluation.

According to “Diagnostic and Statistical Manual of Mental Disorders” following three criteria requires for the diagnosis of factitious disorder:

1. Intentional production of physical or psychological signs or symptoms
2. Motivation for the behaviour is to assume the sick role, and
3. Absence of external incentives for the behaviour (e.g. economic gain, avoiding legal responsibility, and improving physical well-being, as in malingering).

Patients with factitious diseases are extremely difficult to recognize because they do not appear different from patients with authentic causes of similar symptoms, because their psychiatric abnormalities are not appreciated, and because doctors and nurses have a low index of suspicion.

### Conclusion

Haemolacria is an uncommon but worrisome clinical phenomenon. Management should involve a multidisciplinary approach. Recognition of this psychiatric disease is not only important for correct medical diagnosis and treatment, but also essential in protecting the patients from unnecessary invasive and aggressive medical procedures, and saves the healthcare facilities resources by sparing hospital beds, resources, and money.

**Source of Support:** Nil.

**Conflict of Interest:** None declared.

### References

1. Azari AA, Kanavi MR, Saïpe N, Lee V, Lucarelli M, Potter HD, et al. Transitional cell carcinoma of the lacrimal sac presenting with bloody tears. *JAMA Ophthalmol.* 2013;131:689–90.
2. Girolami A, Allemand E, Berti De Marinis G, Pietrogrande F. Bleeding in Munchausen syndrome. *Gazz Med Ital.* 2012;171:483–9.
3. Ozcan KM, Ozdaş T, Baran H, Ozdogan F, Dere H. Hemolacria: Case report. *Int J Pediatr Otorhinolaryngol.* 2013;77:137.
4. Shah SB, Reichstein DA, Lally SE, Shields CL. Persistent bloody tears as the initial manifestation of conjunctival chloroma associated with chronic myelogenous

- leukemia. Graefes Arch Clin Exp  
Ophthalmol.2013;251:991–92.
5. Sridharan S, Shukla D, Mehta R, Oswal R. Munchausen syndrome masquerading as bleeding disorder in a group of pediatric patients. Indian J Psychol Med. 2011;33:86–8.
  6. Tüfekçi Ö, Gözmen S, Yılmaz ş, Hilkey Karapınar T, Çetin B, Burak Dursun O, et al. A case with unexplained bleeding from multiple sites: Munchausen syndrome by proxy. *Pediatr Hematol Oncol*.2011;28:439–43.