

## An Isolated medial rectus involvement in a case of orbital pseudotumor –A rare clinical entity

Ajay Kumar Arya<sup>1,\*</sup>, Asmita Manoj Kumari<sup>2</sup>, Aalok Kumar<sup>3</sup>

<sup>1,3</sup>Senior Resident, Kings George's Medical University, Lucknow, <sup>2</sup>Senior Resident, Sanjay Gandhi Post Graduate Institute of Medical Sciences, Lucknow

**\*Corresponding Author:**

Email: drajayarya@gmail.com

---

### Abstract

**Purpose:** To report a case of isolated medial rectus muscle involvement in patient of orbital pseudotumor presenting as painless proptosis.

**Case Report:** A 57 year old male presented as painless right proptosis for last 10 months. Patient had blurring of vision for last 3 months. He had revealed non-axial proptosis in right eye with restricted adduction and diplopia. The pupils were normal. There was no history of painful eye movement, fever, photophobia and trauma. Magnetic resonance imaging(MRI) of the orbit was done and revealed uniform enlargement of right medial rectus muscle including muscle belly and tendon. After MRI imaging, the patient was planned for surgical excision as patient had also developed blurring of vision. The endonasal endoscopic translaminar excision was done. Tumor was dissected off from orbital fat and medial rectus muscle. Histopathology showed feature of pseudotumor and no evidence of malignant cells.

**Conclusion:** This is an atypical case of orbital pseudotumor in which only medial rectus of right eye is involved. Orbital pseudotumor may cause painless proptosis and mimic extraocular tumors. MRI may play important role for diagnosing the pseudotumor, its extent and exclude other cause of proptosis.

**Keywords:** Medial rectus, Pseudotumor, Proptosis.

---

### Introduction

Orbital pseudotumor is a non- infectious, non-neoplastic inflammatory disease of orbit without any identifiable cause. After Grave's disease and lymphoproliferative disorder, orbital pseudotumor is the third most common disease of the orbit. It accounts for 10% of all orbital masses<sup>(1)</sup>. Isolated extraocular muscles involvement is a rare and mainly affect females. As it is the diagnosis of exclusion<sup>(2)</sup>, so all secondary cause should be excluded before diagnosis. It may present as non-specific clinical symptoms. In our case this patient was presented as painless proptosis.

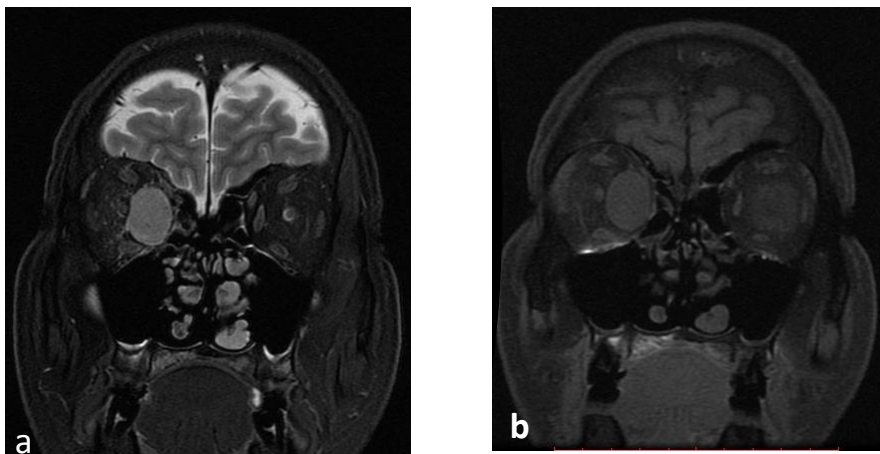
### Case Report

A 57 year old male was presented as painless right proptosis for last 10 months. Patient had blurring of vision for last 3 months. He had no painful eye movement, fever, photophobia. There was no history of trauma and no features of underlying systemic disease. He had no history of oral or genital ulcer, joint pain. Physical examination revealed normal vitals sign. He was conscious with normal higher mental functions. He had no neck swelling or lymphadenopathy. Eye examination revealed non-axial proptosis in right eye with restricted adduction. Patient was also complaining of diplopia. The pupils were normal size and normally reacting. On fundus examination media were clear, disc margin and blood vessels over disc was normal. There was no sign of papilloedema and choroidal fold present on fundus. The rest of the physical examination was normal. No facial hypoesthesia or asymmetry was noted. The lower cranial nerves were intact.

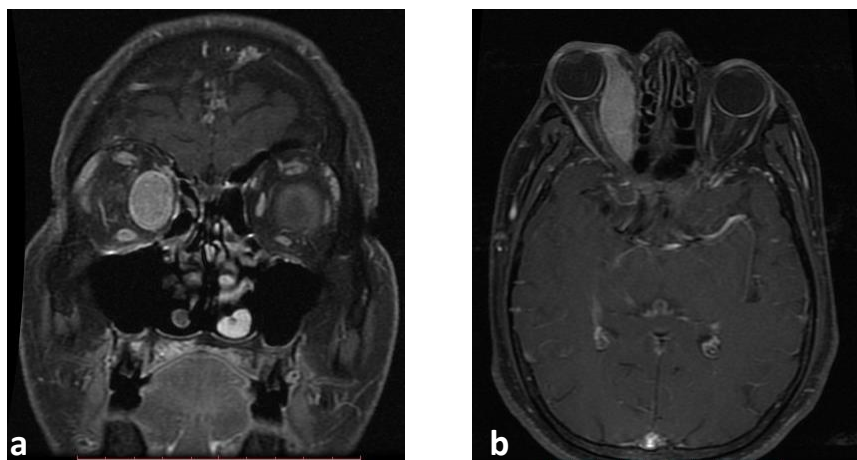
Investigations showed normal total leucocytes count, erythrocyte sedimentation rate (ESR), C- reactive protein. Renal, liver and thyroid function test were normal. Antinuclear antibodies, anti PR-3, anti-MPO were within normal limits. Rheumatoid factor, thyroglobulin antibodies, anti-thyroperoxidase antibodies and ACE were negative. HIV, Hepatitis B & C serology were normal. His chest X-ray was unremarkable.

MRI of the orbit was done and revealed uniform enlargement of right medial rectus muscle including muscle belly and tendon. On T2 –weighted images, muscle was hyperintense and it was isointense to hyointense on T1 –weighted images (Fig. 1 a & b). Enlarged muscle was causing mass effect and displacing the right optic nerve. Post-contrast T1 weighted fat suppressed images showed homogenous enhancement (Fig. 2 a & b). No abnormal soft tissue thickening was noted at orbital apex or along cavernous sinus. MRI brain was normal. No intracranial extension was noted. After MRI imaging, the patient was planned for surgical excision as patient had also developed blurring of vision. The endonasal endoscopic translaminar excision was done. Tumor was dissected off from orbital fat and medial rectus muscle. Excised specimen was sent for histopathology. After surgery patient had improved visual acuity and degree of proptosis was decreased. Otherwise post-operative period was uneventful and patient was discharged after one week. Histopathology showed feature of pseudotumor and no evidence of malignant cells and

granuloma. His symptom was improved in follow up visits.



**Fig. 1 a & b: Coronal T2-weighted image demonstrates bulky medial rectus muscle and hyperintense signal intensity and isointense signal intensity on coronal precontrast T1-weighted image**



**Fig. 2 a & b: coronal and axial post gadolinium contrast with fat suppression T1- weighted images demonstrates bulky medial rectus muscle and homogenous enhancement**

### **Discussion**

The etiology of orbital pseudotumor is unknown, but infection, autoimmune disorder, and aberrant wound healings may cause this. It may have also been associated with infectious diseases such as Streptococcal pharyngitis, viral upper respiratory tract infection and *Borrelia burgdorferi* infection. Orbital pseudotumor is inflammatory disease that causes infiltration and fibrosis involving the orbit diffusely or isolately. Orbital pseudotumor (myositis) is a subgroup of pseudotumor and a common component. It is usually unilateral<sup>(3,4)</sup> with female preponderance. Its clinical presentation could as acute, subacute or chronic with tendency of recurrence. Secondary cause's likes lympho-proliferative disorders, Grave's disease, connective tissue disorders should be excluded.

Granulomatous inflammatory pattern of one category of orbital pseudotumor may mimics sarcoidosis. The ophthalmologists should be aware of the existence of granulomatous orbital pseudotumors not associated with systemic sarcoidosis as a distinct clinicopathologic entity. Sarcoidosis may be revealed by an orbital inflammatory lesion. In our case, no secondary causes were found. Computed tomography (CT) is modality of choice especially in emergency settings. MRI is more sensitive than CT. MRI is very useful in detecting the intracranial extension and better delineation of optic nerve and cavernous sinus.

Corticosteroid is considered as mainstay of treatment, although recurrence is common. Radiotherapy, chemotherapy, betox and surgery are other modalities of treatment. Surgery is not done

commonly, however it is rational if patient has feature of optic nerve involvement or mass effect due tumor itself, like in our case.

Our purpose in this case study is to draw the attention that, orbital pseudotumor may cause painless proptosis and mimic extraocular tumors. MRI may play important role for diagnosing the pseudotumor, its extent and exclude other cause of proptosis.

### **Bibliography**

1. Shikishima K, Kawai K, Kitahara K. Pathological evaluation of orbital tumours in Japan: analysis of a large case series and 1379 cases reported in the Japanese literature. *Clin Exp Ophthalmol* 2006;34:239–244.
2. Jacobs D, Galetta S. Diagnosis and management of orbital pseudotumour. *Curr Opin Ophthalmol* 2002;13:347–351.
3. Medenhall WM, Lessner AM. Orbital pseudotumor. *Am J Clin Oncol* 2010;33:304-306.
4. Ding ZX, Lip G, Chong V. Idiopathic orbital pseudotumor. *Clin Radiol* 2011;66:886-892.