

Study of surgical outcome of sutureless & glueless conjunctival autografting after pterygium surgery: a retrospective study

Sanjeev Kumar^{1,*}, Prakash Kumar², Bimal Chandra³

¹Associate Professor, ²Assistant Professor, ³Professor, Dept. of Ophthalmology, Narayan Medical College, Sasaram, Bihar

***Corresponding Author:**

Email: dr.sanjeevk1@yahoo.co.in

Introduction

The term pterygium comes from the ancient Greek word (pteryx: wing & geon: fin). Pterygium is characterized by a triangular portion of bulbar conjunctiva encroaching upon the cornea⁽¹⁾. Pterygium is most common in the so called "Pterygium area" which is defined by geographical altitude of 40 degree north and south of equator⁽¹⁾. It is more common in adult male involving in outdoor activities⁽²⁾. The exact cause of pterygium is still unknown but UV radiation is supposed to be the most important cause. Other causes include exposure to dry & dusty environment. Pterygium is most often seen from nasal side in the inter-palpebral area. The nasal affinity of pterygium is attributed to the fact that a greater portion of bulbar conjunctiva is exposed to the UV radiation. Secondly there is sparseness of subconjunctival tissue in the temporal region & the temporal region is exposed to a lesser extent to UV radiation due to a greater amount of bowing of outer 2/3rd of upper lids.

The prevalence rate of primary pterygium varies from 0.7 to 3.1% in various populations around the world⁽³⁾. Patient may have foreign body sensation, redness, irritation and is controlled by lubricating eye drops. Indication for surgery include visual impairment, cosmetic disfigurement, motility restriction & recurrent inflammation. Pterygium surgery was evolved significantly over time.

In bare sclera technique, pterygium mass is excised and the underlying sclera is left exposed, unfortunately recurrence rate is up to 50% of cases. To prevent the recurrence, conjunctival autografting by the use of sutures are being done but this technique takes more time for stitches and produces ocular discomfort for several weeks. These complications led to the development of no stitch technique using fibrin glue as adhesive to secure the graft^(5,6). The fibrin glue causes the risk of transmitting reactions and infections. All these lead to the development of sutureless & glueless conjunctival autografting for covering bare sclera. Pterygium excision with sutureless glueless conjunctival autografting is gaining popularity due to its simple technique and lesser recurrence rate.

Postoperative follow up was done on first day, seventh day, first month and sixth month. Patients were enquired about pain and discomfort and examined for

hemorrhage, graft dislocation, graft retraction and recurrences and other postoperative complications.

Material & Methods

All the patients of pterygium that come between 1st March 2016 to 30th August 2016 at Narayan medical college & hospital, Sasaram were randomly selected irrespective of eyes, age and gender. All the cases were examined with slit lamp. Blood sugar, bleeding time, clotting time and xylocaine sensitivity test was performed. Informed consent was obtained from all patients before surgery. Surgical steps: all patients were anesthetized with a peribulbar block and then eyes were painted and draped. The body of pterygium is dissected 4mm away from the limbus down to bare sclera, reflected over the cornea. Pterygium mass was carefully dissected out from the cornea, the subconjunctival fibrovascular tissue including Tenon's capsule were thoroughly removed to provide clear sclera bed. The size of the defect is measured with Vernier caliper. At supero-temporal position conjunctiva was marked in such a way the graft become 1mm larger than bare sclera. A thin Tenon free conjunctival autograft with limbal stem cell is excised. Autograft is slid over the bare sclera and orientation is kept limbus to Limbus. It is slipped over with draping motion to ensure epithelial side is up.

Post-operatively steroid drops are initially given four times a day and tapered over four weeks period. Antibiotic drops were administered four times a day for two weeks. Lubricating eye drops were given four times a day for one month.

Results

All methods adhered to the tenets of the Declaration of Helsinki Principles for research in human subjects. Pre-operative and post-operative visual acuities are recorded. Post-operative complications (immediate and late) were recorded. Final cosmetic outcome was evaluated according to the grading system reported by Prabhasawat et al.⁽¹²⁾

A total of 20 eyes of 17 patients underwent primary pterygium surgery with sutureless and glueless conjunctival autografting. There were 11 male (64.70%) and 6 females (35.30%). The mean age group was 41.85 years. Out of total 20 eyes, 18 eyes (90%) had nasal pterygium and two eyes (10%) had nasal plus

temporal pterygium. Mean graft size was 23.30mm² and the mean surgical time was 16.15 minutes. In our study there was one graft dislocation. The possible reason could be due to patch removal in this patient was done by paramedical staff, in rest of the patients careful patch removal was done by investigator itself. In one of our patient graft retraction was observed on first postoperative day. But on fourth week of post-operative visit, the retracted graft covered the exposed area. There were no recurrence observed in our records up to a follow-up period of 6 months. The mean follow up period was 5.22 month. In one patient vision improved by two Snellen's chart line and cosmetic outcome was found to be excellent in all the patients.

Table 1: The type of pterygium, gender of patients and the Laterality

	Sub-groups	Number	Percentage(%)
Location of pterygium	Nasal	18	90
	Nasal & Temporal	2	10
Gender	Male	11	64.7
	Female	6	35.3
Laterality	OD	8	40
	OS	12	60

Table 2: Results of suture and glue-free autologous grafts for pterygium

Age, mean +/- SD	41.85 +/-10.85 years
Follow-up, mean +/- SD	5.22 +/-1.06 months
Operation time, mean +/- SD	16.15 +/-1.70 minutes
Mean graft size, mean +/- SD	23.30 +/-3.2 mm ²
Recurrence	none
Visual improvement	1 patient
Complications (dislocation/ retraction)	1 dislocation+1 retraction

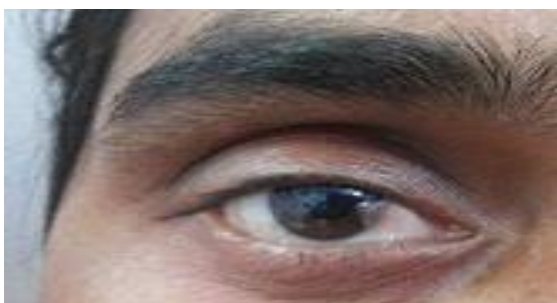

Fig. 1: Primary pterygium

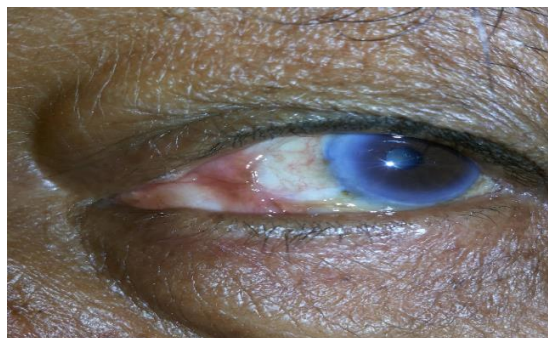


Fig. 2: 1 month post-op

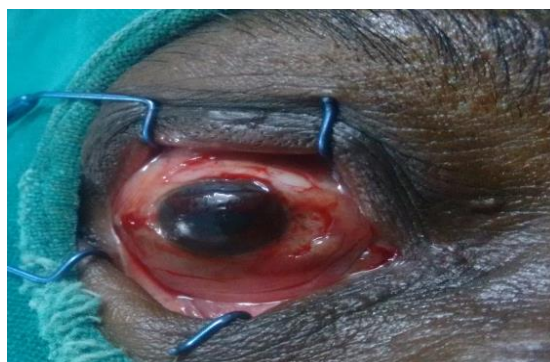

Fig. 2: Intraoperative

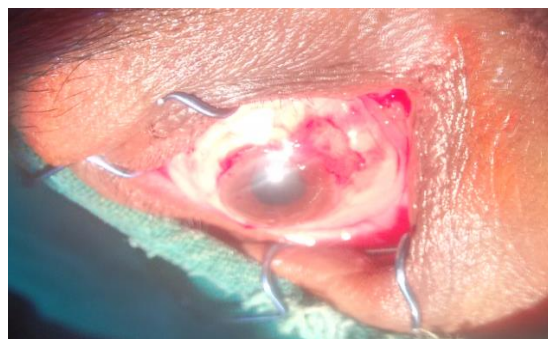

Fig. 3: Post op. after grafting

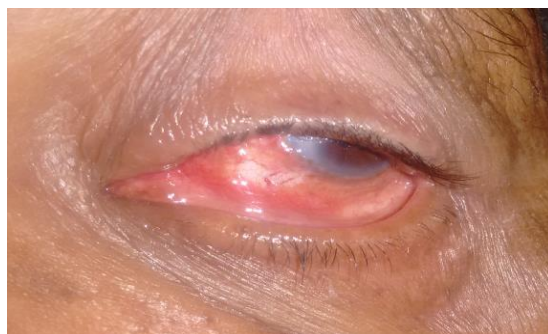

Fig. 4: Graft retraction day 1

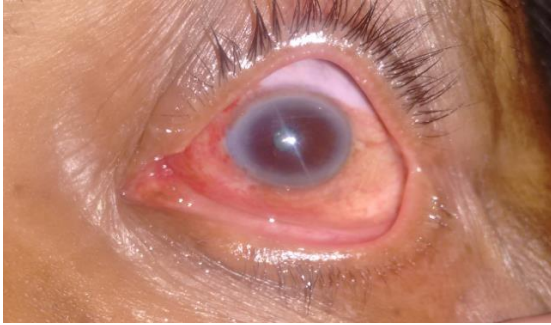


Fig. 5: Resolving graft retraction

Discussion

Currently practiced surgical methods of pterygium excision include conjunctival autografting using suture or glue and sutureless glueless autografting. The presence of sutures may lead to prolong wound healing and fibrosis^(6,8), subsequent complications such as pyogenic granuloma formation are easily treated. Others such as symblepharon, forniceal contracture, ocular motility restrictions, diplopia and sclera necrosis and infections are much more difficult to manage and may be sight threatening^(9,10). As the fibrin glue is manufactured from human plasma, it carries the risk of transmitting diseases.⁽¹²⁾ Most commonly Hepatitis A and Parvovirus B19 are prone to get transmitted through fibrin glue. The fibrinogen compounds may also be susceptible to inactivation by iodine preparations such as those used for conjunctival disinfection before pterygium surgery⁽¹¹⁾. Sutureless glueless conjunctival autografting in pterygium surgery is a simple technique with excellent results.

In Dr Mitra study¹³- a prospective, non-comparative, interventional case series conducted in India- 19 patients underwent graft fixation with autologous blood. The mean surgical time was 11 minutes, no graft dislocation and no recurrence at the end of 6 month follow up.

In our study, the mean surgical time was 16.15 minutes. There was one graft dislocation on the very first postoperative day but there was no recurrence.

Conclusion

No suture no glue conjunctival autografting in pterygium surgery is excellent because of its simple technique, short surgical time, lesser complication, excellent cosmetic outcome and almost no recurrence. This surgery has all the potential to stand the test of the time.

References

1. Duke-Elder S. Leigh AG. In: Duke Elder S(Eds); System of ophthalmology', Vol. 8, Henry Kimpton Publishers, London 1965, PP 573- 585.
2. Hilgers JH. Pterygium on the island of ARUBA. Amsterdam Klein offset Drukkerij Poortpers NV 1959.
3. Detels R. Dhir SP Pterygium: a geographical survey. Arch Ophthalmol. 1967;78:485-491.
4. Avala M. Results of pterygium surgery using a biologic adhesive cornea 2008;27:663-667.
5. Kim HH Mun HJ, Park YJ Lee KW, Shin JP. Conjunctivolimbal autograft using a fibrin adhesive in pterygium surgery. Korean J Ophthalmol. 2008;22:147-154.
6. Koranvi G. Seregard S. KOPPED. The cut and paste method for primary pterygium surgery: Long term follow up. Acta Ophthalmologica Scandinavica 2005;83:298-301.
7. Koryani G., Seregard S, Kopp ED. A no suture small incision approach to pterygium. Br J Ophthalmol 2004;88:911-914.
8. Allan BD, Short P Crawford GJ, Barret GD, Constable IJ. Pterygium excision with Conjunctival autografting: An effective and saqfe technique. Br. J. Ophthalmol 1993;77:698-701.
9. Solomon A Pires RT, Tseng SC Amniotic membrane transplantation after extensive removal of primary and recurrent Pterygia. Ophthalmology 2001;108:449-460.
10. Vrabc MP, Weisenthal RW, Elsnig SH. Subconjunctival fibrosis after autograft. Cornea 1993;12:181-183.
11. Glimor OJ, Reid C. Prevention of intraperitoneal adhesions: a comparison of noxythiolon and a new providone – iodine PVP solution. Br J Surg 1979;66:197–199.
12. Prabhasawat P, Barton K, Burkett G, Tseng SC. Comparison of conjunctival autografts, amniotic membrane grafts and primary closure for pterygium excision. Ophthalmology 1997;104:974-985.
13. Mitra S et al. Autoblood as tissue adhesive or conjunctival autograft fixation in pterygium surgery. Poster presented at the annual meeting of the American academy of ophthalmology; Oct 22 and 23, 2011; Orlando Fla.