

## Comparison between sutureless conjunctival autograft using autologous blood versus sutured limbal conjunctival autograft in primary pterygium surgery

Hemalatha BC<sup>1,\*</sup>, Pradeep<sup>2</sup>, SB Shetty<sup>3</sup>, Malavika K<sup>4</sup>

<sup>1</sup>Assistant Professor, <sup>2</sup>Junior Resident, <sup>3</sup>Professor & HOD, <sup>4</sup>Professor, Dept. of Ophthalmology, MS Ramaiah Medical College, Karnataka

**\*Corresponding Author:**

Email: subhema@gmail.com

### Introduction

Pterygium is an abnormal sub-conjunctival fibro-vascular overgrowth, commonly seen in tropical countries as this population has increased exposure to light, dust, wind and heat. The main treatment of pterygium is surgical excision. However, recurrence is a bothersome issue. To avoid recurrence conjunctival autograft with mitomycin use is an option however there is a risk of scleral necrosis. Conjunctival graft may be held in place either with sutures or fibrin glue. Suture technique is when used increases the operative time, postoperative discomfort and is sometimes associated with postoperative complications like infection/abscess formation and pyogenic granuloma. Use of fibrin glue has gained the popularity to circumvent the use of sutures and its associated complications. Apart from increasing the cost of surgery there is a potential risk of anaphylaxis and prion disease transmission with use of fibrin glue. In this study we have used autologous blood for achieving the adherence of the conjunctival auto-graft and compared the technique with that of conventional sutured auto-graft for primary pterygium surgery.

### Materials and Methods

**Study design:** This was a prospective study conducted at Dr M S Ramaiah medical college between June 2012 and June 2016. Fifty patients diagnosed with pterygium were included in the study based on the following inclusion and exclusion criteria.

**Inclusion criteria:** Patients aged more than 18yrs who presented with pterygium and were symptomatic (redness, cosmetic, irritation, watering) and patients with pterygium threatening the visual axis were included in the study.

**Exclusion criteria:** Atrophic pterygium, pseudopterygium, recurrent pterygium with multiple surgeries, any other limbal surgery, ocular surface disorders. Patients > more than 65yrs, patients on anti-platelet/ anti-coagulant drugs were excluded from the study.

The patients who met the inclusion criteria and consented for the study were included. They were assigned to one of the two treatment groups after being randomised by odd or even number method. Patients with odd numbers were assigned to group 1 and they

underwent a pterygium excision along with autologous blood assisted sutureless conjunctival auto-graft while patients with even numbers were assigned to group 2 and they underwent pterygium excision along with suturing of conjunctival autograft.

Institute's Ethics Committee approval was obtained. The study adheres to the tenets of the Declaration of Helsinki for research in humans and informed written consent was obtained from all patients.

**Pre-operative workup:** All patients underwent a comprehensive ophthalmologic examination including visual acuity, refraction, slit lamp bio-microscopy, measurement of intraocular pressure, extra-ocular muscle movements and dilated funduscopy. Anterior segment photography was taken for documentation of pterygium size and morphology. Other procedures like Keratometry, Corneal Topography and Probe test were done if required. These patients were followed up to minimum of 3 months postoperatively.

### Procedure

**Group 1: Autologous blood assisted suture less conjunctival auto-graft group:** Patients in this group underwent pterygium excision followed by autologous blood assisted conjunctival auto-graft. In this group haemostasis was allowed to occur spontaneously without use of cautery to provide autologous fibrin to glue the conjunctival autograft and the scleral bed was viewed through the transparent conjunctiva to ensure that residual bleeding did not lift the graft. The graft was held in position for 10 min by application of gentle pressure over the graft with fine non-toothed forceps. Graft adherence and positioning is examined 10 min after grafting. Fig. 1

**Group 2: Sutured conjunctival auto-graft:** Patients in this group underwent conjunctival auto graft with conventional method of suturing using 8-0 vicryl or 9-0 nylon. First the two limbal corners were sutured into the episclera and then the posterior corners of the graft were sutured to the bulbar conjunctiva.

In both the groups a pressure eye patch was applied for 24 hours, systemic analgesia was given twice daily. Topical steroid antibiotic combination (moxifloxacin with difluprednate) four times daily was started from the first post-operative day which was gradually tapered

over 4 weeks while topical lubricating eye drops 4-6 times/ day was prescribed for four to six weeks. The patients were instructed to wear protective glasses to avoid direct sun exposure, dust and also asked not to rub their eyes.

All patients were followed up 1 day after surgery, then weekly for the first one month. Later they were reviewed at 3 months and at 6th month. They are examined for haemorrhage, chemosis, wound gape, graft shrinkage, graft dehiscence, recurrence or any other complication. Patients also completed a questionnaire at the end of first month follow up. The questionnaire was scored from (0 to 3) 0 = nothing; 1 = mild; 2 = moderate; 3 = severe for grading pain, foreign body (F.B) sensation, photophobia, hyperaemia and chemosis into four grades according to the intensity. Also the overall satisfaction with the procedure post-operatively at 3 weeks was recorded as four grades 0 = unsatisfied; 1 = low satisfaction; 2 = moderate satisfaction and; 3 = highly satisfied. The data were collected and recorded among both the groups to compare for ocular signs and symptoms, and overall satisfaction.

### Postoperative Follow-up

The outcome of this study was categorised into primary secondary and others to determine the incidence of recurrence and patient's satisfaction, Operative time-Calculation, gained visual acuity postoperatively in each procedure measured. The main postoperative primary outcome is assessing the recurrence rate i.e. fibrovascular proliferation invading the cornea more than 1.5 mm at the site of previously excised pterygium. Complications were recorded like persistent epithelial defect, dellen, inclusion cyst, scarring and infection like pyogenic granuloma, conjunctival edema, corneal scleral necrosis, infective scleritis, keratitis endophthalmitis.

### Results

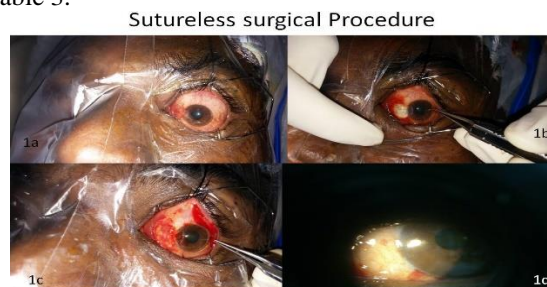In our study all patients had a minimum 3 months, follow-up range up to 6 to 30 month, mean follow up was 16 months. The preoperative characteristics along with grading of pterygium is summarised in Table 1. Age of patients varied from 23 to 80 years (average = 65yrs) and was comparable between the two groups Table 2. In both the groups majority were female's patients, residing at Kolar and Tumkur belt and cosmesis was the main indication among the female patient's housewife's inoccupation. With respect to site and grade of pterygium in both the groups majority were nasal pterygium and grade 2 in grading. In both the group astigmatism induced ranged from 0.5 to 1.5 mm against the rule, the incidence being group 1 with suture less had 32% whereas group 2, 24% comparable. In suture group 11 patients (44%) had combined with cataract surgery whereas 12 (48%) patients among

sutureless group, thus the difference between the group not significant.

**Intraoperative:** Duration of surgery calculated from starting of pterygium surgery to end point once the graft stabilized. Time for allowing the blood clot to form in group 1 is 8-10 minutes. The mean duration of surgery was for was 14 minutes (range 12-20 min) in group 1 and 24 minutes (range 20-30min) in group 2. Thus operative time was significantly shorter in the group with suture less than in group 2 with suture. In combined surgery cases with cataract, time taken for cataract surgery was excluded in both the groups.

In the immediate post-operative period more patients in the suture group were symptomatic and complained of inability to open the eye due to pain, irritation, foreign body sensation and watering (14 patients, 56%) compared to suture less group using autologous blood (4 patients, 16%)( $p < 0.05$ ). However, post suture removal i.e. after 2 to 4 weeks both the groups did not have significant symptoms that the patients complained of Fig. 4a,b.

In the sutured group no patients had any graft displacement; where as in sutureless group 5 patients had graft displacement. In all these 5 cases the displacement was noticed on the first postoperative day. None of them required intervention as the displacement was mild. The graft was recessed temporarily in 3 cases and in 2 patients there was a mild displacement over corneal surface Fig. 2. In both the groups corneal reepithelialisation was completed within 2 weeks postoperatively. One of the patients in the group 1 developed a rare complication, a pyogenic granuloma Fig. 3a, b, c at graft host junction. Patient underwent a surgical excision followed by intensive topical steroid drops. He responded well to the treatment. None of other patients developed complications like corneal vascularization, graft necrosis, symblepharon at the donor site during their follow-up. There was no post-operative recurrence of pterygium in both the groups on long term follow-up. Fig. 5, 6. In the post-operative period the patient satisfaction was high i.e. 94% among sutureless group when compared with the suture group i.e. only 10% of patients due to suture related problems Table 3.



**Fig. 1a: Nasal pterygium, b: bare scleral bed post pterygium excision, c: conjunctival graft placed over the scleral bed after rupturing a blood vessel after 10mts. D: graft well taken up over a scleral bed on 6<sup>th</sup> week, with healed corneal epithelium**

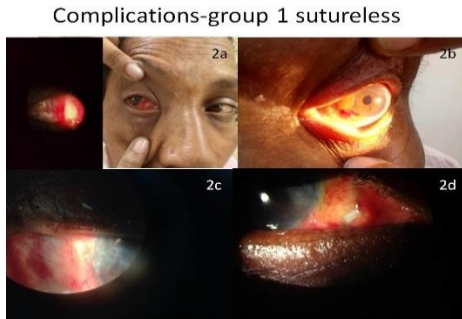

Fig. 2 a, c, d: Conjunctival graft recession on temporal, b: Graft recessed superiorly

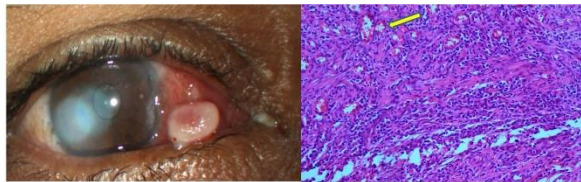


Fig 3a; Preoperative, Pyogenic granuloma Fig 3b; HISTOPATHOLOGY REPORT- Necrosis and granulation tissue. ie prominent endothelial proliferation and chronic inflammation rich in lymphocytes and plasma cell.

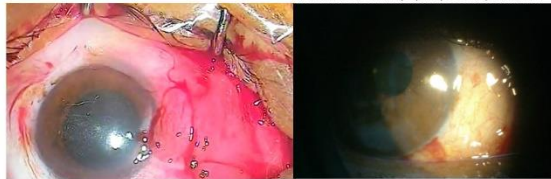

Fig 3c; Post surgery –sutureless graft in situ, day1 Fig 3d; Post-operative at 3<sup>rd</sup> month, graft in situ

Fig. 3: Complication-Sutureless Group Pyogenic granuloma

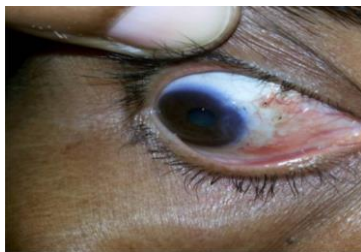

Fig. 4a: Conjunctival congestion with vascularisation adjacent to suture

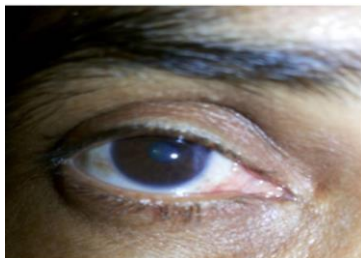


Fig. 4b: Post-suture removal resolved conjunctival reaction

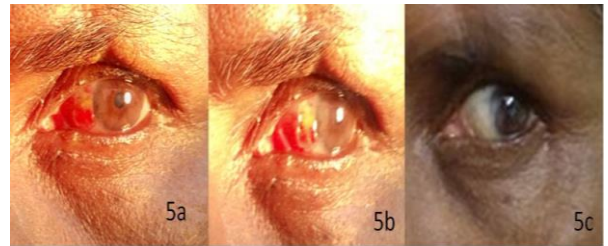


Fig. 5a: At day 1 post-operative, b: At 1 week blood clearing at scleral bed, c: At 18 months year post-operative graft

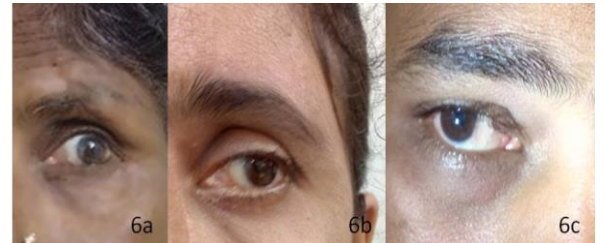

Fig. 6a: Long term follow up 1-18 month, b: 24 month, c: 36 month-post graft sutureless

Tables 1: Grades of Pterygium in different groups

Grades of Pterygium	Group -1 sutureless	Group -2 suture
1-midway between limbus and pupil border	24%	40%
2-extends up to pupil border	64%	40%
3-crosses pupil	12%	20%

Table 2: Results of suture and sutureless using autologous blood for pterygium

	Group-sutureless	Group -suture
No of eyes	25 eyes	25 eyes
OD	12	10
OS	13	15
Location	24 nasal/1 temp	20 nasal/5 temp
Gender, F:M	18:7	16:9
Age, mean SD	65	70
Followup, range	6 to 30 months	6 to 28 months
Operation time	15-18mts	30 mts
Recurrence	none	None
Complication	4 graft displacement, one pyogenic granuloma	15-irritation and redness

**Table 3: Patient satisfaction-3 to 6 week**

Patient satisfaction - grades	Group - sutureless	Group -suture
0= Unsatisfied	nil	60%
1= Low satisfaction	nil	20%
2= Moderate satisfaction	6%	10%
3= Highly satisfied	94%	10%

## Discussion

The aim of pterygium surgery is to excise the pterygium and prevent its recurrence. In order to reduce the incidence of recurrence variety of techniques, such as amniotic membrane graft conjunctival autograft, and limbal conjunctival transplant and use of fibrin glue have been tried<sup>1,2,3</sup>. Adjunctive therapies include Beta irradiation, Thiotepa, 5-Fluorouracil, Daunorubicin, and mitomycin C application are also been done. (MMC)<sup>4,5,6,7</sup> Use of adjunctive therapy risks complications.

The most preferred surgical procedure post pterygium excision is conjunctival autografting using sutures mainly because of its lower recurrence and complication rate.<sup>3</sup> Although it is considered as a safe and effective surgical technique it requires more surgical expertise and surgical time.<sup>8</sup> In our study we compared this established technique with a suture less surgical technique. A suture less technique is quicker at the same time avoids complications of suture like infection and increased inflammation, also according to Sridhar et al<sup>9</sup> there is no role of suture in wound healing and may traumatise adjacent tissue as well.

To help the graft adhere to the scleral bed commercially available fibrin glues from pooled human plasma is commonly used, it carries a risk of transmissible diseases like hepatitis A and parvovirus<sup>10,11</sup>. To prevent this in our study we used autologous blood serum easy way to procure fibrin for graft adhesion. After the securing conjunctival autograft using autologous blood, we patched the eyes for 24 hours. Patients were instructed strictly "not to rub their eyes" for 24 hours. The good apposition of lids over the bulbar conjunctiva itself acts as a biological dressing helping in excellent wound healing. Vascularization of episcleral bed within a week post grafting as reported by Tayanç et al<sup>12,13</sup> will be further enhanced by autologous blood, resulting early firm adhesion of the graft over the episcleral bed thereby preventing occurrence of recurrence. The reported conjunctival healing rates is  $3.16 \pm 0.17 \text{ mm}^2$  per day in rabbit models as mentioned by Zhu X et al.<sup>21</sup> and most of our grafts are smaller in size ie 4 to 6 mm hence we can expect good and quick healing.

In our study we did not any recurrence in both the groups, compared to other studies Hirst and Ang et

al<sup>14,15</sup> recurrence rate being 2%-39%. The operating time in both groups and postoperative symptoms complained in conventional techniques group with sutures were comparable to studies done by Kim, Koranyi and Allan et al.<sup>16,17,18</sup>

In both the groups 44% in group 1 and 48% in group 2 underwent pterygium excision combined with cataract surgery. This gave an advantage of avoiding additional surgery as mentioned by Gulani<sup>20</sup>, with no additional risk of graft displacement. Along with complications like graft recession, we had a rare case of pyogenic granuloma in sutureless group at graft host junction, which known to be associated with suture.<sup>14,19</sup> which was treated with surgical excision successfully.

In conclusion, the use of autologous blood for the attachment of conjunctival autografts in pterygium surgery is an effective procedure to reduce the risk of recurrences. Also Autologous blood in pterygium surgery is an economical alternative to fibrin glue. This technique not only shortens there operating surgical time but also delivers good results and can be a safe alternative to fibrin glue. Most of our patients were highly satisfied in the sutureless group as they had minimal postoperative discomfort and had early recovery. Most patients had satisfaction from the cosmetic point of view as this was the major indication of surgery in majority of our female patients. Comparable results in both the groups indicate that, this technique can be considered as alternative method of conjunctival autograft after pterygium excision in developing countries.

## References

1. Tan DTH, Chee SP, Dear KBG, *et al.* Effect of pterygium morphology on pterygium recurrence in a controlled trial comparing conjunctival autografting with bare sclera excision. *Arch Ophthalmol* 1997;115:1235-40.
2. Tananuvat N, Martin T. The results of amniotic membrane transplantation for primary pterygium compared with conjunctival autograft. *Cornea* 2004;23:458-63.
3. Prabhawat P, Barton K, Burkett G, *et al.* Comparison of conjunctiva autografts, amniotic membrane grafts, and primary closure for pterygium excision. *Ophthalmology* 1997;104:974-85.
4. Smith S, D'Amore PA, Dreyer EB. Comparative toxicity of mitomycin C and 5 fluorouracil *in vitro*. *Am J Ophthalmol* 1994;118:332-7.
5. Sodhi PK, Verma L, Pandey RM, Ratan S. Comparison between the role of intraoperative mitomycin C and doxorubicin in preventing the recurrence of primary pterygium. *Ophthalmic Res* 2004;37:1-6.
6. Cassady JR. The inhibition of pterygium recurrence by thiotepa. *Am J Ophthalmol* 1966;61:886-8.
7. Ajayi BG, Bekibele CO. Evaluation of the effectiveness of postoperative beta irradiation in the management of pterygium. *Afr J Med MedSci* 2002;31:9-11.
8. Ti SE, Chee SP, Dear KB, *et al.* Analysis of variation in success rates in conjunctival autografting for primary and recurrent pterygium. *Br J Ophthalmol* 2000;84:385-9.

9. Sridhar MS, Bansal AK, Rao GN. Surgically induced necrotizing scleritis after pterygium excision and conjunctival autograft. *Cornea* 2002;21:305-7.
10. Chan SM, Boisjoly H. Advances in the use of adhesives in ophthalmology. *Curr Opin Ophthalmol* 2004;15:305-10.
11. Biedner B, Rosenthal G. Conjunctival closure in strabismus surgery: Vicryl versus fibrin glue. *Ophthalmic Surg Lasers* 1996;27:967.
12. Tayanç E, Akova YA, Yilmaz G, et al. Anterior segment indocyanine green angiography in pterygium surgery with conjunctival autograft transplantation. *Am J Ophthalmol* 2003;135:71-5.
13. Kucukerdonmez C, Akova YA, Altinörs DD. Vascularization is more delayed in amniotic membrane graft than conjunctival autograft after pterygium excision. *Am J Ophthalmol* 2007;143:245-9.
14. Hirst LW. The treatment of pterygium. *Surv Ophthalmol* 2003;48:145-80.
15. Ang LP, Chua JL, Tan DT. Current concepts and techniques in pterygium treatment. *Curr Opin Ophthalmol*, 2007;18:308-13.
16. H.H. Kim, H.J. Mun, Y.J. Park, K.W. Lee, J.P. Shin, Conjunctivolimbal autograft using a fibrin adhesive in pterygium surgery, *Korean J Ophthalmol*, 22, 2008, pp. 147-154 -21.
17. G. Koranyi, S. Seregard, E.D. Kopp, Cut and paste: a no suture, small incision approach to pterygium surgery, *Br J Ophthalmol*, 88, 2004, pp. 911-914.
18. B.D. Allan, P. Short, G.J. Crawford, G.D. Barrett, I.J. Constable, Pterygium excision with conjunctival autografting: an effective and safe technique, *Br J Ophthalmol*, 77, 1993, pp. 698-701.
19. Fryer RH, Reinke KR. Pyogenic granuloma: a complication of transconjunctival incisions. *Plast Reconstr Surg*. 2000;105:1565-66.
20. Gulani A, Dastur YK. Simultaneous pterygium and cataract surgery. *J Postgrad Med*. 1995 Jan-Mar;41(1):8-11.
21. Zhu X, Beuerman RW, Cheng ZY, Ang LPK, Tan DTH. Kinetic analysis of conjunctival epithelial wound healing in the rabbit model. *Invest Ophthalmol Vis Sci* 2005;46:4247.