

## Circumscribed choroidal hemangioma- A case report

Shairin Jahan<sup>1,\*</sup>, Rahul Gupta<sup>2</sup>, Gargi Nagpal<sup>3</sup>, Naheed Akhtar<sup>4</sup>, Abdul Waris<sup>5</sup>

<sup>1,2,3</sup>Post Graduates,<sup>4</sup>Assistant Professor. Dept. of Ophthalmology. Institute of Ophthalmology, JNMCH, Aligarh

**\*Corresponding Author:**

Email: jahanshairin@gmail.com

### Abstract

Choroidal hemangioma is a rare, benign vascular ocular tumor that presents as either a circumscribed mass or as a diffuse variant. Circumscribed choroidal hemangiomas (CCH) resemble posterior segment lesions such as choroidal melanoma, choroidal metastases, central serous chorioretinopathy, or nonspecific retinal detachment. A circumscribed choroidal hemangioma often appears as a subtle red–orange mass or as a greyish lesion in the posterior choroid. In rare instances, CCH may be associated with sub retinal fluid accumulation and retinal detachment. In the literature, CCH have been reported in Caucasian, Hispanic and Chinese patients. However, research and case reports about CCH in young Indian patients are relatively rare. Here, we present a case of a middle aged Indian male who presented to Retina Clinic, AMUIO, and Aligarh with the complaints of reduced vision and central scotoma in right eye. After a detailed clinical examination and investigations, a diagnosis of CCH in right eye was made and the patient was advised Photodynamic Therapy.

**Keywords:** Central serous chorioretinopathy; Choroidal hemangioma; Choroidal melanoma; Choroidal metastasis; Retinal detachment; Sturge-Weber syndrome.

### Introduction

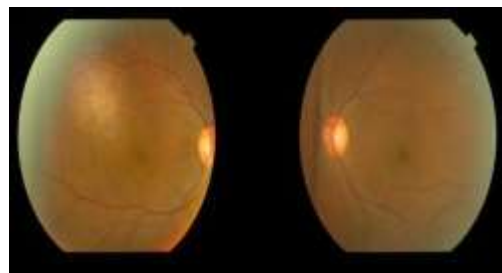
Circumscribed choroidal hemangiomas (CCHs) are benign tumors that occur sporadically, without any associated local or systemic anomalies. CCH usually appears between the second and sixth decade of life, causing visual disturbances due to exudative retinal detachment or macular edema<sup>[1-3]</sup>. They are relatively uncommon, but their precise incidence in the general population is unknown. They affect both sexes and all ethnic groups. The patient may complain of visual disturbances such as reduced vision, metamorphosis, photopia, visual field defects, and progressive hypermetropia. Examination of CCH reveals an orange-red choroidal mass with margins that blend with the surrounding choroid. It usually locates the posterior pole and is not thicker than 6mm<sup>2</sup>. A pigmented rim sometimes surrounds the tumor, and sub retinal fluid from the tumor leading to an exudative retinal detachment is generally present in symptomatic cases.

Although choroidal hemangiomas are vascular tumors, prominent intrinsic tumor vessels, or “feeder vessels,” are not present on clinical examination. Some studies have reported secondary changes, such as degeneration of the overlying choriocapillaries, focal proliferation of the RPE, fibrous metaplasia, cystoid macular edema, retinoschisis, and ossification<sup>[3-4]</sup>. Such ossification may clinically resemble a choroid stoma.

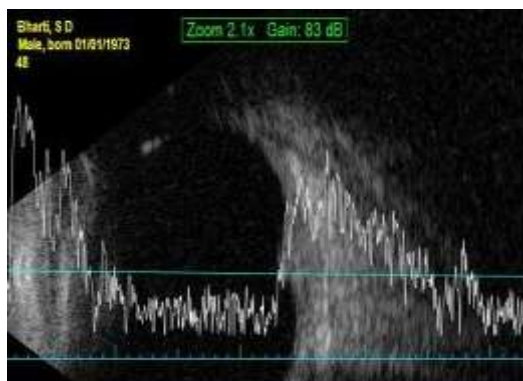
### Case Report

A 43 year old male presented to Retina Clinic, AMUIO, and Aligarh with the complaints of reduced vision and central scotoma in right eye for 20 days on 19<sup>th</sup> December 2015. There were no other associated ocular complaints like meteor phopsia, visual, photopia, floaters or pain. Under diffuse light condition, head posture, facial symmetry, forehead, eyebrows, lids,

HBCR, ocular movements were all within normal limits. On ocular examination, the uncorrected visual acuity in right eye was 6/18 while it was 6/6 in left eye. The best corrected visual acuity in right eye was 6/9 with +1.0 DS while it was 6/6 in left eye with plain glasses. The intraocular pressure measured by non-contact tonometer was found to be 16 mm of Hg in right eye and 14 mm of Hg in left eye. Anterior segment was within normal limits in both the eyes. Dilated fundus examination of right eye showed an elevated sub retinal red-orange lesion super temporal to the fovea. Optic disc was normal with C: D ratio of 0.3 and blood vessels were also found to be normal and foveal reflex was normal. Dilated fundus examination of left eye revealed normal optic disc with C: D ratio of 0.3. Blood vessels and background were normal. Macula was healthy and foveal reflex was present. FFA and B-Scan were advised to the patient. FFA revealed rapid, spotty hyper fluorescence in the early arterial phase and diffuse intense late hyper fluorescence. B-scan showed an acoustically solid lesion with a sharp anterior surface, without choroidal excavation and orbital shadowing.



**Fig. 1: (Fundus photography showing an elevated lesion supero temporal to the macula in right eye with normal fundus findings in left eye)**



**Fig. 2: B-scan showing mound elevating the retina in right eye**

The diagnosis of CCH was made on the basis of FFA and B-scan findings. The patient was advised Photodynamic Therapy (PDT) in right eye.

### Discussion

Timely diagnosis and treatment is critical as these benign tumors predominantly affect the posterior choroid, causing significant visual disturbance.

### Diagnosis of choroidal hemangioma

The diagnosis of choroidal hemangioma is a combination of clinical features and ancillary tests. Clinically, circumscribed hemangioma appears as a subtle red-orange mass in the posterior choroid. Ancillary testing for choroidal hemangioma includes the diagnostics below. Ultrasonography-Choroidal hemangioma shows high internal reflectivity (A-scan) and acoustic solidity (B-scan). Fluorescein angiography- In early arterial phase, hyper fluorescence of the mass is evident with late diffuse hyper fluorescence. Indo cyanine green angiography- This test shows early hyper fluorescence by 1 minute with late dye washout at 20 minutes, appearing hypo fluorescent relative to the surrounding choroid. Auto fluorescence-Choroidal hemangioma shows little intrinsic auto fluorescence. Overlying lipo fuscini and fresh sub retinal fluid show hyper auto fluorescence and RPE hyperplasia and atrophy show hypoauto fluorescence.

### Treatment Options

The decision to treat a CCH should be individualized. The physician should base treatment on the extent of symptoms, loss of vision, and the potential for visual recovery. Laser photocoagulation (Xenon or Argon) has been an effective treatment modality for hemangioma for many years. Currently, laser photocoagulation is rarely used to treat hemangiomas as this has been largely replaced by photodynamic therapy. Shields and coworkers reported 62% resolution of sub retinal fluid and 71% stability of vision with argon laser photocoagulation<sup>[5]</sup>.

Photodynamic therapy (PDT) using verteporfin has been used with considerable success as treatment of small to medium-size circumscribed choroidal hemangiomas in recent years and is currently regarded as the treatment of choice for such lesions<sup>[6-8]</sup>. In some cases, PDT has been combined with intravitreal anti-vascular endothelial growth factor (anti-VEGF) drug therapy to treat eyes with a large amount of turbid sub retinal fluid, subfoveal tumor location, or both. In some centers, long-duration, low power, large spot size infrared laser hyperthermia (frequently referred to as 'TTT (trans pupillary thermotherapy) has been employed as an alternative to PDT with considerable success in selected cases<sup>[9]</sup>.

In patients who have an extremely thick choroidal hemangioma, extensive non-rhegmatogenous retinal detachment, or a diffuse or circumscribed choroidal hemangioma that failed to respond to photodynamic therapy, low-dose ocular irradiation appears to be an effective therapeutic option. Several different radiation therapy methods (external beam photon radiotherapy<sup>[10]</sup>, plaque radiotherapy<sup>[11]</sup>, proton beam irradiation<sup>[12]</sup>, gamma knife radiotherapy<sup>[13]</sup>, and stereotactic radiotherapy<sup>[14]</sup> have been employed with good success in selected patients. When external beam radiotherapy or proton beam irradiation is used, the eye is usually treated to a target dose of approximately 12–20Gy. When plaque radiotherapy is employed, the tumor is usually treated to an apex dose of approximately 20–30 Gy. These forms of radiation therapy induce partial or total tumor regression, stimulate gradual reabsorption of sub retinal fluid that is usually sustained for many months to years, and preserve useful vision in at least some affected eyes.

Anti-vascular endothelial growth factor (anti-VEGF) agents are known to reduce vascular permeability and hasten resolution of sub retinal fluid and intraregional edema in a multitude of ophthalmic pathologies. Sagong and coworkers reported beneficial effect of bevacizumab (Avastin, Genentech) for three patients with circumscribed hemangioma<sup>[15]</sup>.

### References

1. Shields CL, Honavar SG, Shields JA, Cater J, Demirci H. Circumscribed choroidal hemangioma: clinical manifestations and factors predictive of visual outcome in 200 consecutive cases. *Ophthalmology*.2001;108:2237-2248.
2. Anand R, Augsburger JJ, Shields JA. Circumscribed choroidal hemangiomas. *Arch ophthalmology*. 1989;107:1338-1342.
3. Mashayekhi A, Shields CL. Circumscribed choroidal hemangioma. *Curr Open Ophthalmology*. 2003;14:142-149.
4. Heimann H, Damato B. Congenital vascular malformations of the retina and choroid. *Eye (Lond)*.2010;24:459-467.
5. Gill H.S., Simpson R.: Trans pupillary thermotherapy in the management of juxtapapillary and parafoveal circumscribed choroidal hemangioma. *Can J Ophthalmology* 2005;40:729-33.

6. Kivela T., Tenhunen M., Joensuu T., et al: Stereotactic radiotherapy of symptomatic circumscribed choroidal hemangiomas. *Ophthalmology* 2003;110:1977-1982.
7. Michels S., Michels R., Simader C., Schmidt-Erfurth U.: Verteporfin therapy for choroidal hemangioma: a long-term follow-up. *Retina* 2005;25:697-703.
8. Nam T.K., Lee J.I., Kang S.W.: Gamma knife radiotherapy for circumscribed choroidal hemangioma. *Acta Neurochir (Wien)* 2005;147:651-654.
9. Schulenburg A., Piguat B., Zografos L.: Indocyanine green angiographic findings in choroidal hemangiomas: a study of 75 cases. *Ophthalmological* 2001;214:246-252.
10. Schilling H., Sauerwein W., Lommatzsch A., et al: Long-term results after low dose ocular irradiation for choroidal haemangiomas. *Br J ophthalmology* 1997;81:267-273.
11. Witschel H., Font R.L.: Hemangioma of the choroid. A clinic pathologic study of 71 cases and a review of the literature. *Surv Ophthalmology* 1976;20:415-431.
12. Zografos L., Bercher L., Chamot L., et al: Cobalt-60 treatment of choroidal hemangiomas. *Am J Ophthalmology* 1996;121:190-199.
13. Zografos L., Egger E., Bercher L., et al: Proton beam irradiation of choroidal hemangiomas. *Am J Ophthalmology* 1998;126:261-268.
14. Sagong M, Lee J, Chang W. Application of intravitreal bevacizumab for circumscribed choroidal hemangioma. *Korean J Ophthalmology*. 2009;23:127-13.