

Rare case of polypoidal choroidal vascular angiopathy: A case report

Kamya Sharma¹, Rajendra P Maurya^{2,*}, Mahendra K Singh³, Prashant Bhushan⁴, Shrinkhal⁵

¹Senior Resident, ^{2,4}Assistant Professor, ³Professor, ⁵Junior Resident, Dept. of Ophthalmology, Institute of Medical Sciences, Banaras Hindu University, Varanasi

***Corresponding Author:**

Email: mauryap_bhu@yahoo.com

Abstract

Polypoidal choroidal vasculopathy (PCV) is currently recognized as a phenotype of age-related macular degeneration (AMD). PCV is also known as "posterior uveal bleeding" and is believed to be a type of choroidal neovascularization, PCV often shows several unique clinical manifestations which appears to be different from typical neovascular AMD (tAMD). The primary abnormality involves the choroidal circulation, and the characteristic lesion is an inner choroidal vascular network of vessels ending up as an aneurysmal bulge or outward projection, visible clinically as a reddish orange, spheroid, polyp-like structure. The usual age of onset of polypoidal CNV is between 50 and 65 years with an average of 60.1 years. Here an unusual case of Polypoidal choroidal vasculopathy in 32 years male with history non-resolving enteric fever is being presented and pathogenesis, clinical features, investigation findings and management are discussed.

Introduction

Polypoidal choroidal vasculopathy (PCV) was first time described by Yannuzzi LA et al in 1982^[1]. Various names were given like "posterior uveal bleeding syndrome"^[2] or "multiple recurrent retinal pigment epithelium detachments"^[3].

Indocyanine green angiography (ICG) and optical coherence tomography (OCT) is the imaging modality of choice in assessing the PCV. Diagnosis is based on ICG and confirmed with fundus characteristics and OCT findings. The primary abnormality involves the choroidal circulation and the characteristic lesion is the inner choroidal vascular network of vessels ending, in an aneurysmal dilatation which appears clinically as a reddish orange, spheroid, polyp-like structure.

The natural course of the disease often have a remitting-relapsing course, and clinically, it is associated with chronic, multiple, recurrent serosanguineous detachments of the retinal pigment epithelium and neurosensory retina with long-term preservation of good vision^[4].

However, the classification of PCV as distinct subtype of exudative age-related macular degeneration (AMD) easily differentiated from other diseases and other subtypes of choroidal neovascularization associated with AMD is still a great challenge.

Polypoidal choroidal vasculopathy has also been described in different pathological conditions including central serous chorioretinopathy^[5], circumscribed choroidal hemangioma^[6]; melanocytoma of the optic nerve^[7]; pathological myopia and staphyloma^[8]; or choroidal osteoma^[9]. It behaves like a neovascularopathy occurring in a variety of different diagnoses than a distinct abnormality of the inner choroidal vasculature^[10]

IPCV is characterized by the presence of recurrent serosanguineous PEDs and neurosensory retinal detachments (NSRD). The vascular abnormality

underlying the disorder appears to be in the inner choroid. Dilated networks of vessels terminating in aneurysmal dilatations or "polyps" can be observed on ICG angiography. Polypoidal lesions can originate from various different region such as the peripapillary region, macula, or peripheral areas. On histopathological evaluation, various cases of IPCV showed extensive fibrovascular proliferation in the subretinal space and within Bruch's membrane, and a marked lymphocytic infiltration with both B and T cells. Although laser photocoagulation appears to be very effective in preserving visual acuity in patients with IPCV, but there are also chances of spontaneous resolution of PEDs and NSRDs to occur.

Case Report

A 32-year male presented with sudden deterioration of vision for **last two** months in left eye which was associated with mild ocular pain. His visual acuity in right eye was 6/6 and in left eye was 6/12 on Snellen's chart. On examination anterior segment was within normal limit. On dilated fundus examination with indirect ophthalmoscope and 78D slit lamp biomicroscopy, right eye was normal but in left eye diffuse soft confluent drusen in polypoidal pattern was present near macula with hard exudates and some calcified drusen present all over posterior pole which was gradually increasing. He denied any history of trauma but patient had history of typhoid for 4 times in last 3 months, but no other ocular complaints. Fundus photos were taken at presentation and then at 15 days interval, it shows gradual increase in size of lesions, which is associated with gradual diminution of vision up to 6/24 in 1 month duration.

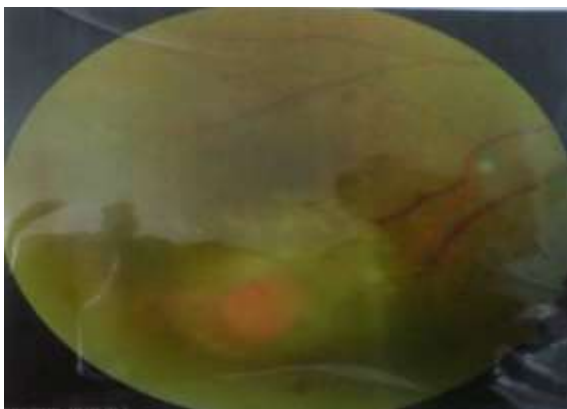


Fig. 1: Fundus photograph on day one showing orangish red lesion

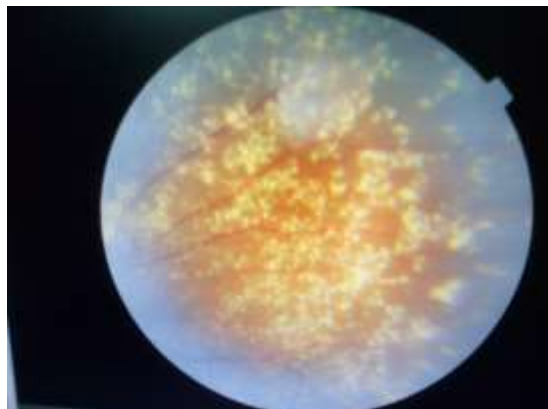


Fig. 4: Photograph of OCT showing hyperreflective polypoidal lesion seen to be extending in inner retinal layers damaging the bruch's membrane

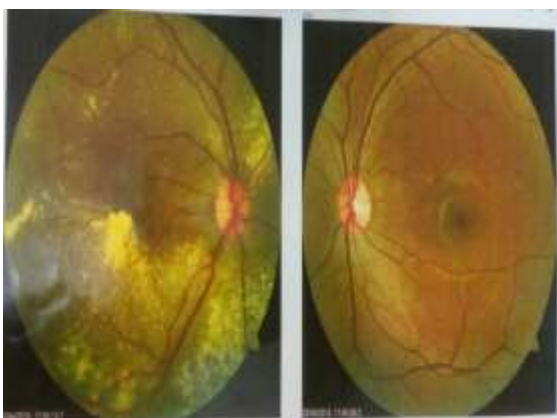

Fig. 2: Fundus photograph at 15th day, showing soft confluent established lesion near macula

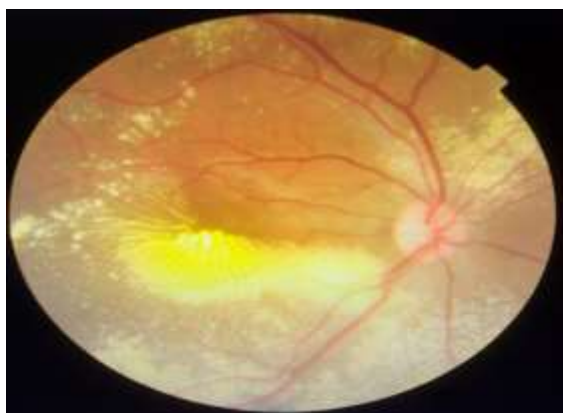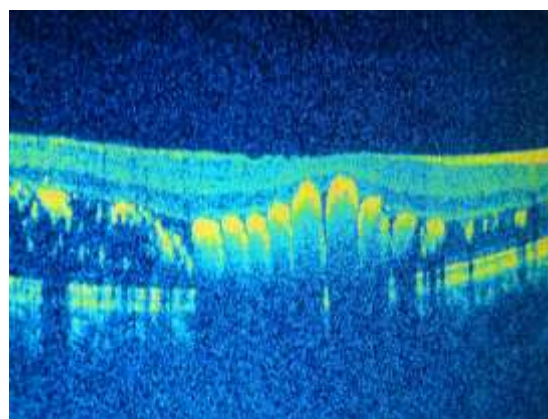

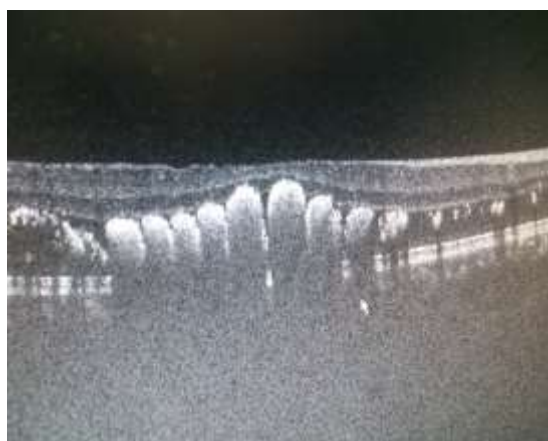
Fig. 3: Fundus photograph taken after one month interval shows gradual increase in confluent lesion. Calcified drusen like lesion present in periphery



Discussion

Polypoidal choroidal vasculopathy (PCV) is characterized by a network of branching inner choroidal vessels with terminal, polyp-like aneurysmal dilations.^[11] Ophthalmoscopically, they appear as multiple reddish-orange protrusions from the choroid into the subretinal space.^[12] This disease is prevalent in all races and in both sexes.^[13,15] The usual age of onset of polypoidal CNV is between 50 and 65 years with an average of 60.1 years.^[16 & 15] However, the age of

diagnosis is much younger and broader than seen with AMD.

The pathogenesis of PCV is still not clearly understood. In the past, microvascular disease processes such as hypertension and diabetes^[17-19] were thought to be the cause of PCV but after many extensive studies and research, the role of biochemical mediators of vasogenesis, like vascular endothelial growth factor (VEGF) etc. may be responsible for the neovascularization seen in PCV. Various reports have shown strong expression of VEGF in PCV specimens and also its up-regulation in the aqueous humor in eyes with PCV.^[20 & 21] Recent studies done, has also located a complement factor H gene with strong association with PCV as a probable factor leading to its development.^[22]

Interestingly, a common genetic link has also been found between PCV and AMD. Gotoh and associates located an ARMS2 (LOC387715) genetic variant in Japanese patients with strong associations with both exudative AMD and PCV.^[23] The abnormal vascular network in PCV is histopathologically in order with the short posterior ciliary arteries and therefore is thought to originate from its branches, which develop through defects in Bruch's membrane.^[24] OCT has recently been proven to be useful in the diagnosis of PCV. Polypoidal lesions appear as sharp dome-like elevations of the RPE with moderate inner reflectivity.^[25] In addition, a highly reflective line just below the mildly elevated and reflective RPE was often observed, consistent with the location of the vascular branching networks.^[26] Sato and associates called the dual reflective layers the **"double-layer sign"**, which they observed in 59% of eyes with PCV.^[26] PCV have a more favorable visual prognosis compared to that of exudative AMD. However, significant and permanent visual loss can occur with macular involvement of PCV.

Differential diagnoses include retinal telangiectasias, retinal macroaneurysms, valsalva retinopathy, and Purtscher's retinopathy when the appearance is primarily hemorrhagic. Other diseases mimicking PCV include inflammatory processes and conditions that predispose patients to the development of CNV, such as ocular histoplasmosis, angioid streaks, pathologic myopia, choroidal rupture, and choroidal tumors and hemangioma

Mainly the patients of PCV are kept on regular follow up and treatment of PCV lesions is only recommended when central vision is being threatened by persistent and progressive exudative changes.

Otherwise, a conservative approach is mostly recommended. Various treatment modalities like laser photocoagulation, transpupillary thermotherapy, photodynamic therapy with verteporfin (PDT), and surgery or intravitreal antiangiogenic drugs have been reported. However, only one randomized, controlled study has been performed to prove the efficacy and

safety of ranibizumab Vs PDT or PDT plus ranibizumab (the EVEREST trial).

Direct laser photocoagulation of leaking polyps has proven short-term safety and efficacy for extrafoveal lesions.

In conclusion, polypoidal choroidal vasculopathy seems to be a distinct clinical entity that should be differentiated from other types of choroidal neovascularization associated with age-related macular degeneration and other known choroidal degenerative, inflammatory, and ischemic disorders. Although PCV is more common in elderly people but possibility may be considered in younger age groups.

References

1. Yannuzzi LA. Idiopathic polypoidal choroidal vasculopathy. The Macula Society Meeting. Miami, USA, February 5, 1982.1982;1.
2. Kleiner RC, Brucker AJ, Johnston RL. The posterior uveal bleeding syndrome. *Retina* 1990;10(1):9-17.
3. Stern RM, Zakov ZN, Zegarra H, Gutman FA. Multiple recurrent serosanguineous retinal pigment epithelial detachments in black women. *Am J Ophthalmol* 1985;100(4):560-569.
4. Yannuzzi LA, Freund KB, Goldbaum M, et al. Polypoidal choroidal vasculopathy masquerading as central serous chorioretinopathy. *Ophthalmology* 2000;107:767-777.
5. Li H, Wen F, Wu D. Polypoidal choroidal vasculopathy in a patient with circumscribed choroidal hemangioma. *Retina* 2004;24:629-631.
6. Bartlett HM, Willoughby B, Mandava N. Idiopathic polypoidal choroidal vasculopathy in a patient with melanocytoma of the optic nerve. *Retina* 2001;21:396-399.
7. Mauget-Fajssse M, Cornut PL, Quaranta El-Maftouhi M, Leys A. Polypoidal choroidal vasculopathy in tilted disk syndrome and high myopia with staphyloma. *Am J Ophthalmol* 2006;142:970-975.
8. Fine HF, Ferrara DC, Ho I-V, et al. Bilateral choroidal osteomas with polypoidal choroidal vasculopathy. *Retin Cases Brief Rep* 2008;2:15-17.
9. Samira K, Engelbert, Michael E, Yutaka I, Freund, K. B. Polypoidal choroidal vasculopathy: Simultaneous Indocyanine Green Angiography and Eye-Tracked Spectral Domain Optical Coherence Tomography Findings. *Retina* 2012;32:1057.
10. Yannuzzi LA. Idiopathic polypoidal choroidal vasculopathy. Presented February 5, 1982 at the Macula Society Meeting, Miami, Florida.
11. McCleary CD, Guier CP, Dunbar MT. Polypoidal choroidal vasculopathy. *Optometry*. 2004 Dec;75(12):756-70.
12. Yannuzzi LA, Freund KB, Goldbaum M, et al. Polypoidal choroidal vasculopathy masquerading as central serous chorioretinopathy. *Ophthalmology*. 2000 Apr;107(4):767-77.
13. Yannuzzi LA, Ciardella A, Spaide RF, et al. The expanding clinical spectrum of idiopathic polypoidal choroidal vasculopathy. *Arch Ophthalmol* 1997;115:478-485.
14. Yannuzzi LA, Wong DWK, Storzolini BS, et al. Polypoidal choroidal vasculopathy and neovascularized age-related macular degeneration. *Arch Ophthalmol* 1999;117:1503-1510.

15. Ciardella AP, Donsoff IM, Huang SJ, et al. Polypoidal choroidal vasculopathy. *Surv Ophthalmol.* 2004 Jan-Feb;49(1):25-37.
16. Ciardella AP, Donsoff IM, Yannuzzi LA. Polypoidal choroidal vasculopathy. *Ophthalmol Clin North Am.* 2002 Dec;15(4):537-54.
17. Lip PL, Hope-Ross MW, Gibson JM. Idiopathic polypoidal choroidal vasculopathy: a disease with diverse clinical spectrum and systemic associations. *Eye.* 2000 Oct; 14 Pt 5:695-700.
18. Ross R, Gitter K, Cohen G, et al. Idiopathic polypoidal choroidal vasculopathy associated with retinal arterial macroaneurysm and hypertensive retinopathy. *Retina.* 1996;16:105-11.
19. Tong JP, Chan WM, Liu DT, et al. Aqueous humor levels of vascular endothelial growth factor and pigment epithelium-derived factor in polypoidal choroidal vasculopathy and choroidal neovascularization. *Am J Ophthalmol* 2006;141:456-462.
20. Matsuoka M, Ogata N, Otsuji T, et al. Expression of pigment epithelium growth factor and vascular endothelial growth factor in choroidal neovascular membranes and polypoidal choroidal vasculopathy. *Br J Ophthalmol* 2004;88:809-915.
21. Kondo N, Honda S, Kuno S, Negi A. Coding variant 162V in the complement factor H gene is strongly associated with polypoidal choroidal vasculopathy. *Ophthalmology* 2009 Feb;116:304-310.
22. Gotoh N, Nakanishi H, Hayashi H, et al. ARMS2 (LOC387715) variants in Japanese Patients with exudative age-related macular degeneration and polypoidal choroidal vasculopathy. *Am J Ophthalmol.* 2009 Jun;147(6):1037-41,1041.e1-2.
23. Moorthy RS, Lyon AT, Rabb MF, et al. Idiopathic polypoidal choroidal vasculopathy of the macula. *Ophthalmology* 1998 Aug;105:1380-5.
24. Kamaeda T, Tsujikawa A, Otani A, et al. Polypoidal choroidal vasculopathy examined with en face optical coherence tomography. *Clin Experiment Ophthalmol.* 2007 Sep-Oct;35(7):596-601.
25. Sato T, Kishi S, Watanabe G, et al. Tomographic features of branching vascular networks in polypoidal choroidal vasculopathy. *Retina.* 2007;27:589-594.