

Intraoperative bleeding during lacrimal sac surgery

Ratandeeep Kumar Agrawalla^{1*}, Jayashree Dora²

¹Junior Resident, ²Professor, Dept. of Ophthalmology, VIMSAR, Burla

*Corresponding Author:

Email: dratandipkumargrawala@gmail.com, prasadrakyat@yahoo.in

Abstract

Intraoperative blood loss is a problem in lacrimal sac surgery. In this prospective double blind study we compared the intraoperative blood loss in patients having preoperative tranexamic acid, ethamsylate, botropase and placebo (vitamin B complex). The patients treated with anyone of preoperative tranexamic acid, etamsylate, botropase have significantly lower intraoperative blood loss and less operating time as compared to the placebo group.

Key words: DCR –dacryocystorhinostomy, DCT – dacryocystectomy, NLDO – nasolacrimal duct obstruction

Introduction

Lacrimal sac surgery is one of common ophthalmic surgery practiced by both ophthalmologist and otorhinolaryngologists. Intraoperative bleeding during lacrimal sac surgery is may be from angular vein, soft tissue, periosteum, nutrient artery of bone, sac or may be while dissecting nasal mucosa, which causes inconvenience to the surgeons because the operating field is also very small.

Aim of the study

To compare the amount of intraoperative bleeding and operative time during lacrimal sac surgery in patients using

1. Tranexamic acid
2. Ethamsylate
3. Botropase
4. Placebo (B complex)

Inclusion criteria:

- Patients having chronic dacryocystitis due to NLDO

Exclusion criteria:

- Patients having bleeding disorders
- Patients on antiplatelete drugs and blood thinning agents
- Patients with diabetes mellitus
- Females who are menstruating

Type of study: prospective, interventional, double blind study.

Study duration: 6 months

Materials and Methods

56 patients with NLDO presented to our OPD were admitted for the lacrimal sac surgery (dacryocystorhinostomy or dacryocystectomy). The patients were advised for blood investigations like CBC, TLC, DLC, FBS, PPBS, HIV, HBsAg, HCV. To

rule out any bleeding disorder we ordered for BT and CT. The patients were operated 2 days after admission. The patients were divided into 4 groups.

Group 1- patients treated with tranexamic acid tablets 500 mg BD preoperatively

Group 2- patients treated with ethamsylate tab 250 mg BD preoperatively

Group 3- patients treated with botropase injection BD preoperatively

Group 4- patients treated with placebo (Vit B Complex) oral preoperatively

Patients with contraindications for dacryocystorhinostomy underwent dacryocystectomy. All the patients were operated under local anaesthesia with 2% lignocaine with adrenaline and 0.5% bupivacaine infiltrated at the sac area. The patients who underwent dacryocystorhinostomy were given nasal pack just prior to the operating procedure. The nasal packs were removed 24 hours after operation. The operating time was calculated by using watch from skin incision to skin closure. The intraoperative bleeding was calculated by the numbers of gauge pellets soaked (size of each pellet was standardized 2×2 cm) with blood postoperatively. The pellets were prepared after soaking the gauge in normal saline and squeezing.

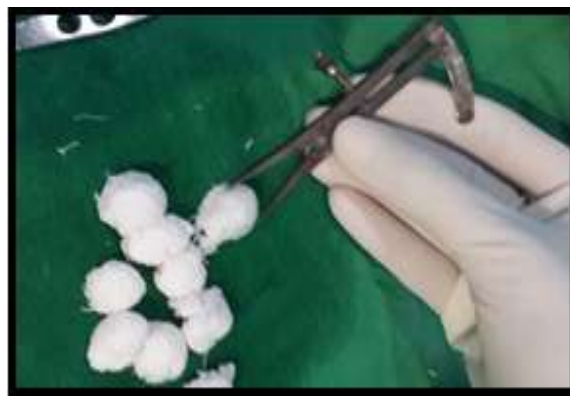

Fig. 1: Standardization of gauge pellets

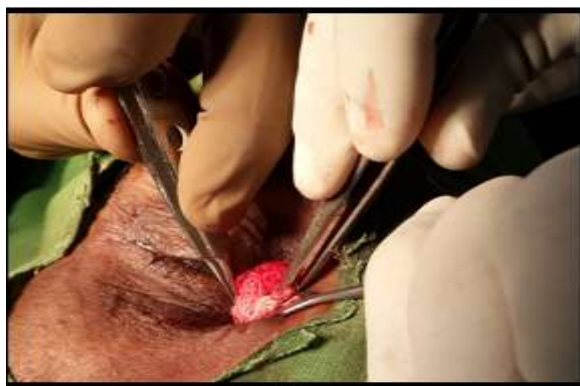

Fig. 2: Gauge pellets used intraoperative period to soak blood



Fig. 3: Blood soaked guage pellets

Observation

26 patients underwent dacryocystorhinostomy and 30 patient underwent dacryocystectomy. In every group

14 patients were allotted by random sampling. In this study mean age of the patients is 42 years. In our study population 34 patients were females and 22 patients were male.(F:M = 1.54) in group 1, 7 underwent DCR and 7 DCT. In group 2, 4 patients underwent DCR and 10 underwent DCT. In group 3, 7 underwent DCR and 7 underwent DCT. In group 4, 8 underwent DCR and 6 DCT. The mean time for DCR was 37 minutes and mean time for DCT was 20 minutes. The mean number of pellets soaked for DCR operation was 26 and for DCT was 12.

Group 1

- The mean operating time for dcr was 30 minutes and for dct it was 16 minutes.
- The mean number of pellets soaked for dcr was 22 and for dct was 9.

Group 2

- The mean operating time for dcr was 32 minutes and for dct it was 18 minutes.
- The mean number of pellets soaked for dcr was 24 and for dct was 11.

Group 3

- The mean operating time for dcr was 30 minutes and for dct it was 15 minutes.
- The mean number of pellets soaked for dcr was 20 and for dct was 10.

Group 4

- The mean operating time for dcr was 56 minutes and for dct it was 31 Minutes.
- The mean number of pellets soaked for dcr was 38 and for dct was 18.

Table 1

Group	No. of patients	Type of operation	Mean operating time in minutes	Mean no. of pellets soaked
Group 1	7	DCR	30	22
Group 2	4	DCR	32	24
Group 3	7	DCR	30	20
Group 4	8	DCR	56	38

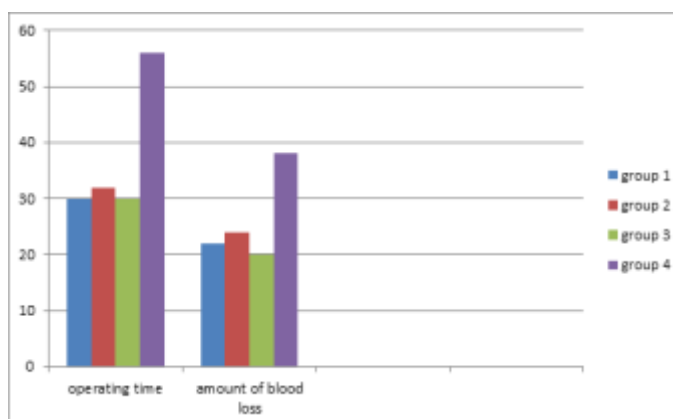


Table 2

Group	No. of patients	Type of operation	Mean operating time in minutes	Mean no. of pellets soaked
Group 1	7	DCT	16	9
Group 2	10	DCT	18	11
Group 3	7	DCT	15	10
Group 4	6	DCT	31	18

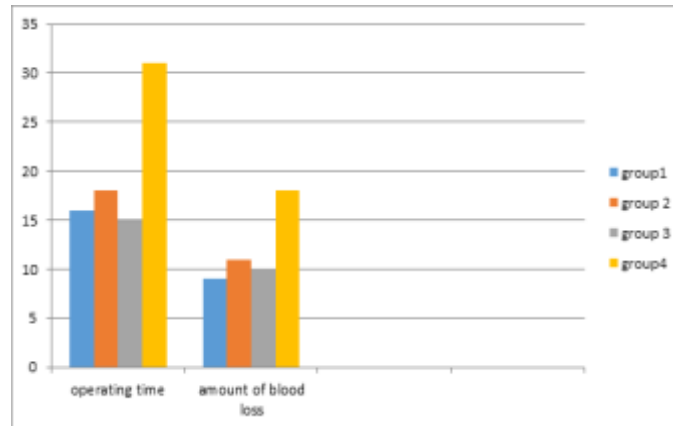


Table 3

Age group in years	No. of patients	Sex (F:M)	Laterality (L:R)
10 - 20	2	1:1	1:1
20 -30	6	2:1	1:1
30 -40	10	1.5:1	1.5:1
40 -50	18	2:1	1.25:1
50 – 60	12	1.4:1	1:1
60 – 70	8	2:1	1.67:1
total	56	1.54:1	1.24:1

Table 4

Age group in years	No. of patients underwent DCT	Nasal pathology
10 - 20	0	-
20 -30	2	Atrophic rhinitis, epistaxis
30 -40	7	Trauma to face, repeated epistaxis, deviated nasal septum
40 -50	8	Tuberculosis, epistaxis, contracted fibrosed sac
50 – 60	8	Contracted fibrosed sac, fistula, fracture maxilla
60 – 70	5	Contracted fibrosed sac, tuberculosis, fistula
total	30	

Conclusion

The patients treated preoperatively with tranexamic acid, ethamsylate, botropase have a marked reduction in operating time and bleeding (botropase >tranexamic acid >ethamsylate) as compared to the placebo.

Discussion

Chronic dacryocystitis is preferentially more common in adults over middle life from third to seventh decades^{8,9,10}.

In the present study, maximum number of cases belonged to the age group of 40-55 years (38.2%). The average mean age of our study was 42 years.

In our study mean age of presentation of dacryocystitis is 42 years. The female to male sex ratio is 1.54. Nlido is more common in middle aged and elderly females. It has been suggested that the menstrual and hormonal fluctuations and a heightened immune status as factors that may contribute to the disease process. These may explain the prevalence in the middle-aged and elderly females. Hormonal changes that bring about a generalized de-epithelisation in the body may cause the same within the lacrimal sac & duct¹². An already narrow lacrimal fossa in women predisposes them to obstruction by the sloughed off debris. Axial maxillo-facial ct scans showed women

having a smaller bony diameter at the level of lower fossa and middle naso lacrimal duct compared to men. The adult inferior bony fossa increased in size with age in both men and women, while middle naso-lacrimal duct increased in size in men only¹²

Tranexamic acid exerts its antifibrinolytic effect by reversibly blocking lysine binding sites on plasminogen, thus preventing plasmin from interacting with lysine residues on the fibrin polymer, causing subsequent fibrin degradation^{1,3}.

Ethamsylate is a haemostatic agent; also promotes angioprotective and proaggregant action. It stimulates thrombopoiesis and their release from bone marrow. Haemostatic action is due to activation of thromboplastin formation on damaged sites of small blood vessels and decrease of pgi₂ (prostacyclin 2) synthesis; it also facilitates platelet aggregation and adhesion, that at last induce decrease and stop of hemorrhage^{2,4}.

Botropase is a hemocoagulase preparation used to arrest bleeding of different etiology. It is an enzyme preparation with hemocoagulase activity which is attributable to the protein batroxobin. The enzyme clots pure fibrinogen like thrombin, releasing fibrinopeptide from a fibrinogen. The enzyme possesses all the typical characteristics of serine proteases and has a molecular weight of 27,000 da and its isoelectric point is around 7.5. Botropase is said to have actions like thrombin. However, there are many differences between the two agents. Botropase is both systemic and local hemocoagulant unlike thrombin. Botropase induced clot is not structurally similar to thrombin clot. Botropase is not absorbed by clot like thrombin. It appears that even in the absence of calcium, botropase can cleave the fibrinogen into fibrin. Antithrombin iii does not interfere with botropase hemocoagulant action^{5,6}.

References

1. Tranexamic acid in dacryocystorhinostomy – clinical trials. Gov, haemek medical center, Israel.
2. Step-by-step dacryocystorhinostomy for beginners: an expert's view Shrikant Deshpande, Anjaneya Agashe, Abhinav Loomba, Neha Dhiware department of ophthalmology, Mahatma Gandhi Mission Medical College, Navi Mumbai, Maharashtra, India.
3. Tranexamic acid for the treatment of heavy menstrual bleeding: efficacy and safety Henri Leminen and Ritva Hurskainen.
4. Mechanism of ethamsylate, Wikipedia.
5. Effects of botropase on clotting factors in healthy human Volunteers Ashok K. Shenoy, K. V. Ramesh, Mukta N. Chowta, Prabha M. Adhikari,¹ and U. P. Rathnakar (NCBI).
6. Dacryocystitis: systematic approach to diagnosis and therapy Sergio Pinar-Sueiro & Mercedes Sota & Telmo-xabier Lerchundi & Ane Gibelalde & Bárbara Berasategui & Begoña Vilar & Jose Luis Hernandez # Springer Science+Business media, llc 2012.
7. Kanski J J, Menon J. Clinical Ophthalmology. Philadelphia: butterworth- heinman, 5th edition 2003: pp:43-56.
8. Myren Yanoff, Jay S. Duker. The lacrimal drainage system, chapter- 98, in: ophthalmology, 2nd edn. Mosby publication. Pp.761-769.
9. Khurana AK, Khurana I. Conjunctiva, lacrimal apparatus and tear film. Chapter 10. In: anatomy and physiology of eye. 1st edition. New Delhi. Cbs publishers and distributors. 1998. Pp: 336-63.
10. Jones L J. An anatomical approach to problems of the eyelids and lacrimal apparatus. Archives ophthalmology. 1961;66:137-49.
11. Patel K, Magdum R, Sethia S, Lun A, Pradhan A, Misra RN. A clinico-bacteriological study of chronic dacryocystitis. Sudanese J ophthalmol. 2014;6(1):1-5.
12. McClean C J, Clee I A, Rose G E. Rhinostomies: an open and shut case? Br j ophthalmol. 1999;83:1300-1.
13. Baldeschi L, Nardi M, Hintschich C R, Koornneef L. Anterior suspended flaps: a modified approach to external dacryocystorhinostomy. Br J ophthalmol. 1998;82:790-2.
14. Ali M J, Naik M N, Honavar S G. External dacryocystorhinostomy: tips and tricks. Oman J ophthalmol. 2012;5(3):191-5.