

Presentation pattern and management outcome of ocular and periocular dermoid cyst

Rajendra P. Maurya^{1*}, Sashikant UC Patne², Virendra P. Singh³, Mahendra K. Singh⁴, Ritika⁵, Manisha Dwivedi⁶, Tanmay Srivastava⁷

¹Assistant Professor, ^{3,4}Professor, ^{5,6,7}Junior Resident, Dept. of Ophthalmology, ²Assistant Professor, Dept. of Pathology, IMS, Banaras Hindu University, Varanasi, Uttar Pradesh

***Corresponding Author:**

Email: mauryap_bhu@yahoo.com

Abstract

Purpose: To determine the pattern of clinical and radiological presentation and treatment outcomes of ocular and periocular dermoid cyst.

Materials and Methods: This prospective, international study was conducted in Unit of orbit, Ocular Oncology & Oculoplasty, Department of Ophthalmology, Institute of Medical Sciences, Banaras Hindu University from April 2014 to May 2016. Forty Six (46) patients with suspected dermoid cyst of the globe, orbit and periocular area were enrolled from outpatient department. Their detailed history, ocular examination, laboratory and radiological investigations were done. All lesions were confirmed on histopathological examination after surgical excision. The collected data was entered and analyzed by using SPSS version 13 software for mode of presentation, laterality, anatomical location & type of lesion, radiological finding and treatment outcome.

Results: 46 patients aged between 5 months and 31 years, underwent surgical excision of dermoid, out of which 20 (43.48%) were male and 26 (56.52%) were female. The maximum percentage of patients were in the age group 11-20 yrs. (45.65%) and 1-10 yrs. (39%). Dermoids were left sided in 30 (65.22%) cases and right sided in 16 (34.78%) cases. None of the cases had bilateral involvement. Most common type of dermoid were superficial orbital/periocular dermoid (21, 45.65%) followed by deep orbital dermoid (12, 26.09%) and limbal dermoid (10, 21.74%). However in 3 (6.52%) cases primary conjunctival dermoid was excised. Out of 10 cases of limbal dermoid, two were associated with Goldenhar's syndrome and one case was associated with eyelid coloboma.

In all 10 cases, limbal dermoid was seen in infero-temporal quadrant with larger portion of mass involving cornea without involving visual axis. Superficial orbital/periocular dermoid cyst were mostly located at superotemporal and superonasal area. However deep/intra orbital dermoid were equally located in superonasal and inferonasal orbit. In 32.6% cases CT scan revealed remodeling/scalloping of underlying orbital bone. None of the cases had features of intracranial extension and dumbbell shaped lesion. Majority of patients were asymptomatic, common presentation was palpable mass lesion. However in 17.39% cases nonaxial proptosis was observed. All patients underwent surgical excision. In 5 cases, these was rupture of capsule while dissecting them from periosteum. Recurrence was observed in two cases.

Conclusion: Dermoid cysts are commonest orbital periocular masses in childhood and typically present in superotemporal or superonasal location. Limbal dermoid are typically located at inferotemporal quadrant. Orbital dermoid should be investigated for localization and to assess the bony defects or intraorbital and intracranial extension. Orbital dermoid should be removed carefully and completely with minimum trauma in order to prevent rupture/recurrence. Always choose appropriate surgical incision for good functional & cosmetic effect.

Key Words: Choristomas, Dermoid cyst, Dumb bell-dermoid, Limbaldermoid.

Introduction

Dermoid cysts are most common benign lesions of the orbit in childhood.^[1] It accounts for about 40% of the orbital lesions in children and 89% of all pediatric orbital cysts.^[2] They are true ectodermal inclusion cysts found along the embryonic lines of closure and fusion. Dermoid cysts are lined by keratinized stratified squamous epithelium and unlike epidermal cyst, contain dermal appendages like hair follicles (Fig. 1), sweat glands and sebaceous glands.^[3] Orbital dermoids can be superficial to the orbital septum or lie deep inside the orbit, posterior to orbital septum.^[4] Most commonly, periocular dermoids are located along the zygomatico-frontal suture, at the lateral orbital wall followed by frontoethmoidal/nasofrontal suture at the medial orbital wall.^[5] Other locations of ocular dermoids are deep orbital cavity, limbus and conjunctiva.

They usually present as well defined, slow growing, painless lesions with local mass effect on globe, optic nerve and surrounding bones and leading to abnormal extra ocular movements, non axial proptosis, visual impairment and erosion/remodeling of underlying bones. Computerized tomography is the diagnostic modality of choice. It helps to determine bony changes/defects and intracranial or intra orbital extension of cyst. Successful management of orbital dermoids require complete surgical excision of the cyst with intact wall through an incision over the mass or lid crease incision.

Materials and Methods

A Two year prospective, interventional study was carried out in Unit of Orbit, Ocular Oncology and Oculoplasty, Department of Ophthalmology, Institute of Medical Sciences, Banaras Hindu University, Varanasi

from April 2014 to May 2016. This study was conducted to understand the disease pattern of ocular and periocular dermoid cyst regarding its clinical presentation, radiological features and treatment outcome. The patients were selected from the eye department. Some patients were referred from Pediatric and ENT department. They were admitted in the eye ward for detailed workup and surgical treatment. The initial evaluation of patients included detailed history, complete ophthalmological examination, laboratory and radiological investigations like orbital USG and CT scan/MRI. A preoperative photograph was taken. Later surgery was planned. All lesions were confirmed on histopathology after surgical excision. Limbal dermoids were shaved off with or without partial keratectomy and conjunctival autografting. Superficial dermoid cyst were excised via transcutaneous incision over cyst while deep orbital dermoids were removed through transcutaneous anterior orbitotomy approach. Patients were regularly followed up for six months to observe any recurrence. Data was collected and analyzed by using SPSS version 17 software for mode of presentation, age, gender, laterality, anatomical location, radiological effects and type of lesions.

Results

46 patients aged 5 months to 31 years underwent surgical excision of dermoid, out of which 20 (43.48%) were male and 26 (56.52%) were female [Table 1]. The maximum percentage of patients were in the age group

11-20 yrs (45.65%) and 1-10 yrs (39%). Dermoids were left sided in 30 (65.22%) cases and right sided in 16 (34.78%) cases. None of the cases had bilateral involvement. Most common type of dermoid was superficial orbital/periocular dermoid (21, 45.65%) followed by deep orbital dermoid (12, 26.09%) and limbal dermoid (10, 21.74%) [Fig. 2 & 3]. However in 3 (6.52%) cases primary conjunctival dermoid was excised [Fig. 4] [Table 2]. Out of 10 cases of limbal dermoid, two were associated with Goldenhar's syndrome and one case was associated with eyelid coloboma.

In all 10 cases, limbal dermoid was seen in inferotemporal quadrant with larger portion of mass involving cornea without involving visual axis. Superficial orbital/periocular dermoid cyst were mostly located at superotemporal and superonasal area [Fig. 5-10]. However deep/intraorbital dermoid [Fig. 11 & 12] were equally located in superonasal and inferonasal orbit [Table 3]. In 32.6% cases CT scan revealed remodeling/scalloping of underlying orbital bone [Fig. 11]. None of the cases had features of intracranial extension and dumb bell shaped lesion. Majority of patients were asymptomatic. Common presentation was palpable mass lesion. However, in 17.39% cases nonaxial proptosis was observed. All patients underwent surgical excision. In 5 cases, there was rupture of capsule while dissecting them from periosteum. Recurrence was observed in two cases [Table 4].

Table 1: Age and Sex wise distribution of cases

Age (years)	Male		Female		Total	
	No.	(%)	No.	(%)	No.	(%)
<1 – 10	8	17.39	10	21.74	18	39.13
11 – 20	9	19.57	12	26.09	21	45.65
21 – 30	2	4.35	3	6.52	5	10.87
>30	1	2.17	1	2.17	2	4.35
Total	20	100.00%	26	100.00%	46	100.00%

Table 2: Distribution according to type and laterality

Anatomical site	Eye involved		No.	(%)
	RE	LE		
Limbal	4	6	10	21.74
Conjunctival	1	2	3	6.52
Orbital Deep	8	4	12	26.09
Superficial	12	9	21	45.65
Total	25	21	46	100.00

Table 3: Location of Dermoid

Location	No.	(%)
Inferotemporal	12	26.09
Superotemporal	15	32.61
Superonasal	14	30.43
Inferonasal	5	10.87

Table 4: Post Complication in Orbited Demand

Complications	No.	(%)
Diminution of vision	3	6.52
Ptosis	2	4.35
Rupture	5	10.87
Postoperative infection	2	4.35
Recurrence	2	4.35

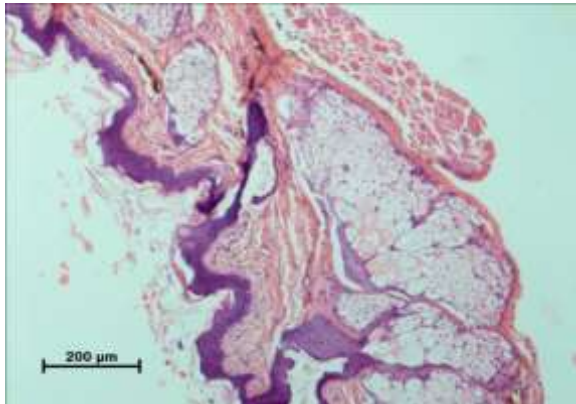
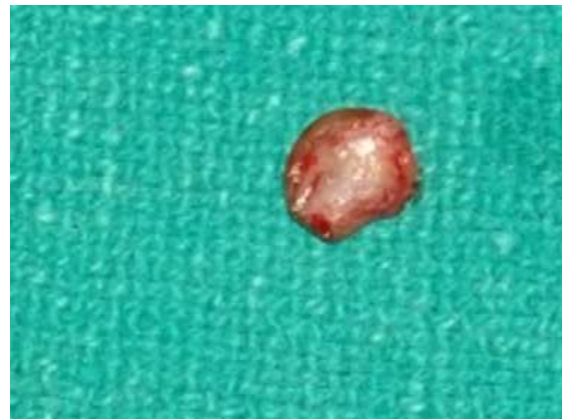
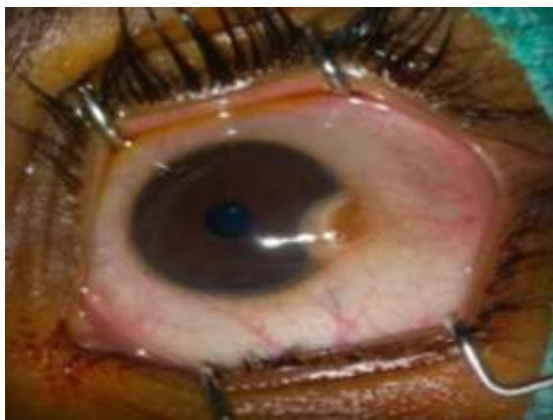
Fig. 1: Microphotograph showing stratified squamous epithelium line cyst with underlying sebaceous glands and skeletal muscle bundles (Hematoxylin and eosin stain; X100)

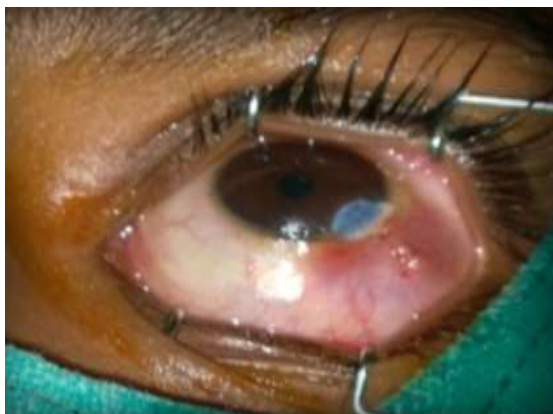

2C

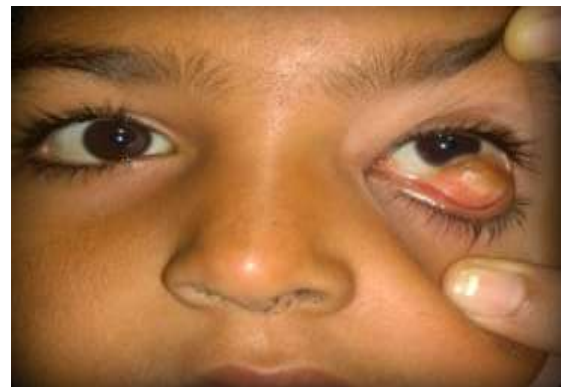Fig. 2: Inferotemporal Limbal Dermoid (A) Post operative photograph (B) and Gross specimen (C)



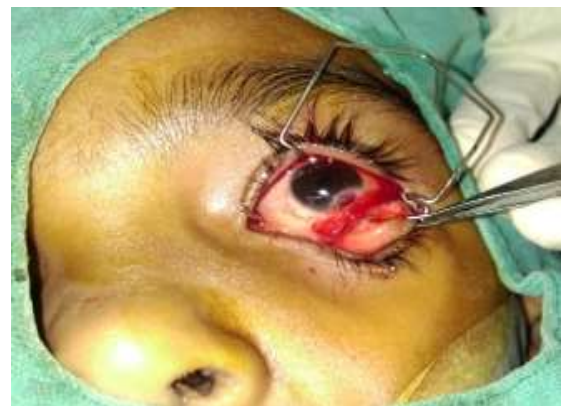2A



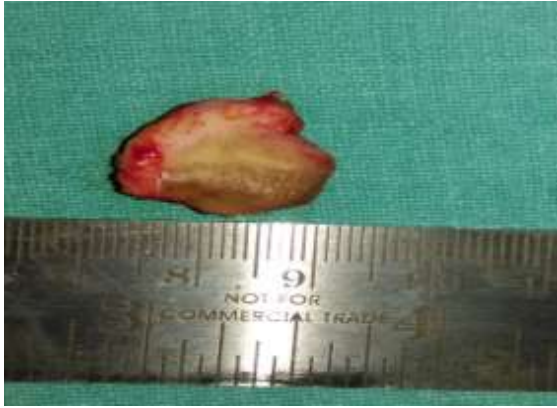2B



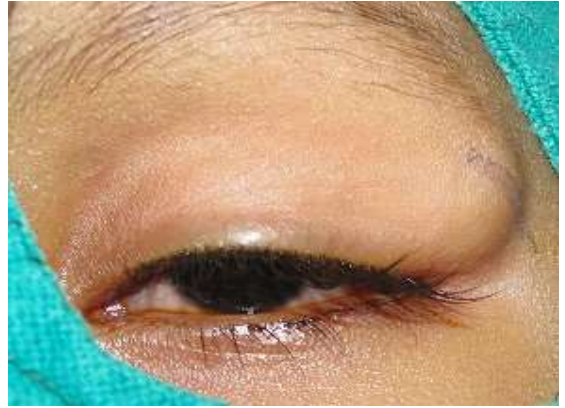3A



3B

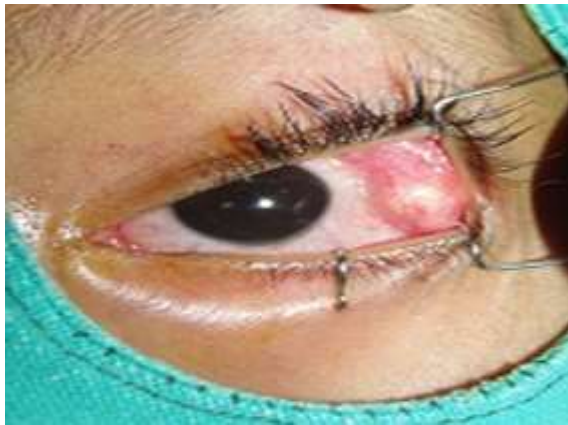

3C

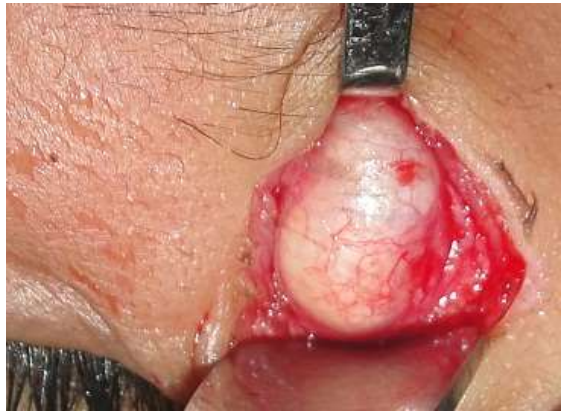

5A

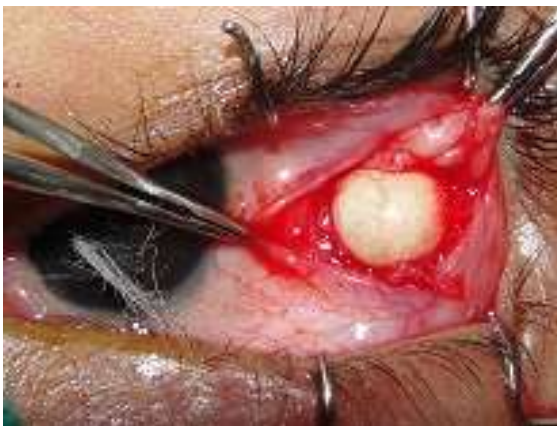Fig. 3: Large Inferotemporal Conjunctival Dermoid (A) An Intraoperative photograph of the patient(B) and Gross specimen (C)



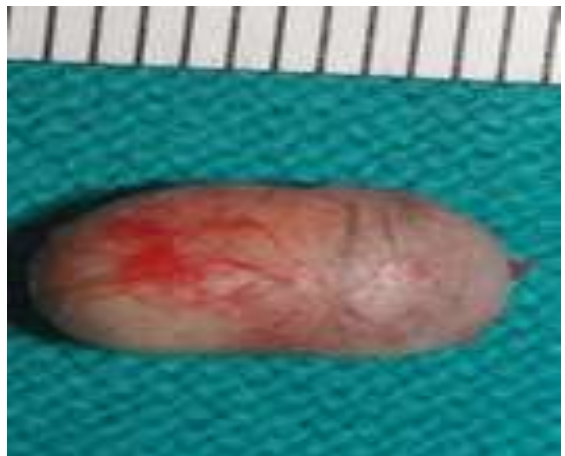4A



5B

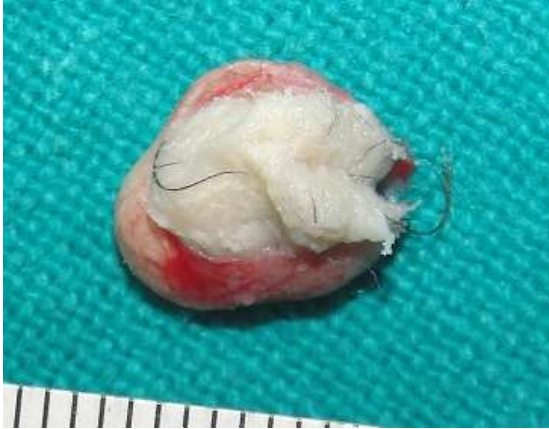

4B



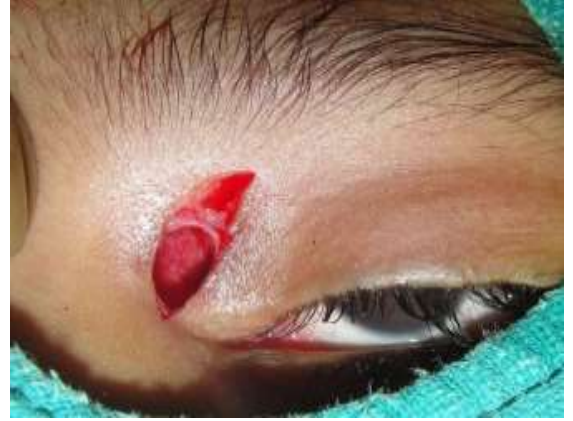5C

Fig. 4: Temporal conjunctival dermoid cyst with expansion into lateral bony wall (A) Transconjunctival lateral orbitotomy facilitates access to dermoid cyst(B)

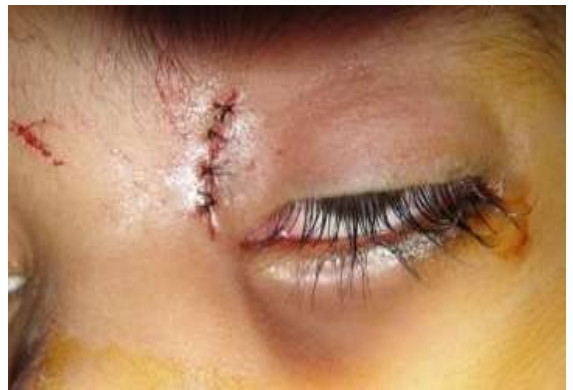

5D

Fig. 5: 3-year –old girl with dermoid cyst at her superotemporal area of left upper eyelid causing mild mechanical ptosis (A). Cyst was removed in toto through transcutaneous incision over cyst (B & C). Gross specimen of Cyst showing pilosebaceous secretion are depicted (D)

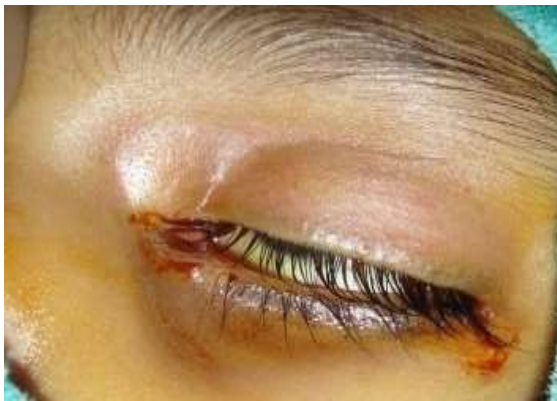

6C

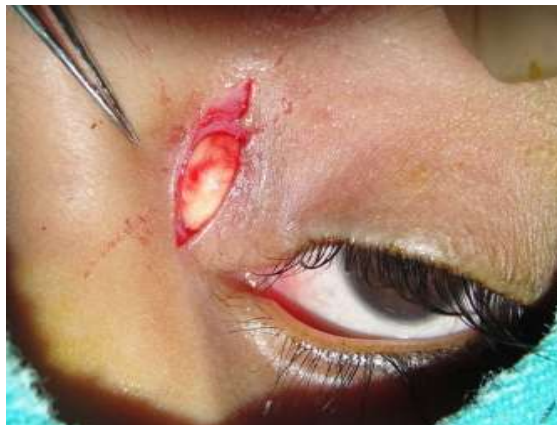

6D

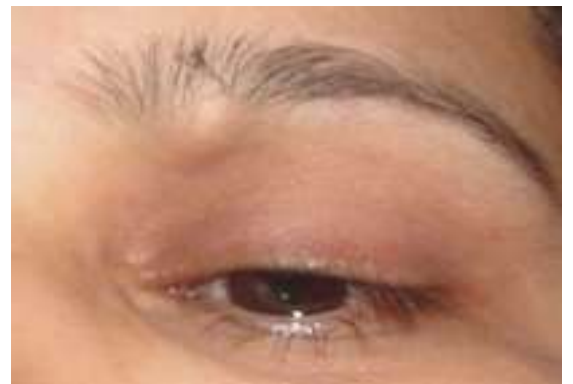Fig. 6: 6 year-old boy with left eye superiomedial, superficial dermoid cyst (A) Transcutaneous medial orbitotomy, incision over cyst showing cystic lesion of whitish color(B). After excision showing fossa (C), immediate post-operative photograph



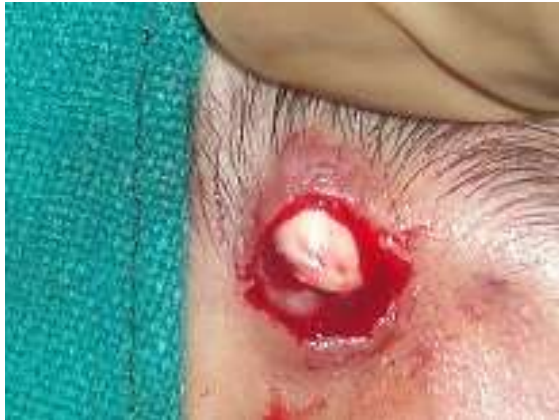6A



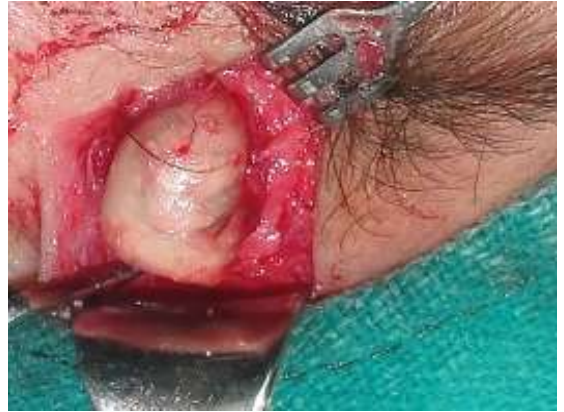6B



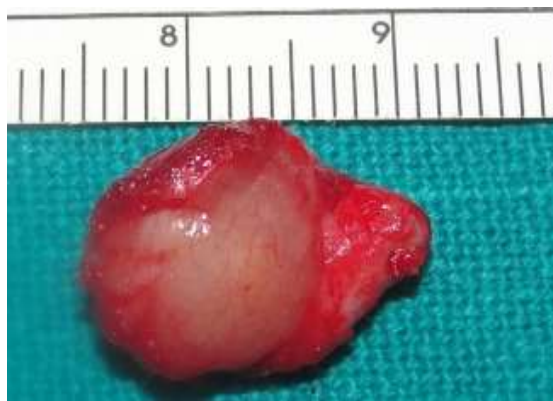7A



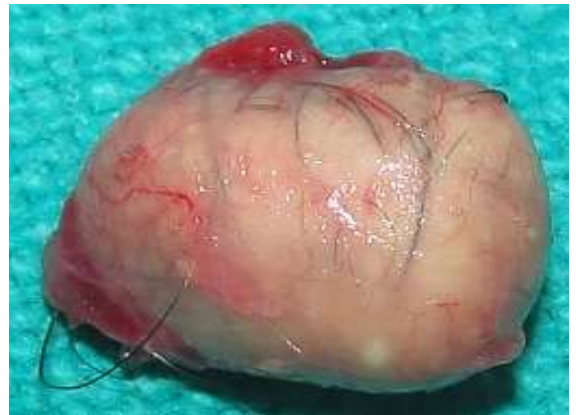7B



8B

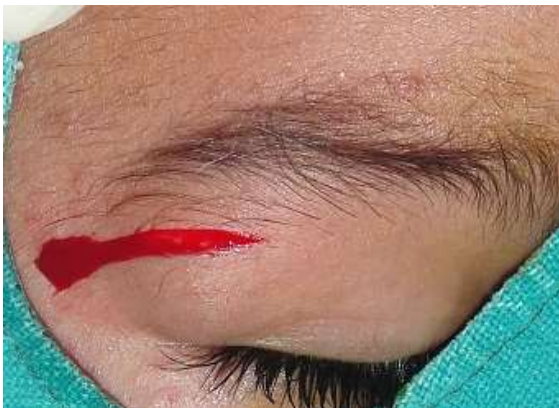

7C

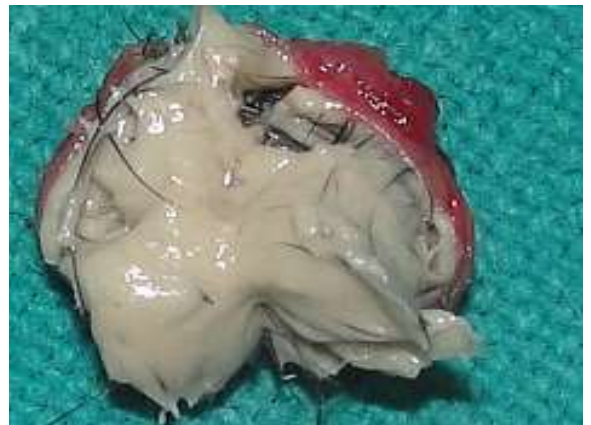

8C

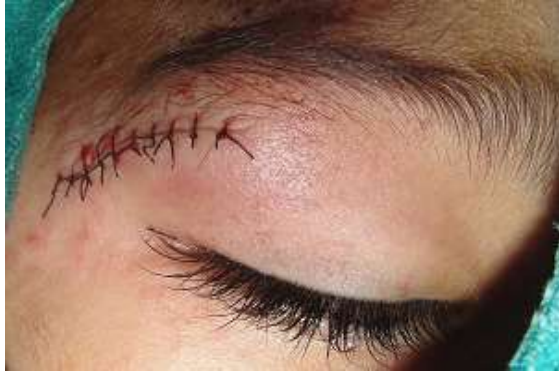Fig. 7: Superficial periocular dermoid at left medial eyebrow (A), Intraoperative photograph showing white cystic lesion (B) Cyst was completely excised (C)



8A

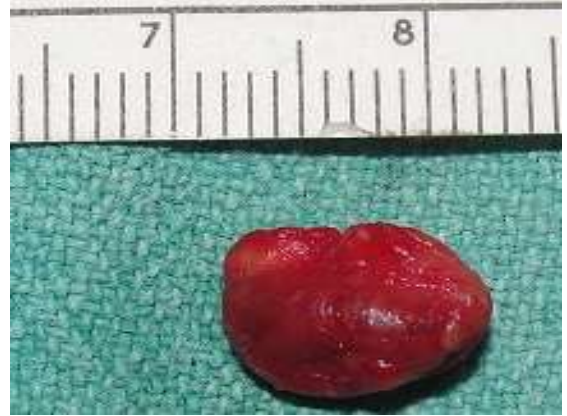

8D

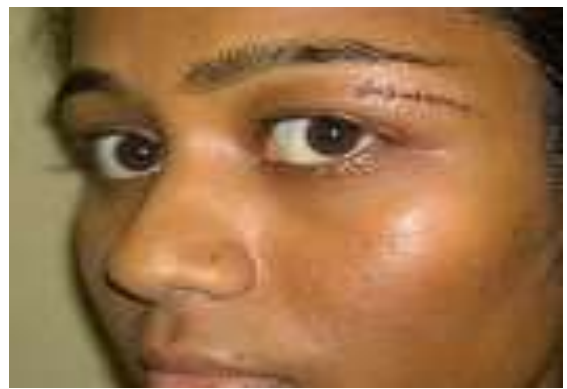

8E

Fig. 8: Dermoid cyst at the temporal portion of the right upper eyelid in 30 year female (A) skin incision over cyst, (B) an intraoperative photograph showing cystic lesion firmly adherent to the underlying tarsus, (C) Completely excised cyst showing hair through the intact capsule (D) cut section of grass specimen showing pilosebaceous material with hair (E) immediate post-operative photograph of the patient

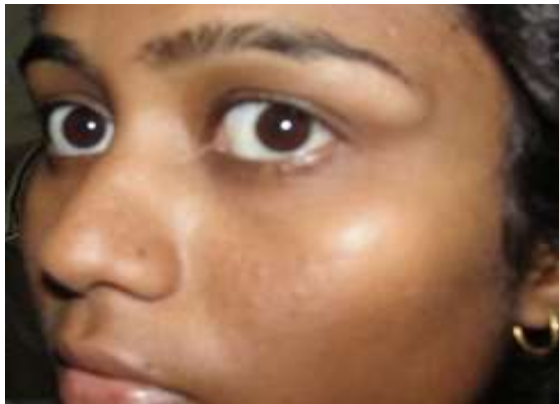

9C

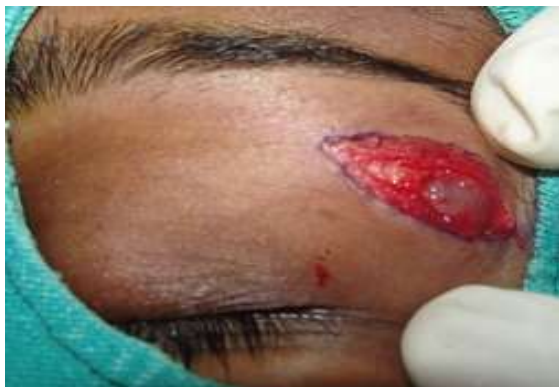

9D

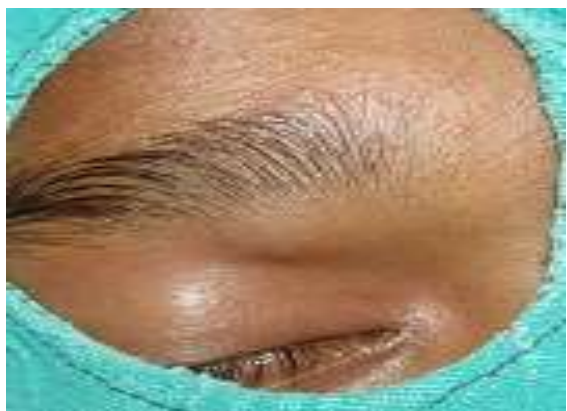Fig. 9: (A) 20-year –old girl with superfecialdermoid cyst at her superotemporal area of left upper eyelid. Cyst was accessed by incision over cyst (B) and removed into (C) immediate post-operative photograph (D)



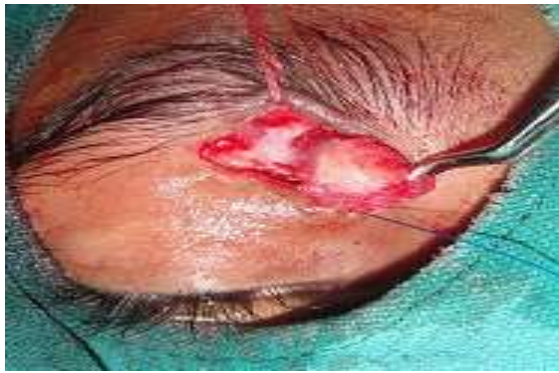9A



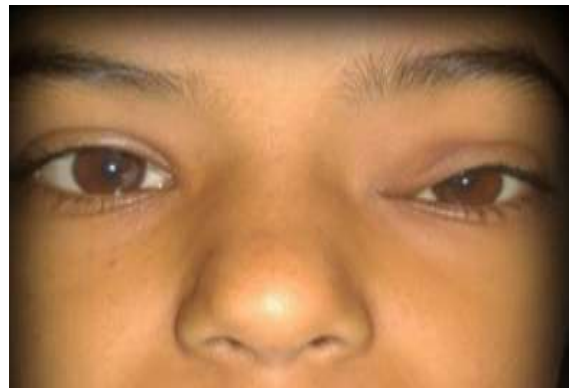9B



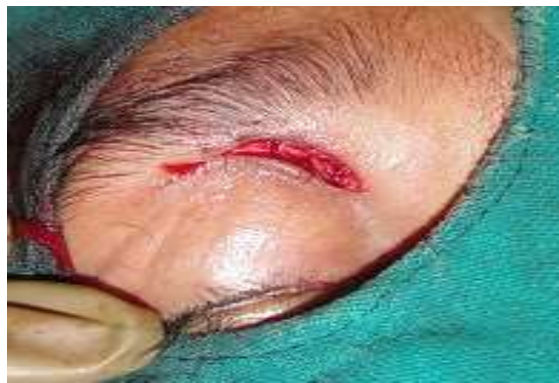10A



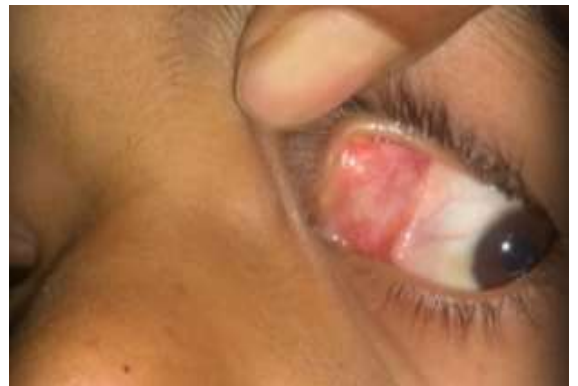10B



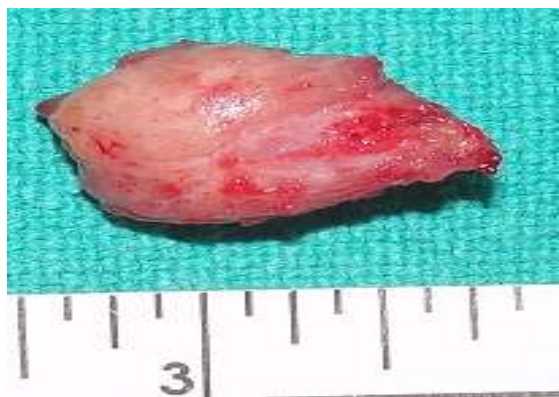11A



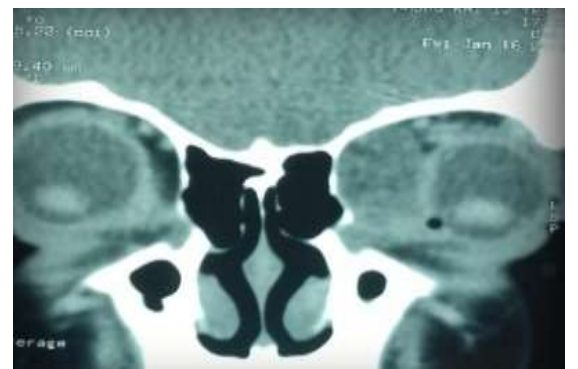
10C



11B



10D

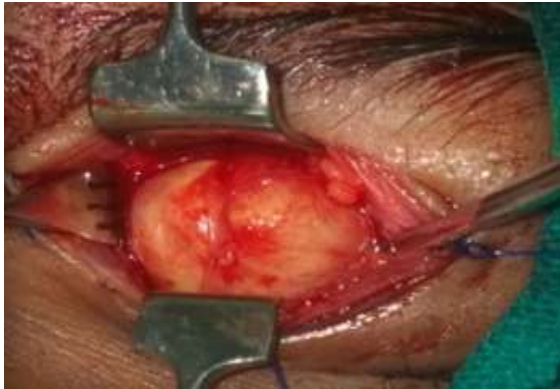

11C

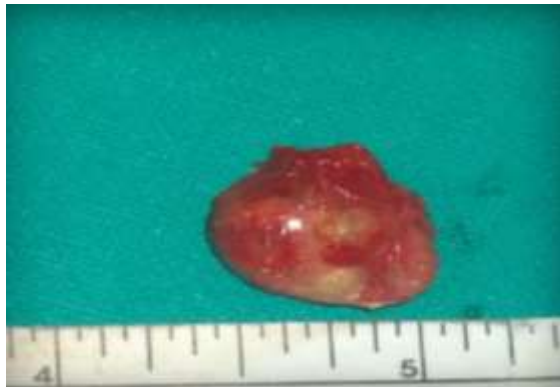

11D

Fig. 10: 6 year-old Girl with supero-medial, superficial dermoid cyst (A) Transcutaneous medial orbitotomy, subciliary incision over cyst showing cystic lesion of whitish color adherent to superomedial orbital rim(B). After excision wound closed in two layer (C) Gross specimen with intact wall

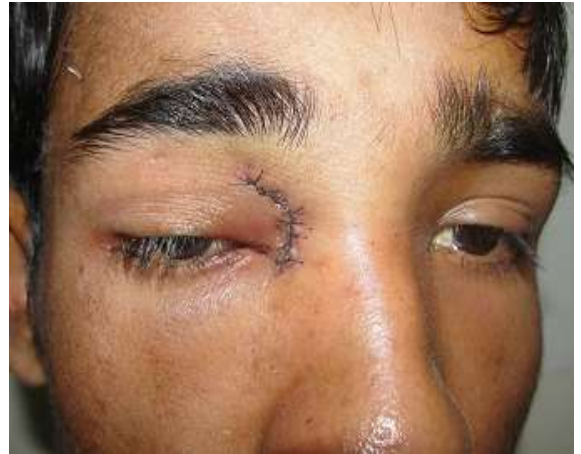

11E

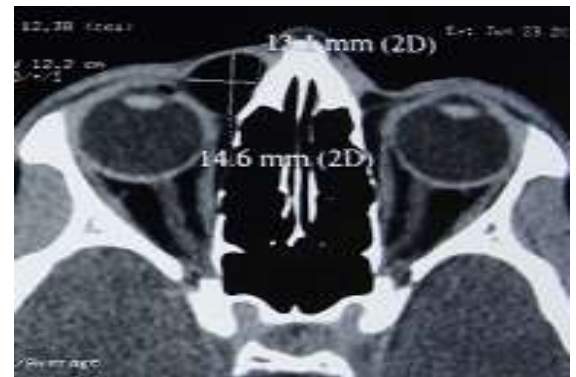

11F

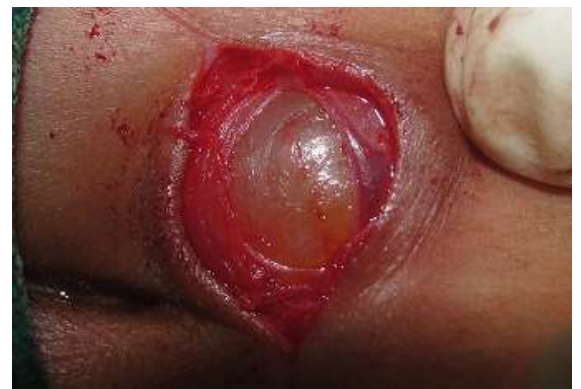Fig. 11: Typical Supero-medial deep orbital dermoid cyst in a 13 year old Girl showing non axial proptosis, mechanical ptosis (A) and trans-conjunctival swelling (B) CT Scan Coronal view showing oval hypodense cystic lesion which pushed left eyeball temporally (C) Sagittal view showing remodelling of roof of orbit (D). Cyst was accessed by transcutaneous supero-medial orbitotomy (E) and removed with intact wall (F)



12B

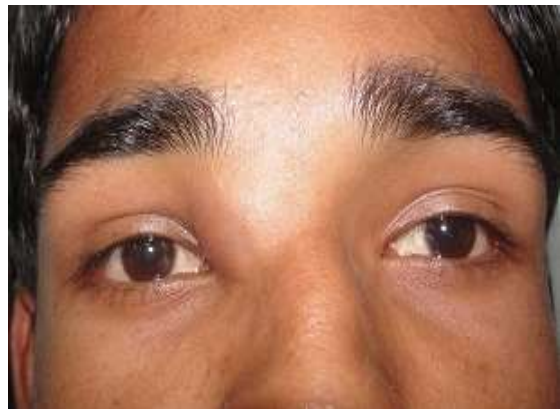

12C



12D

Fig. 12: Dermoid cyst at right medial angle with mild globe displacement , in a 13-year-old boy (A) Axial CT scan showing well- encapsulated, oval lesion at the right medial angle (-80 and -90 NHU, Fatty density) (B) Medial orbitotomy through lid crease showing whitish-yellow color cystic lesion (C). Immediate post-operative photograph (D)



12A

Discussion

Dermoid cysts are congenital and developmental choristoma, as tumor composed of ectopic tissues. Dermoid cysts are formed due to invagination and sequestration of embryonal surface ectoderm, adjacent to cranial sutures. Although orbital dermoid are most

frequent in infancy but they can appear at any age due to their slow growing nature. Grove (1981)^[5] classified dermoid cyst into superficial and deep dermoid. Superficial dermoid cyst appears during 1st and 2nd decade of life, commonly seen in temporal region. Deep dermoids are slow growing, usually appearing during 2nd to 4th decade of life.

Most of the dermoid cysts are unilateral but bilateral cases have also been reported.^[6] Bilateral Limbal dermoids are features of Goldenhar's syndrome. Limbal dermoids are mostly solid, superficial and commonly present at the infero-temporal limbus.^[6,7] In our study 21.74% patients had limbal dermoid, all were superficial and at inferotemporal location.

Conjunctival dermoid may present, as a part of limbal dermoid or as an extension of superficial dermoid. We observe three cases of primary conjunctival dermoid cyst and they were completely excised (Fig. 4). In our study maximum patients had superficial dermoid, lying subcutaneously, anterior to orbital septum, most commonly in superotemporal location. The children usually presented with slow growing well circumscribed, freely mobile, firm or cystic masses. Most of the periocular dermoid are asymptomatic but sometimes patient may present as orbital cellulites due to cyst rupture, either spontaneously or following blunt trauma, causing inflammatory foreign body reaction.^[2,8] Intra orbital dermoids are rare, constituting 5-10% of all orbital dermoid cases.⁽⁹⁻¹¹⁾

Deep dermoid cysts are slow growing and sometime remain clinically occult. The large intraorbital dermoid may present as proptosis, globe displacement and diplopia. They can extend into frontal sinus or intracranial cavity^[12], rarely extension through lateral orbital wall along the frontal zygomatic suture may produce a dumbbell shaped lesion^[13]. Ruszkowski found only one dumbbell dermoid in his series of 65 cases^[14]. Occasionally deep dermoid is present as an acute inflammation due to leakage of keratin^[2] or secondary fistula^[15]. Surgical removal of deep orbital dermoid is more difficult than superficial/periorbital one. Surgical approach depends on location/position of the cyst. Most common complication is intraoperative rupture & incomplete excision leading to recurrence. In our study, 5 cases had intra operative rupture and recurrence was seen in two cases. Before surgical excision, dermoid cyst should be differentiated from others pediatric orbital swellings like dacryocoele, mucocoele, dacryoadenitis, orbital abscess and hemangioma. CT scan orbit is the preferred modality of imaging. It demonstrates the size, shape, location and extension of the cyst. The cyst contents may be isodense, hypodense or heterogeneous, depending on the presence of keratin, having positive radiological density or negatively dense pilosebaceous materials. CT Scan also reveals bony changes like bone erosion, bone sclerosis and scaloping or fossa formation^[16]. Cavazza S et al reported in his study that commonest location of orbital dermoid are along the

zygomaticofrontal suture (86.6%) and nasofrontal suture (10%)^[5]. Chamda SJ et al (1999) in his review of 160 CT Scan studies of orbital dermoid observed that 65% were located temporally and 30% nasal to the globe and in one case dermoid had retrobulbar location^[17]. In our study also >75% dermoid were on temporal location. However Sherman et al found equal number of medial and lateral dermoid in there study^[18].

Conclusion

Dermoid cysts are the commonest orbital periorbital masses among childhood, typically present in superotemporal or superonasal location. Limbal dermoid are typically located at inferotemporal quadrant. Orbital dermoid should be investigated for localization and to assess the bony defects or intraorbital and intracranial extension. Early diagnosis and treatment of orbital dermoid is advocated, as delay may lead to increase in size and chance of rupture and other complications. Orbital dermoid should be removed carefully and completely, with minimum trauma in order to prevent rupture/recurrence. It is advanced to always choose appropriate surgical incision for good functional & cosmetic effect.

References

1. Kersten RC. The eyelid crease approach to superficial lateral dermoid cysts. *J. Pediatr. Ophthalmol Strabismus.* 1988;25(1):48-51.
2. Shields JA, Shields CL. Orbital cysts of childhood – classification, clinical features, and management. *Such ophthalmol* 204;49(3),281-299.
3. Pryor SG, Levuis JE, Weaveu AL, orvidas(). *Pediatric dermoid cyst of the head and neck. Otolaryngol Head Neck Surg* 2005;32(6):938-942.
4. Erave AS *Orbital disorders: diagnosis and Management in oculoplastic survey: New York, Raven Press, pp. 274-277, 1981.*
5. Cavazza S, Laffi GL, Lodi L, Gasparrini E, Tassinari E. Orbital dermoid cyst of Childhood : Clinical, Pathologic Findings, classification and Management. *Inf. Ophthalmol* 201;31(2):93-97.
6. Yanoff. M., Duker JS. *Ophthalmology. Second Edition, Mosby: Sf Louis 2004;397-740.*
7. Nadeem S, Raza A. Presentation of ocular and orbital dermoid cyst at Holy family hospital Rawalpindi. *Pak J Ophthalmol*, 2012;28(2):95-98.
8. Kudo K, TSU Tsumi S, Suga Y et al. orbital dermoid cyst with intratemoral inflammataghaemarhae. *Neoral med Chir (Tokyo)* 208;48,359-62.
9. Chawada SJ, Moseley If. Computed tomography of orbital dermoids: a 20 years review. *Chin Radiol* 1999;54:821-5.
10. Bouguila H, Malik I, Nacef L, Marrakchi S, Day Foos F, Ayed S. Intraorbital dermoid cyst. A propos of a case. *J. Fr. Ophthalmol* 1999;22:438-41.
11. El Afrit MA, Trojet S, Kammaun H, Sdiri N, Abid B.S., Brondhane F, Kraiem A: Dermoid cysts: Epidemiological, clinical and pathorogical studies. *J. Fr. Ophthotual* 2003;26:618-21.
12. Atik B, Tan O, Kaya Z, Kiroglu A F. Minimal invasive excision of intraorbital dermoid cyst. *Eur J Gen Med* 2007;4(2):87-90.

13. L Chen. The dumbbell orbital dermoid. *Chung Hua Yen Kotsa Chih* 1991;27:98-100.
14. Ruszkowski A, Caouette-Laberge L, Bortoluzzi P, Egerszegi EP. Superior eyelid incision: an alternative approach for frontozygomaticdermoid cyst excision. *Ann Plast Surg* 2000;44:591-4.
15. ZF Pollard, J Calhoun. Deep orbital dermoid with draining sinus. *Am J Ophthalmol* 1975;79:310-3.
16. Rath A, Subudhi BNR, Panda P, Panda S. Dermoid cyst situated in and around the eye ball. *Trans Med J*;1(3):90-92.
17. Chawda SJ, Moseley IF, Computed tomography of orbital dermoids; A 20 year review. *ClinRadiol* 1999;54:821-5.
18. Sherman RP, Rootman J, La Pointe JS. Orbital dermoids: Clinical presentation and management. *Br J Ophthalmol* 1984;68:642-52.