

Content available at: <https://www.ipinnovative.com/open-access-journals>

IP International Journal of Ocular Oncology and Oculoplasty

Journal homepage: <https://ijooo.org/>

## Case Report

# Rehabilitation of patient with unilateral congenital anophthalmia using custom ocular prosthesis

Raj Chandrakant Salvi<sup>1\*</sup>, Manish Chauhan<sup>1</sup>, Jyoti Tembhurne<sup>1</sup>, Arti Gangurde<sup>1</sup>,  
Niraja Jaiswal<sup>1</sup>, Pradnya Salian<sup>1</sup>

<sup>1</sup>Government Dental College and Hospital, Mumbai, Maharashtra, India



### ARTICLE INFO

#### Article history:

Received 14-06-2024

Accepted 29-06-2024

Available online 27-08-2024

#### Keywords:

Congenital anophthalmia

Custom ocular prosthesis

Tooth coloured acrylic

### ABSTRACT

**Background:** This case report aims to detail the fabrication and implementation of a custom ocular prosthesis for a patient with unilateral congenital anophthalmia. This study highlights the innovative approach, the procedures undertaken, and the significant outcomes achieved.

**Case Report:** A detailed assessment of the patient's anophthalmic socket was conducted. A custom impression technique was used to fabricate the prosthesis, ensuring optimal fit and aesthetic appearance. The process included impression making, customized prosthesis design, and fitting sessions.

**Results:** The custom ocular prosthesis achieved excellent aesthetic integration, restoring facial symmetry and enhancing the patient's appearance. Follow-up assessments showed satisfactory prosthesis retention, minimal discomfort, and positive psychosocial impacts, including improved self-esteem and social interactions.

**Conclusion:** This case underscores the importance of individualized prosthetic solutions in managing congenital unilateral anophthalmia.

This is an Open Access (OA) journal, and articles are distributed under the terms of the [Creative Commons Attribution-NonCommercial-ShareAlike 4.0 License](https://creativecommons.org/licenses/by-nc-sa/4.0/), which allows others to remix, tweak, and build upon the work non-commercially, as long as appropriate credit is given and the new creations are licensed under the identical terms.

For reprints contact: [reprint@ipinnovative.com](mailto:reprint@ipinnovative.com)

## 1. Introduction

Congenital anophthalmia, characterized by the complete absence of ocular tissue within the orbit, is a rare but significant congenital anomaly. It presents not only a cosmetic challenge but also impacts the psychological and social well-being of affected individuals.<sup>1,2</sup> Managing congenital anophthalmia involves multidisciplinary approach, aiming to restore facial symmetry, promote orbital growth, and provide psychosocial benefits to the patient.<sup>3</sup>

The traditional treatment for congenital anophthalmia begins with the use of conformers to stimulate orbital growth and prepare the socket for a prosthetic eye. Conformers are progressively larger devices that help in

expanding the orbital cavity, ensuring that there is adequate space for a future ocular prosthesis.<sup>4</sup> A tooth-supported, heat-cured custom ocular prosthesis was fabricated and delivered. This method was chosen to enhance the retention and stability of the prosthesis, offering improved cosmetic and functional outcomes.<sup>5,6</sup>

The fabrication of a custom ocular prosthesis involves a meticulous process of impression making, wax pattern try-in, and color matching to ensure the final prosthesis blends seamlessly with the patient's natural eye. Thereby improving comfort and confidence of patient.<sup>7,8</sup> This case underscores the critical importance of a customized approach in prosthetic eye rehabilitation, essential for achieving the best possible outcomes for patients with congenital anophthalmia.

\* Corresponding author.

E-mail address: [raj.salvi54@gmail.com](mailto:raj.salvi54@gmail.com) (R. C. Salvi).

## 2. Case Report

A 25 year old female patient reported to the department of prosthodontics and crown and bridge, with the chief complaint of unaesthetic appearance due to missing right eye. Patient is a diagnosed case of unilateral congenital anophthalmia. She was suffering from severe emotional trauma due to deformed facial esthetics.

During the examination, a shrunken anophthalmic cavity with intact soft tissue bed was noted, indicative of an ocular defect. (Figure 1) The patient exhibited normal eyelid movements, and there were no signs of inflammation in the periorbital tissues. The patient was informed about the rehabilitation options for the right eye, including stock and custom ocular prostheses, along with their respective limitations. After consideration, the patient chose to proceed with a custom ocular prosthesis. Written consent was obtained accordingly.

### 2.1. Procedure

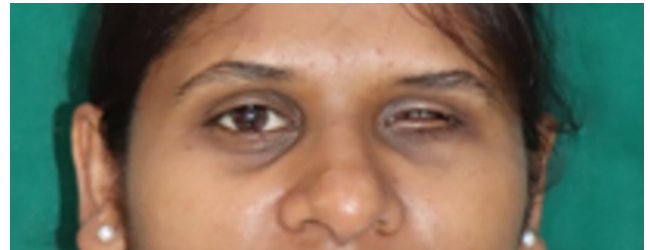Patients anophthalmic socket was irrigated with saline followed by light lubrication with lubricant. A semi customized impression tray was made with an addition silicone light body applicator tip (Avue gum light body, Dental Avenue, India) and plastic spoon. (Figure 2) The light body was expressed into the anophthalmic cavity and the patient was instructed to close the eyelids and perform various eye movements. (Figure 3)

After setting, the primary impression was removed and inspected for any voids. Boxing was done with modelling wax. The impression was poured till the convexity or height of contour of the ocular defect with type III dental stone (Kalrock; Kalabhai Karson, India) to obtain a primary cast. The cast was retrieved and evaluated for any errors.


Custom tray was fabricated with self-cure acrylic resin. (Figure 4)(DPI self-cure tooth molding powder, Mumbai) The final impression was made using light body in a similar manner.(Figure 5) The final impression was removed and checked for any error. This was followed by beading and boxing. A final cast was poured to obtain a split cast. Wax pattern was made to duplicate the contour of the contralateral eye. Patient was instructed to perform various eye movements to check the fit and comfort. A putty index of wax pattern was made using condensation silicone. (Zeta Plus, Zhermack, Italy)

A conformer was fabricated using putty index of wax pattern with clear acrylic to increase the size of the shrunken anophthalmic socket. (Figure 6) Using the conformer the soft tissue profile of the eyelids were adequately matched. Patient was instructed to use this conformer until the size of anophthalmic cavity is increased. The wax pattern was repeated according to the increased size of anophthalmic cavity. Stock iris was selected to match the size and color of patients contralateral iris.

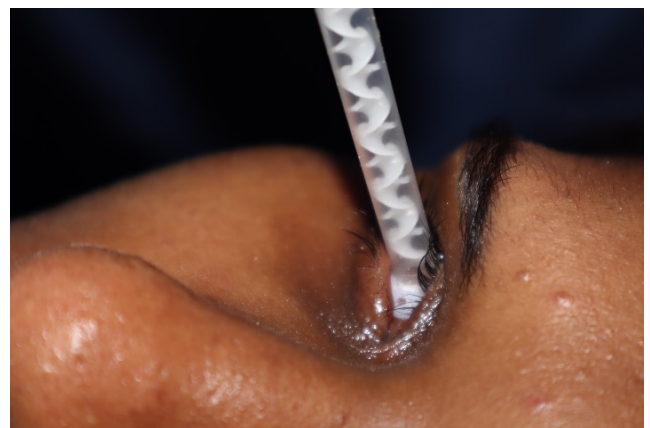Iris centering was done by marking points on the patient's face: the facial midline, the center of the iris of the opposite eye, and a third point at the same distance from the midline as the iris center. (Figure 7) These marks were transferred to the wax pattern and final cast, then the iris was positioned in the patient's anophthalmic cavity. The centered iris was evaluated using a digital graph on a frontal facial photograph. (Figure 8)



**Figure 1:** Patient has unilateral anophthalmia with right eye

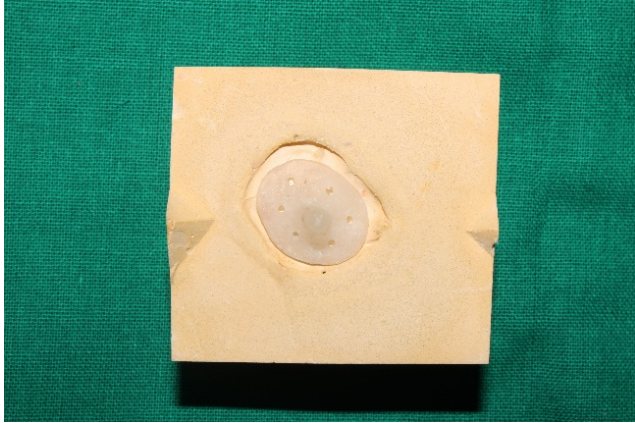

**Figure 2:** Semicustomized impression tray

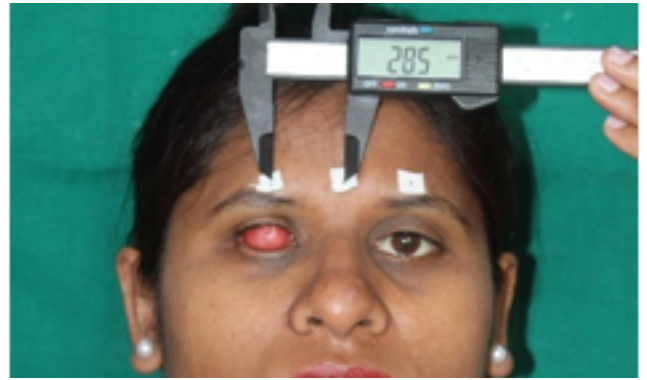

**Figure 3:** Recording of primary impression

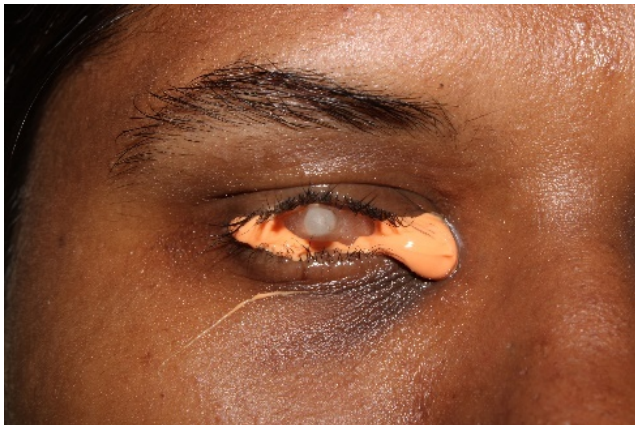Patients scleral shade was selected using customized shade guide created with tooth colored heat cure acrylic



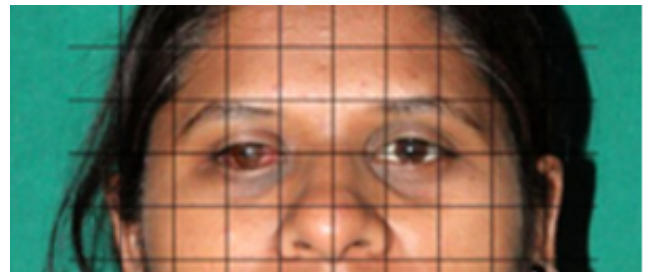**Figure 4:** Custom tray on primary cast



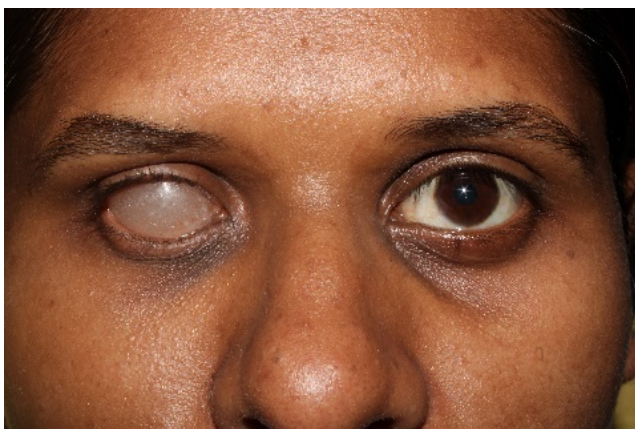
**Figure 7:** Centering of iris



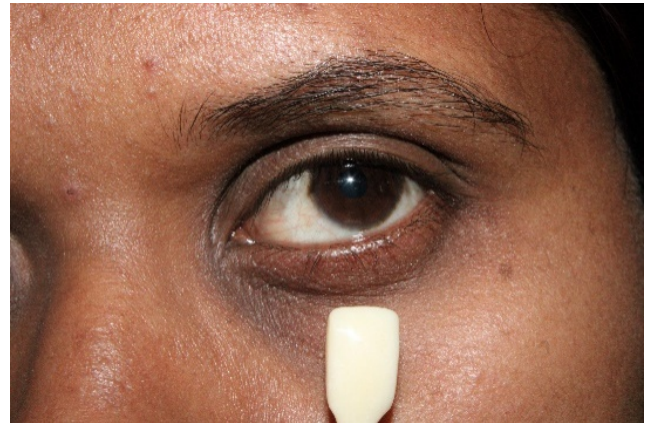**Figure 5:** Final impression



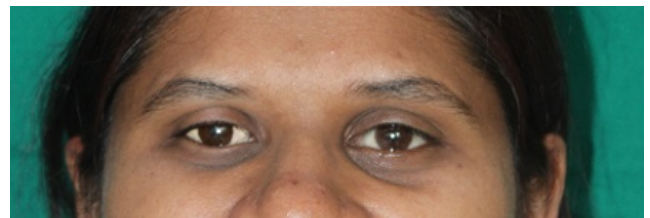**Figure 8:** Digital verification of centered iris



**Figure 6:** Conformer



**Figure 9:** Scleral shade selection using customized shade guide



**Figure 10:** Delivery of custom ocular prosthesis

resin. (Figure 9) The iris was stabilized with plastic cap of gas torch and adhesive. Flasking was done followed by dewaxing, packing and processing with tooth colored heat cure acrylic resin. (DPI heat-cure tooth molding powder, Mumbai)

The prosthesis was retrieved followed by characterization with acrylic colors to match the patients contralateral eye. A thin layer of spacer wax was adapted on this ocular prosthesis and flasking, dewaxing, and processing was done with heat cure clear acrylic resin. The final custom ocular prosthesis was retrieved followed by finishing and polishing. This final prosthesis was delivered to the patient and evaluated critically for lid drape, contour, and dimension. The follow-up was done after a week.

### 3. Discussion

This case highlights several innovative aspects of the custom ocular prosthesis fabrication process, providing insights that can significantly impact future practices.

#### 3.1. Use of conformers

One standout feature in this case is the strategic use of a conformer to address a shrunken anophthalmic cavity. By gradually increasing the cavity size, the conformer ensures better adaptation of the final prosthesis to the socket. This approach is not universally applied but has demonstrated its effectiveness in enhancing both comfort and aesthetic outcomes for patients. The gradual resizing facilitated by the conformer is crucial for achieving a precise fit, a fundamental factor in the success of ocular prostheses.<sup>9</sup>

#### 3.2. Custom tray fabrication

The fabrication of the custom tray using self-cure acrylic resin provided a highly detailed and accurate final impression, essential for producing a well-fitting prosthesis. While this step may be routine, its critical role in ensuring an optimal fit is often underappreciated. Emphasizing the precision of the custom tray fabrication process can significantly improve prosthetic outcomes.<sup>10</sup>

#### 3.3. Digital evaluation for iris centering

A particularly noteworthy innovation in this case is the use of digital evaluation for iris centering. By leveraging facial landmarks, this method achieves precise alignment of the prosthetic eye's iris with the contralateral eye. This digital approach represents a significant advancement over traditional methods, offering increased precision and better aesthetic outcomes, which in turn enhances patient confidence and satisfaction.<sup>11</sup>

#### 3.4. Customized shade guide

The creation of a customized shade guide using tooth-colored acrylic resin to match the scleral color is

another unique aspect. This approach ensures that the prosthesis closely matches the patient's natural eye color, contributing to a more natural and aesthetically pleasing appearance. Such customization plays a crucial role in patient satisfaction.

#### 3.5. Advanced final processing techniques

The final processing steps, including detailed characterization with acrylic colors and the addition of a clear acrylic resin layer for a smooth finish, further distinguish this case. These advanced techniques ensure the durability and aesthetic appeal of the prosthesis, closely mimicking the contralateral eye. Emphasizing these detailed final processing steps can significantly enhance the overall quality of the prosthetic outcome.<sup>7</sup>

### 4. Conclusion

This case emphasizes the critical roles of using a conformer for anophthalmic socket management and digital evaluation for precise iris positioning, along with meticulous final processing techniques. These innovations significantly enhance the fit, function, and aesthetic quality of ocular prostheses, leading to improved patient outcomes and satisfaction.

### 5. Source of Funding

None.

### 6. Conflict of Interest

None.

### References


1. Quaranta-Leoni FM. Congenital anophthalmia: current concepts in management. *Curr Opin Ophthalmol*. 2011;22(5):380–4.
2. Bernardino CR. Congenital anophthalmia: a review of dealing with volume. *Middle East Afr J Ophthalmol*. 2010;17(2):156–60.
3. Aggarwal H, Kumar P, Singh RD. Prosthetic management of congenital anophthalmia-microphthalmia patient. *Arch Med Health Sci*. 2015;3(1):117–20.
4. Reddy PS, Murugesan, Abraham P, Kumar V. Prosthodontic and surgical management of anophthalmia: a case report. *J Indian Prosthodont Soc*. 2014;14(1):120–3.
5. Sethi T, Kheur M, Haylock C, Harianawala H. Fabrication of a custom ocular prosthesis. *Middle East Afr J Ophthalmol*. 2014;21(3):271–4.
6. Pires R, Vaz-Pereira S, Lagoa R. Improving the quality of life of patients with ocular prosthesis: Benefits and Design of Custom Ocular Prostheses. *J Craniofac Surg*. 2018;29(7):675–8.
7. Salvi RC, Chauhan M, Temburne J, Gangurde A, Shetty P. Rehabilitation of an ocular defect with custom ocular prosthesis- A case report. *IP Ann Prosthodont Restor Dent*. 2023;9(4):239–43.
8. Baylor E, Phillips PW. Custom-made ocular prostheses: A review. *J Prosthet Dent*. 2004;91(4):386–90.
9. Al-Oulabi A, Rawas MA, Farook TH, Rashid F, Barman A, Jamayet NB, et al. The loss of an eye due to occupational injury: Two case studies of ocular prosthetic rehabilitation. *Work*. 2021;69(3):865–70.

10. Shrivastava KJ, Shrivastava S, Yadav NS, Gupta S. Rehabilitation of unilateral loss of eye with customized ocular prosthesis: Case series. *Indian J Dent Res.* 2020;31(2):326–30.
11. Gupta RK, Padmanabhan TV. Prosthetic rehabilitation of a post evisceration patient with custom made ocular prosthesis: a case report. *J Indian Prosthodont Soc.* 2012;12(2):108–12.


**Jyoti Tembhurne**, Professor and Head

**Arti Gangurde**, Associate Professor

**Niraja Jaiswal**, Associate Professor

**Pradnya Salian**, Post Graduate Student  <https://orcid.org/0009-0005-0852-2422>

### Author biography

**Raj Chandrakant Salvi**, Post Graduate Student  <https://orcid.org/0009-0007-0675-4056>

**Manish Chauhan**, Associate Professor

**Cite this article:** Salvi RC, Chauhan M, Tembhurne J, Gangurde A, Jaiswal N, Salian P. Rehabilitation of patient with unilateral congenital anophthalmia using custom ocular prosthesis. *IP Int J Ocul Oncol Oculoplasty* 2024;10(2):106-110.