

Content available at: <https://www.ipinnovative.com/open-access-journals>

IP International Journal of Ocular Oncology and Oculoplasty

Journal homepage: <https://ijooo.org/>

## Case Report

# Imaging signatures in diffuse choroidal hemangioma in a case of Sturge Weber syndrome

Rinal Pandit<sup>1\*</sup>, Dhairat Shah<sup>2</sup>, Deepanshu Agrawal<sup>2</sup>, Sukanya Gorhe<sup>2</sup>, Neha Sharma<sup>3</sup>

<sup>1</sup>Dept. of Glaucoma, Choithram Netralaya, Indore, Madhya Pradesh, India

<sup>2</sup>Dept. of Vitreoretina, Choithram Netralaya, Indore, Madhya Pradesh, India

<sup>3</sup>Dept. of Community Ophthalmology, Choithram Netralaya, Choithram Netralaya, Madhya Pradesh, India



## ARTICLE INFO

### Article history:

Received 15-11-2023

Accepted 06-12-2023

Available online 01-02-2024

### Keywords:

Sturge Weber syndrome

Diffuse choroidal hemangioma

Tomato ketchup fundus appearance

## ABSTRACT

Sturge–Weber syndrome (SWS) is a rare congenital neurocutaneous disorder characterized by facial port-wine stain, leptomeningeal hemangiomas, and ocular manifestations such as glaucoma and diffuse choroidal hemangioma (DCH). DCH is a benign vascular lesion characteristically seen in up to 50% of patients affected with SWS. Diffuse choroidal hemangioma can cause refractive error, foveal distortion, and exudative retinal detachment and contribute to vision loss. We report a case of a young male with SWS and a unilateral DCH with characteristic imaging features.

This is an Open Access (OA) journal, and articles are distributed under the terms of the [Creative Commons Attribution-NonCommercial-ShareAlike 4.0 License](https://creativecommons.org/licenses/by-nc-sa/4.0/), which allows others to remix, tweak, and build upon the work non-commercially, as long as appropriate credit is given and the new creations are licensed under the identical terms.

For reprints contact: [reprint@ipinnovative.com](mailto:reprint@ipinnovative.com)

## 1. Introduction

Sturge Weber syndrome (SWS) is a rare neurocutaneous disorder consisting of a triad of Port wine stain, leptomeningeal hemangioma, and ocular manifestations including diffuse choroidal hemangioma (DCH) and glaucoma. Choroidal hemangiomas can be circumscribed or diffuse. The diffuse form typically occurs in SWS. DCH is a benign vascular choroidal tumor that has poorly defined borders and extends over a broad area of the choroid. Thus asymptomatic tumors are often difficult to diagnose because of this indistinct appearance. Potential visual loss can be owing to exudative retinal detachment and macular edema. DCH may increase the risk of neovascular glaucoma development secondary to chronic exudative retinal detachment. Ancillary tests with multimodal imaging are mandatory in asymptomatic DCH for its diagnosis and management. Here we report characteristic clinical and imaging signatures in DCH in a young male with SWS.

## 2. Case Report

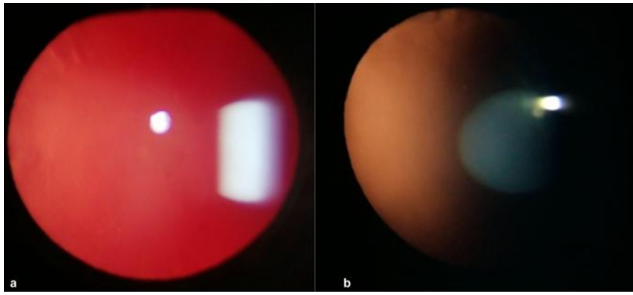
A 17-year-old male presented to our hospital with the chief complaint of dimness of vision in his right eye (RE) for 1 year. On examination, corrected distant visual acuity was 20/400 in the RE and 20/20 in the left eye (LE). The intraocular pressure was 38 mm Hg in RE and 14 mmHg in LE. On external examination, a purple-colored skin discoloration (Port-wine stain) was noted over the right forehead and periorbital region extending over the nasal region up to midline.

Anterior segment evaluation in RE revealed dilated and tortuous episcleral vessels and a relative afferent pupillary defect. Upon gonioscopy, wide open angles with blood in the schlemms canal were noted in the inferior and nasal quadrants. Dilated fundus evaluation in the right eye showed advanced cupping of the optic disc, dilated and tortuous vessels, and a diffuse red-coloured appearance of the fundus (tomato ketchup appearance) [Figure 2a] with respect to the fellow eye [Figure 2b]. Anterior and posterior segment examinations in LE were unremarkable. Based on the

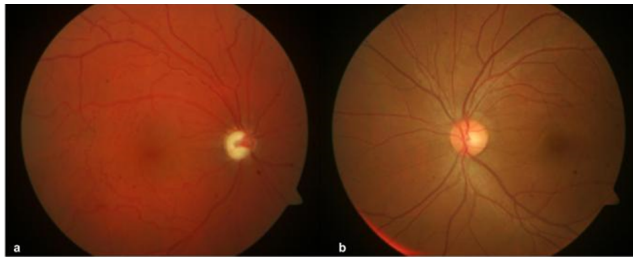\* Corresponding author.

E-mail address: [rinalpandit@gmail.com](mailto:rinalpandit@gmail.com) (R. Pandit).

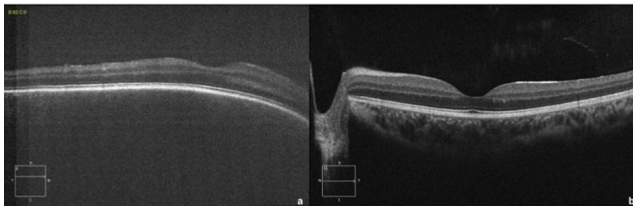
clinical findings, a provisional diagnosis of SWS with RE DCH and secondary glaucoma was made. A color fundus photo (Carl Zeiss, Germany) was obtained for baseline documentation.



**Figure 1:** a: Slit lamp photograph of the RE showing a bright red pupillary reflex in retroillumination; b: Normal orange-red pupillary reflex in the LE



**Figure 2:** Colour fundus photo (Carl Zeiss, Germany); a: RE shows advanced glaucomatous cupping, vessel tortuosity and diffuse red 'tomato-ketchup' appearance; b: LE shows normal fundus



**Figure 3:** Optical Coherence Tomography (OCT) B-scan (Angioplex 5000, Carl Zeiss, Germany) through the macula; a: RE shows 'dome-shaped' elevation without any subretinal fluid; b: LE shows normal macular profile.

Optical Coherence Tomography (OCT) B-scan (Angioplex 5000, Carl Zeiss, Germany) through the macula showed a dome-shaped elevation with choroidal thickening confirming the choroidal tumor [Figure 3a]. Anti-glaucoma medications were started, and observation was advised for the choroidal hemangioma with all possible complications explained. MRI- brain was advised to rule out leptomeningeal angiomas.

### 3. Discussion

DCH is seen in up to 50% of cases of SWS.<sup>1</sup> In DCH the normal choroidal vascular tufts are replaced by thin-walled capillaries and small veins, forming a cavernous vascular complex. These proliferative lesions cause the enlargement of the choroidal plexus.<sup>2</sup> DCH is present ipsilateral to the facial lesion and clinically seen as a diffuse, red-orange colored mass with ill-defined borders spread across a broad area of the choroid.<sup>3</sup> Asymptomatic lesions at the posterior pole are often missed owing to their subtle and indistinct appearance and remain undiagnosed until the later stages when they become symptomatic. Two main clinical clues point towards the diagnosis of DCH in the setting of SWS. First is a brilliant red pupillary reflex in the involved eye compared to the normal reflex in the fellow eye [Figure 1]. Second, is the classical 'tomato-ketchup' fundus appearance<sup>4</sup> of the involved eye as against the normal colored fundus background in the normal fellow eye [Figure 2]. These subtle color changes are well appreciated with fundus photography as compared to fundus ophthalmoscopy. The diagnosis of DCH can be easily confirmed with OCT which shows the characteristic 'dome-shaped' macular profile due to the elevation of the retinal layers secondary to the underlying choroidal tumor. There are no structural alterations in the retinal layers [Figure 3].<sup>2</sup> B-scan Ultrasonography will show choroidal thickening with marked internal reflectivity. It can also detect the presence of additional features like retinal detachment and superficial calcifications.<sup>5,6</sup> Other ancillary imaging tests include Fundus autofluorescence, Indocyanine Green Angiography (ICG-A), spectral-domain Optical Coherence Tomography (SDOCT), and optical coherence angiography (OCTA).<sup>7–9</sup> These imaging modalities aid in the diagnosis of DCH in asymptomatic cases.

DCH are usually asymptomatic, however, they can contribute to vision loss due to refractive errors, hyperopic amblyopia, foveal distortion, macular edema, photoreceptor damage, and exudative retinal detachment.

Asymptomatic tumors are observed and treatment is warranted only when subretinal fluid is noted. Treatment options include external beam radiotherapy (EBRT), proton beam radiotherapy (PBT), targeted radiation using plaque brachytherapy, and the more recent photodynamic therapy.<sup>10</sup>

### 4. Conclusion

Although DCH is asymptomatic in most cases, it can lead to complications in later stages. Thus making early diagnosis and regular monitoring is extremely crucial. The present case highlights the use of multimodal imaging techniques with the classical imaging signatures in DCH to arrive accurately at the diagnosis in asymptomatic patients. This can help to analyze its progression and customize the

intervention methods accordingly.

## 5. Source of Funding

None.

## 6. Conflict of Interest

None.

## References

1. Sullivan TJ, Clarke MP, Morin JD. The ocular manifestations of the Sturge-Weber syndrome. *J Pediatr Ophthalmol Strabismus*. 1992;29(6):349–56.
2. Formisano M, di Pippo M, Scuderi L, Abdolrahimzade S. Current concepts on diffuse choroidal hemangioma in Sturge Weber syndrome. *Ophthalmic Genet*. 2021;42(4):375–82.
3. Witschel H, Font RL. Hemangioma of the choroid. A clinicopathologic study of 71 cases and a review of the literature. *Surv Ophthalmol*. 1976;20(6):415–31.
4. Arepalli S, Shields CL, Kaliki S. Diffuse choroidal hemangioma management with plaque radiotherapy in 5 cases. *Ophthalmology*. 2013;120(11):2358–59.
5. Goldberg MF, Hodes BL. Ultrasonographic diagnosis of choroidal malignant melanoma. *Surv Ophthalmol*. 1977;22(1):29–40.
6. Ciancimino C, Pippo D, Rullo M, Ruggeri D, Grassi F, Scuderi F, et al. An Update on Multimodal Ophthalmological Imaging of Diffuse Choroidal Hemangioma in Sturge–Weber Syndrome. *Vision (Basel)*. 2023;7(4):64. doi:10.3390/vision7040064.
7. Abdolrahimzadeh S, Scavella V, Battaglia D, Recupero SM. Spectral domain optical coherence tomography of choroidal and outer retinal layer thickness in the Sturge Weber Syndrome. *Curr Eye Res*. 2016;41(12):1614–7.
8. Konana V, Shanmugam P, Ramanjulu R, Mishra KC, Sagar P. Optical coherence tomography angiography features of choroidal hemangioma. *Indian J Ophthalmol*. 2018;66(4):581–3.
9. Singh AD, Rundle PA, Vardy SJ, Rennie IG. Photodynamic therapy of choroidal haemangioma associated with Sturge-Weber syndrome. *Eye*. 2005;19:365–7. doi:10.1038/sj.eye.6701474.
10. Ang M, Lee SY. Multifocal Photodynamic Therapy for Diffuse Choroidal Hemangioma. *Clin Ophthalmol*. 2012;6:1467–9. doi:10.2147/OPHTH.S35471.

## Author biography

**Rinal Pandit**, Consultant

**Dhaivat Shah**, Consultant

**Deepanshu Agrawal**, Consultant

**Sukanya Gorhe**, Consultant

**Neha Sharma**, Student

**Cite this article:** Pandit R, Shah D, Agrawal D, Gorhe S, Sharma N. Imaging signatures in diffuse choroidal hemangioma in a case of Sturge Weber syndrome. *IP Int J Ocul Oncol Oculoplasty* 2023;9(4):219-221.