

Content available at: <https://www.ipinnovative.com/open-access-journals>

IP International Journal of Ocular Oncology and Oculoplasty

Journal homepage: <https://ijooo.org/>

Case Report

To study the clinical course and management of recurrent OSSN in HIV positive patient in Eastern Uttar Pradesh

Kriti Bhatt¹, Aditi Jhunjunwala^{2,*}

¹Dept. of Ophthalmology, M.L.N. Medical College, Prayagraj, Uttar Pradesh, India

²Dept. of Ophthalmology, Govt. Medical College, Deoria, Uttar Pradesh, India



ARTICLE INFO

Article history:

Received 15-08-2023

Accepted 15-09-2023

Available online 06-11-2023

Keywords:

HIV

Management

OSSN

Recurrence

ABSTRACT

Introduction: We present a case of recurrent OSSN in HIV positive individual and its successful management. Patient presented to us with slow growing painless greyish mass in temporal area in interpalpebral region. He was diagnosed with HIV 2 years back and was on HAART regimen. He underwent excision for a similar looking mass in same eye 2 years back at the same time he was diagnosed with HIV. On local examination, a greyish white raised nodular gelatinous mass with feeder vessel was seen. It did not involve cornea and took up staining with rose bengal stain. complete excision biopsy using no-touch technique with a margin clearance of 4 mm followed by mitomycin-C and the remaining conjunctival defect closed with amniotic membrane graft was done. Histopathology confirmed OSSN. No recurrence was seen at 2-year follow-up.

Conclusion: HIV shows a strong relation with OSSN and also with recurrent disease. Histopathology should always be done in interpalpebral mass excision in HIV positive patients as the recurrence rate is higher with more aggressive tumour.

This is an Open Access (OA) journal, and articles are distributed under the terms of the [Creative Commons Attribution-NonCommercial-ShareAlike 4.0 License](https://creativecommons.org/licenses/by-nc-sa/4.0/), which allows others to remix, tweak, and build upon the work non-commercially, as long as appropriate credit is given and the new creations are licensed under the identical terms.

For reprints contact: reprint@ipinnovative.com

1. Introduction

Ocular surface squamous neoplasia first described by Von Graefe in 1860¹ is an important clinical entity because of its similar clinical appearance as many common benign pathologies like pterygium, pinguecula, and conjunctival cysts. The term includes ocular surface tumours ranging from mild dysplasia to intraepithelial neoplasia to varying grades of invasive squamous cell carcinoma.² Initial stages start at the transition zone between cornea and conjunctiva (limbus) and can involve eyelid and orbit in advanced stages.² The term ocular surface squamous neoplasia was first coined by Lee and Hirst,³ who classified it into three 3 grades - benign dysplasia, pre-invasive OSSN and invasive OSSN.

Incidence of OSSN is maximum in places near equator and decreases as the distance from equator increases with reported incidence ranging between <0.2 cases/million/year in UK to 35 cases/million/year in Uganda.^{4,5} It was primarily used to be found in elderly male with the mean age of presentation in mid 60s^{3,6,7} but in recent years mean age of presentation has come down to mid-40s with the onset of HIV pandemic.^{8,9}

It is a disease of multifactorial origin with smoking, light hair and skin, xerophthalmia (Vitamin A deficiency), exposure to petroleum products, ultra-violet radiation exposure and immunodeficiency (HIV being most common) being found to play a significant role in its pathogenesis.¹⁰ Ultraviolet B radiation leading to various mutations in p53 was found to responsible in the development of squamous cell carcinoma in various studies.¹¹

* Corresponding author.

E-mail address: aditijtw@gmail.com (A. Jhunjunwala).

It commonly presents unilaterally with a pearly grey growth on the ocular surface near limbus in interpalpebral region which can later cross limbus and involve cornea with common symptoms of foreign body sensation, irritation redness and diminution of vision. Feeder vessels can usually be seen at the base of the lesion.¹² Grossly the lesion can be either nodular, gelatinous, flat superficial leukoplakic or diffusely infiltrating.^{12,13} Several studies found predominantly leukoplakic and large lesion in HIV positive patients.^{6,8} Definitive differentiation of type and grading of lesion can only be done on histopathology.

We present a case of recurrent OSSN in HIV positive patient earlier operated for mass in temporal interpalpebral region in right eye.

2. Case Report

A 45-year-old male, an electrician by occupation and known case of HIV currently on tenofovir-lamivudine-efavirenz regimen for 2 years presented to the ophthalmology OPD with chief complaints of a slow growing painless greyish fleshy mass and diminution of vision in right eye for 1 year. Patient was operated for a similar greyish fleshy mass in right eye 2 years back, details and documents of which are not available with patients. It was also during the routine test for mass excision 2 years back, patient was diagnosed with HIV and subsequently started on HAART regimen. According to the patient, biopsy was not sent 2 years back. Patient had no history of redness, watering, discharge, DM, HTN, any skin disease and TB.

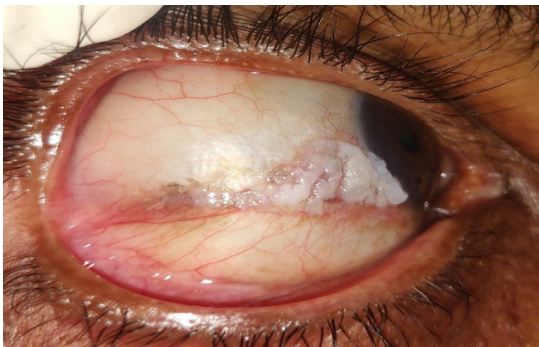


Fig. 1: Clinical picture showing gelatinous conjunctival growth.

On examination visual acuity of right eye was 6/12 and left eye was 6/6. On local examination, a greyish white raised nodular gelatinous mass of size 14mm*5mm in the inter-palpebral region extending from temporal limbus involving 2 clock hours (7' to 9'o clock hours) up to 13 mm laterally with few leukoplakic changes and engorged feeder vessel at the base was seen. It did not involve cornea and took up staining with rose Bengal stain. On lacrimal work-up ROPLAS was negative with syringing freely patent. Systemic examination did not reveal any lymphadenopathy. Imprint cytology was sent which

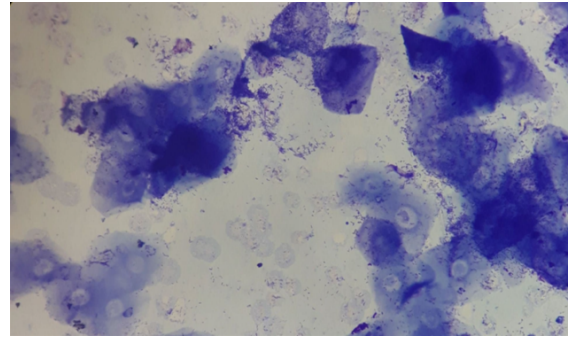


Fig. 2: Imprint cytology showing Mild reactive and koilocytic changes suggestive of mild dysplasia

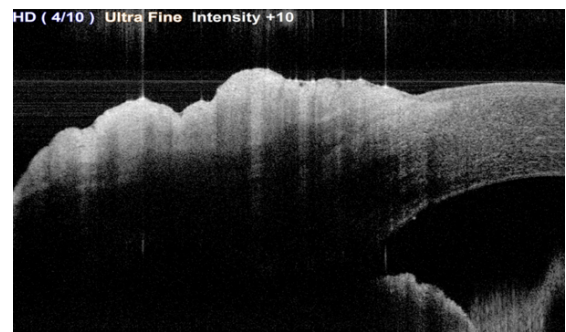


Fig. 3: AS-OCT showing thickened and hyperreflective epithelium with abrupt transition

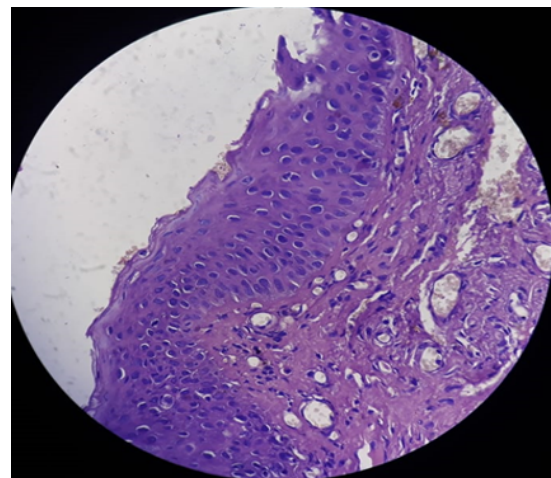


Fig. 4: Histopathology showing hyperplastic keratinized stratified squamous epithelium with full thickness dysplastic changes. Dysplastic cells were large with high N:C ratio, hyperchromatic nucleus and loss of polarity.

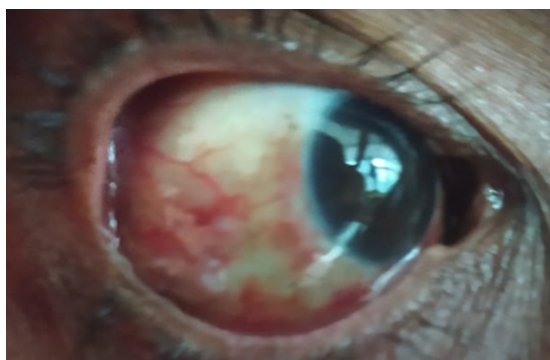

Fig. 5: At 1-week post-Op follow-up

showed mild reactive and koilocytic changes suggestive of mild dysplasia. Anterior segment OCT showed thickened and hyperreflective epithelium with abrupt transition. MRI showed no orbital extension. Provisional diagnosis was made to be right eye recurrent gelatinous ocular surface squamous neoplasia.

After getting the informed consent from patient complete excision biopsy using No-touch Technique with a margin clearance of 4 mm of uninvolved conjunctiva followed by mitomycin-C and the remaining conjunctival defect closed with amniotic membrane graft was done. Excised mass was sent for histopathology which showed hyperplastic keratinized stratified squamous epithelium with full thickness dysplastic changes. Dysplastic cells were large with high N:C ratio, hyperchromatic nucleus and loss of polarity. No foci of invasion were seen suggestive of high-grade squamous cell dysplasia. patient was followed up every 3 months in 1st year and 6 monthly after that. No recurrence was seen at 2 years follow up.

3. Discussion

Increase in cases of HIV in recent years resulted in 3 to 30 times increased risk of having OSSN.⁸ Many studies have shown that HIV is related to more aggressive and higher-grade tumours. It can be the first symptom of an underlying HIV infection. In a study done by Kaliki S et al,¹⁴ OSSN was the presenting sign in 26% cases, out of which 70% were unaware of their HIV-positive status. Similarly, in a retrospective cross-sectional study done by Dandala PP,¹⁴ 23% of the patients were positive for HIV in whom mean age of presentation was 34 years and among HIV positive patients 78.26% had SCC. They concluded that in males, HIV positive and people with outdoor occupations incidence was more with HIV positive individuals showing increased incidence of OSSN with invasive characteristics. Our patient is 45-year-old HIV positive male who works as an electrician and tend to spend most of his day outside.

In a case control study done by Kamal S et al¹⁵ to compare OSSN in HIV positive and negative patients, they found that HIV-positive individuals had larger and thicker

(tumours, with a higher incidence of corneal scleral and orbital invasion and a higher need for extended enucleation or exenteration. HIV positive patients had higher rate of tumour recurrence after primary treatment. In our case, patient had a mass similar mass in temporal region of right eye which was operated 2 years back.¹⁶

Management of OSSN in HIV positive patients depends on the tumour characteristics and there is no set guideline specifically for HIV positive individuals. The most commonly performed treatment is surgical management by wide excision. Wide excision biopsy with “no-touch” technique and 4 mm tumour-free margins followed by direct closure or amniotic membrane graft¹⁷ as was done in our patient and resected specimen was sent for histopathology which confirmed OSSN.

Gichuhi S et al¹⁸ recommends frequent follow-up at 1 week, 6 weeks, 3 months, and 6 months, and then at 6-monthly intervals till 2 years. No recurrence was seen in our patient at 2-year follow-up.

4. Conclusion

HIV shows a strong relation with OSSN and also with recurrent disease. Histopathology should always be done in interpalpebral mass excision in HIV positive patients as the recurrence rate is higher with more aggressive tumour.

5. Source of Funding

None.

6. Conflict of Interest

There is no conflict of interest.

References

1. Basti S, Macsai MS. Ocular surface squamous neoplasia: a review. *Cornea*. 2003;22(7):687–704.
2. Gichuhi S, Ohnuma S, Sagoo M, Burton M. Pathophysiology of ocular surface squamous neoplasia. *Exp Eye Res*. 2014;129:172–82.
3. Lee GA, Hirst LW. Ocular surface squamous neoplasia. *Surv Ophthalmol*. 1995;39(6):429–50.
4. Ateenyi-Agaba C. Conjunctival squamous-cell carcinoma associated with HIV infection in Kampala, Uganda. *Lancet*. 1995;345(8951):695–6.
5. Newton R, Reeves G, Beral V. Effect of ambient solar ultraviolet radiation on incidence of squamous-cell carcinoma of the eye. *Lancet*. 1996;347(9013):1450–1.
6. Kabra RC, Khaitan IA. Comparative analysis of clinical factors associated with ocular surface squamous neoplasia in HIV infected and non HIV patients. *J Clin Diagn Res*. 2015;9(5):1–3.
7. Lee GA, Hirst LW. Incidence of ocular surface epithelial dysplasia in metropolitan Brisbane. A 10-year survey. *Arch Ophthalmol*. 1992;110(4):525–7.
8. Makupa II, Swai B, Makupa WU, White VA, Lewallen S. Clinical factors associated with malignancy and HIV status in patients with ocular surface squamous neoplasia at Kilimanjaro Christian Medical Centre, Tanzania. *Br J Ophthalmol*. 2012;96(4):482–4.
9. Osahon AI, Ukponmwan CU, Uhumwango OM. Prevalence of HIV seropositivity among patients with squamous cell carcinoma of the

- conjunctiva. *Asian Pac J Trop Biomed.* 2011;1(2):150–3.
10. Mannis M, Holland EJ. *Cornea Fundamentals, Diagnosis and Management* 5th. vol. 2. Saunders, Mosby, Churchill: Elsevier; 2021.
 11. Viswamithra P, Bhaskara N. Ocular surface squamous neoplasia. *J Dr NTR Univ Health Sci.* 2014;3(3):185–8.
 12. Krishnaraj J, Das SS, Vendhan K. Ocular surface squamous neoplasia (OSSN). *IP Int J Ocul Oncol Oculoplasty.* 2016;2(1):19–30.
 13. Singh V, Maurya RP, Pal K, Singh S, Singh VP, Ananad K, et al. Ocular squamous neoplasia. An overview. *IP Int J Ocul Oncol Oculoplasty.* 2022;8(1):1–11.
 14. Kaliki S, Kamal S, Fatima S. Ocular surface squamous neoplasia as the initial presenting sign of human immunodeficiency virus infection in 60 Asian Indian patients. *Int Ophthalmol.* 2017;37(5):1221–8.
 15. Dandala PP, Malladi P, Kavitha. Ocular Surface Squamous Neoplasia (OSSN): A Retrospective Study. *J Clin Diagn Res.* 2015;9(11):NC10–3.
 16. Kamal S, Kaliki S, Mishra DK, Batra J, Naik MN. Ocular Surface Squamous Neoplasia in 200 Patients: A Case-Control Study of Immunosuppression Resulting from Human Immunodeficiency Virus versus Immunocompetency. *Ophthalmology.* 2015;122(8):1688–94.
 17. Shields JA, Shields CL, De Potter P. Surgical management of conjunctival tumors: the 1994 Lynn B McMahan Lecture. *Arch Ophthalmol.* 1997;115(6):808–15.
 18. Gichuhi S, Irlam JJ. Interventions for squamous cell carcinoma of the conjunctiva in HIV-infected individuals. *Cochrane Database Syst Rev.* 2007;(2):CD005643. doi:10.1002/14651858.CD005643.pub3.

Author biography

Kriti Bhatt, Senior Resident

Aditi Jhunjhunwala, Senior Resident

Cite this article: Bhatt K, Jhunjhunwala A. To study the clinical course and management of recurrent OSSN in HIV positive patient in Eastern Uttar Pradesh. *IP Int J Ocul Oncol Oculoplasty* 2023;9(3):133-136.