

Content available at: <https://www.ipinnovative.com/open-access-journals>

IP International Journal of Ocular Oncology and Oculoplasty

Journal homepage: <https://ijooo.org/>

## Original Research Article

# Clinical presentations, epidemiology and management of COVID-19 associated Mucor mycosis in a tertiary care hospital in South India

Madhusudhan C N<sup>1</sup>, Raghavendra R<sup>1</sup>, Nischala Balakrishna<sup>1,\*</sup>, DN Prakash<sup>1</sup>, K Satish<sup>1</sup>

<sup>1</sup>Dept. of Ophthalmology, Krishna Rajendra Hospital, Mysore Medical College and Research Institute, Mysore, Karnataka, India



## ARTICLE INFO

## Article history:

Received 05-04-2023

Accepted 25-04-2023

Available online 26-05-2023

## Keywords:

Mucor mycosis

Corona virus

Rhinoorbitocerebral mucor mycosis

Black Fungus

Immune suppression

## ABSTRACT

**Aims:** To study the statistics of the epidemiology, co-morbidities, clinical presentations, management and prognosis of the study group.

**Materials and Methods:** This is a retrospective study conducted in a tertiary care hospital in South India, among 100 subjects, between May 2021 and August 2021 when the Mucor mycosis cases were frequently being diagnosed and treated amongst COVID-19 infected patients.

**Results:** The results showed that 34.0% were between 51-60 years with 100% patients confirmed COVID positive through RTPCR tests. 86.0% had confirmed mucor on CT scan. 50.0% had both eyes vision of 6/60 on presentation. 67.% had periorbital swelling with 51% having prior co-morbidities. 63.0% patients received tablet Posaconazole 30mg as medical treatment and 60.0% required no surgical management. 10.0% required orbital exenteration and 21.0% required partial maxillectomy. 2% experienced orbital apex syndrome as associated complications. 97.0% were discharged post treatment with 3% mortality. There was a positive correlation of medical management with respect to anterior segment and posterior segment findings  $P < 0.001$  and  $P = 0.79$ . There was a positive correlation between surgical treatment and anterior and posterior segment findings  $P < 0.001$  and  $P = 0.43$ . There was a positive correlation between co-morbidities and death  $P < 0.001$ , with 32.0% uncontrolled diabetics.

**Conclusion:** This study shows that immune suppression is directly related to infectivity by mucor mycosis. In order to contain symptomatology and grave prognosis amongst patients, early diagnosis, affordable treatment and follow-up including patient education about the etiology and pathogenesis of the disease must be available.

This is an Open Access (OA) journal, and articles are distributed under the terms of the [Creative Commons Attribution-NonCommercial-ShareAlike 4.0 License](https://creativecommons.org/licenses/by-nc-sa/4.0/), which allows others to remix, tweak, and build upon the work non-commercially, as long as appropriate credit is given and the new creations are licensed under the identical terms.

For reprints contact: [reprint@ipinnovative.com](mailto:reprint@ipinnovative.com)

## 1. Introduction

The Corona virus caused a global pandemic starting in the early months of January 2020 from the Chinese city of Wuhan.<sup>1</sup> Although the first wave did not see a huge number of infective cases requiring hospitalization, the second wave, starting almost a year later in March 2021 was in contrast to the first wave. The newer variant of the older COVID-19 virus, commonly called the Delta variant

proved to be highly contagious and infective, especially in the Indian subcontinent where the country reported one of the highest infections and death rates in the world.<sup>2</sup> This unprecedented rise in the number of deaths was also associated with Mucor mycosis, particularly the Rhino-orbito-cerebral type.<sup>3,4</sup> This was due to the innumerable risk factors in the infected cases which comprised of the high usage of steroids, uncontrolled diabetes mellitus, hypoxia which required the usage of inhaled oxygen and immunosuppression which were favorable factors for the

\* Corresponding author.

E-mail address: [nischalabalakrishna@gmail.com](mailto:nischalabalakrishna@gmail.com) (N. Balakrishna).

growth spread of Mucor mycosis.<sup>5-7</sup>

Mucor mycosis is commonly described as “the black fungus” as it turns the infected tissues black due to infarction and necrosis of the hosts tissues.<sup>3</sup> It results from the invasion of tissues by the fungal hyphae and implantation of these infectious spores in the mucosal areas of conjunctiva, oral and nasal cavity or by inhalation of spores or ingestion of contaminated food.<sup>3</sup>

This is a retrospective study conducted in a tertiary care hospital in South India between May 2021 and August 2021 when the Mucor mycosis cases were frequently being diagnosed and treated amongst COVID-19 infected patients. This study is being done to study the statistics of the epidemiology, co-morbidities, clinical presentations, management and prognosis of the study group.

## 2. Materials and Methods

This retrospective study was conducted in Krishna Rajendra Hospital and Mysore Medical College and Research Institute, Mysore during May 2021- August 2021.

A total of 100 subjects who fulfil both the inclusion and exclusion criteria were selected for the study conducted at Krishna Rajendra Hospital and Mysore Medical College and Research Institute, Mysore. Followings are inclusion and exclusion criteria.

Patients who were diagnosed with COVID 19 infection after the RT-PCR test and having features of Mucor mycosis and treated were included in the study.

Patients who were COVID-19 negative and Patients who were COVID 19 positive without Mucor mycosis were excluded from study.

### 2.1. Methods

The aim and objectives of the intended study were properly explained to the patients' attendants and informed consent were obtained from all patients. Detailed information's were collected for statistical analysis from patients those fulfilling the inclusion and exclusion criteria.

The following parameters and details of the patients will be used for the purpose of the study.

1. Name of the patient.
2. Age of the patient.
3. Gender of the patient.
4. Date of Admission.
5. Date of RTPCR positive report.
6. Patient hospital ID.
7. SRF ID of patient.
8. KOH mount findings.
9. Biopsy or histopathology report of patient confirming mucor myosis.
10. Co morbidities of the patient.
11. Presenting complaints.
12. Vision and color vision of patient.

13. Extraocular movements.
14. Anterior segment examination.
15. Posterior segment examination.
16. CT scan report of brain, orbit and paranasal sinuses.
17. MRI scan of brain, orbit and paranasal sinuses.
18. Treatment given, both medical and surgical for mucor mycosis.
19. Prognosis of the patient post treatment.

All patients underwent for following investigations.

1. RTPCR test.
2. KOH Mount.
3. CT scan of brain orbit and paranasal sinuses.
4. MRI scan of brain, orbit and paranasal sinuses.
5. Biopsy or histopathology report for confirmation of mucor mycosis.
6. CBC, HIV, HBSAg, FBS, PPBS, Urine routine, LFT, RFT, Coagulation profile, CRP, D Dimer done routinely post COVID-19 diagnosis.

## 3. Results

**Table 1:** Age distribution in our study

Age in years	Number of cases	%
20-30	8	8.0
31-40	10	10.0
41-50	29	29.0
51-60	34	34.0
61-70	17	17.0
71-80	2	2.0
Total	100	100.0

**Table 2:** Investigations done in our study formucor mycosis diagnosis

Investigations	Number of cases	%	
CT scan	Brain orbit and paranasal sinuses	86	86.0
	Not done	14	14.0
	Total	100	100.0
MRI scan	Not done	81	81.0
	Done	19	19.0
	Total	100	100.0
Histopathology	Not done	92	92.0
	Done	8	8.0
	Total	100	100.0

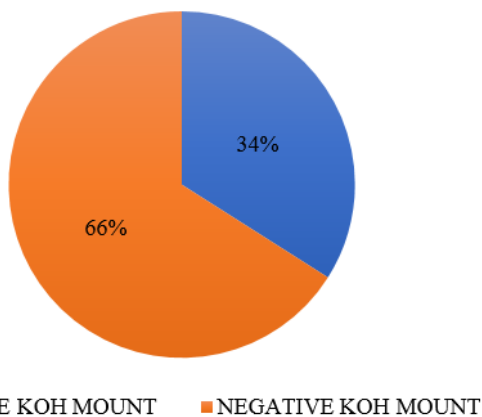
The table shows a positive correlation between anterior segment findings and medical management. Tablet Posaconazole was the main mode of treatment with 43(64.2%) patients with periorbital swelling and 11(55.0%) patients with restricted extraocular muscle movements and non-reactive pupil receiving treatment. Amongst

**Table 3:** Anterior Segment Examination findings in our study group

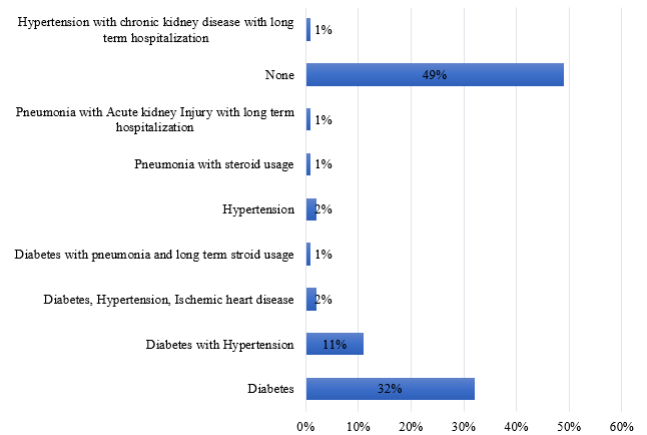
Anterior segment	Number of cases	%
Periorbital swelling	67	67.0
Restriction of extraocular movements with lacrimal apparatus blockage	6	6.0
Mild proptosis with non-reactive pupil	3	3.0
Restriction of extraocular movements	2	2.0
Restriction of extraocular movements with non-reactive pupil	20	20.0
Proptosis	2	2.0
Total	100	100.0

**Table 4:** Posterior segment Examination findings in our study group

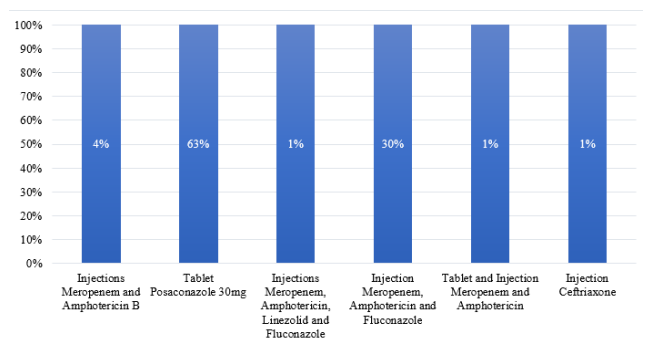
Posterior segment	Number of cases	%
None	85	85.0
Moderate Non proliferative diabetic retinopathy	1	1.0
Mild non proliferative diabetic retinopathy	2	2.0
Grade 3 hypertensive retinopathy with mild non proliferative diabetic retinopathy	7	7.0
Grade 3 hypertensive retinopathy	4	4.0
Central retinal artery occlusion	1	1.0
Total	100	100.0



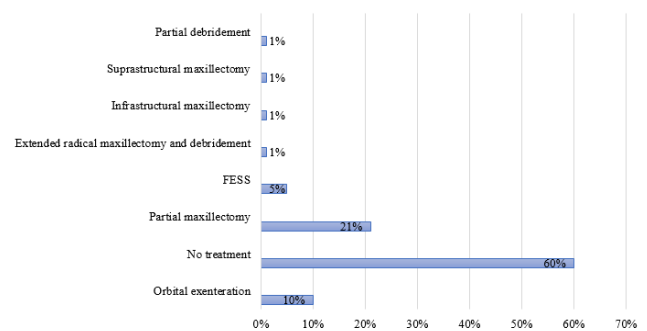
**Fig. 1:** Histopathology showing results after KOH mount examination for confirmation of mucor-mycosis



**Fig. 2:** Co morbidities present in our study group



**Fig. 3:** Medical treatment given in our study group



**Fig. 4:** Surgical treatment given to patients in our study group

Injections, combination of Meropenem, Amphotericin and Fluconazole was given in 22(32.0%) patients with P value <0.001. Table 5

The table shows apposite correlation between surgical management and anterior segment findings with P value=0.79. 44 patients with periorbital (65.7%) received no surgical management while 13 patients (19.4%) underwent partial maxillectomy. 7 patients (35%) patients with restriction of extraocular muscle movements and non-reactive pupil underwent no procedure while 6 patients

**Table 5:** Correlation of Medical treatment with Anterior segment findings

	No.	Periorbital swelling	Extraocular muscle restriction with lacrimal sac obstruction	Mild proptosis with non-reactive pupil	Restriction of extraocular muscles movements	Restriction of extraocular movements with non-reactive pupil	Proptosis	Total
Injection Meropenem and Amphotericin B	No. 1 % 1.5%	2 33.3%	0	0	0	1 5.0%	0	4 4%
30mg Tablet Posaconazole	No. 43 % 64.2%	3 50%	3 100%	1 50%	11 55%	2 100%	63 63%	
Injection Meropenem, Amphotericin, Linezolid Fluconazole	No. 0 %	0	0	0	0	0	0	1 1%
Injection Meropenem Amphotericin and Fluconazole	No. 22 % 32.8%	0	0	0	0	8 40%	0	30 30%
Injection and tablet Meropenem and Amphotericin	No. 0 %	1 16.7%	0	0	0	0	0	1 1%
Injection Ceftriaxone	No. 1 % 1.5%	0	0	0	0	0	0	1 1%
Total	No. 67 % 100%	6 100%	3 100%	2 100%	20 100%	2 100%	100 100%	

$\chi^2=85.71$ ,  $P<0.001$ , HS

**Table 6:** Correlation of Surgical treatment with anterior segment findings

	No.	%	Periorbital swelling	Extraocular muscle restriction with lacrimal sac obstruction	Mild proptosis with non-reactive pupil	Restriction of extraocular muscles movements	Restriction of extraocular movements with non-reactive pupil	Proptosis	Total
Orbital exenteration	5	7.5%	2	0	0	0	3	0	10
			33.3%				15.0%		10%
No treatment	44	65.7%	4	1	2	2	7	2	60
			66.7%	33.3%	100%		35%	100%	60%
Partial Maxillectomy	13	19.4%	0	2	0	0	6	0	21
				66.7%			30%		21%
FESS	4	6%	0	0	0	0	1	0	5
Extended radical maxillectomy	0	0	0	0	0	0	5	0	5
Infrastructural maxillectomy	0	0					5%		1
Supra-structural maxillectomy	1	1.5%	0	0	0	0	1	0	1
							5%		1%
Partial debridement	0	0	0	0	0	0	0	0	1
							5.0%		1%
Total	67	100%	6	3	2	2	20	2	100
			100%	100%	100%	100%	100%	100%	100%

$\chi^2=28.01, P=0.79, NS$

**Table 7:** Correlation of medical treatment with posterior segment findings

	No.	None	Moderate non proliferative diabetic retinopathy	Mild non proliferative diabetic retinopathy	Grade 3 hypertensive retinopathy with mild non proliferative diabetic retinopathy	Grade 3 hypertensive retinopathy	Central artery retinal occlusion	Total
Injection Meropenem and Amphotericin B	No. %	1 1.2%	1 100%	0	1 14.3%	1 25.0%	0	4 4%
30mg Tablet Posaconazole	No. %	58 68.2%	0	2 100%	1 14.3%	2 50%	0	63 63%
Injection Meropenem, Amphotericin, Linezolid Fluconazole	No. %	1 1.20%	0	0	0	0	0	1 1%
Injection Meropenem Amphotericin and Fluconazole	No. %	24 28.2%	0	0	4 57.1%	1 25%	1 100%	30 30%
Injection and tablet Meropenem and Amphotericin	No. %	0	0	0	1 14.3%	0	0	1 1%
Injection Ceftriaxone	No. %	1 1.2%	0	0	0	0	0	1 1%
Total	No. %	85 100%	1 100%	2 100%	7 100%	4 100%	1 100%	100 100%

$\chi^2=53.94, P<0.001, HS$

**Table 8:** Correlation of Surgical treatment with posterior segment findings

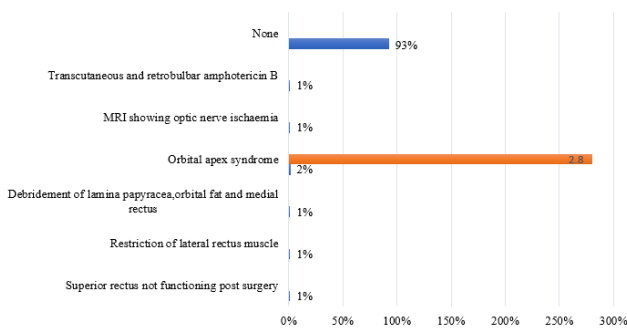
	No.	%	None	Moderate non proliferative diabetic retinopathy	Mild non proliferative diabetic retinopathy	Grade 3 hypertensive retinopathy with mild non proliferative diabetic retinopathy	Grade 3 hypertensive retinopathy	Central retinal artery occlusion	Total
Orbital exenteration	7	81.2%	1	100%	1	14.3%	0	0	10
No treatment	52	61.2%	0	0	1	57.1%	3	0	60
Partial maxillectomy	19	22.4%	0	0	0	14.3%	0	1	21
FESS	4	4.7%	0	0	0	0	1	0	5
Extended radical maxillectomy	1	1.2%	0	0	0	0	0	0	1
Infra-structural maxillectomy	1	1.2%	0	0	0	0	0	0	1
Supra-structural maxillectomy	1	1.2%	0	0	0	0	0	0	1
Partial debridement	0	0	0	0	0	14.3%	0	0	1
Total	85	100%	1	100%	2	100%	4	1	100

$\chi^2=35.85$ ,  $P=0.43$ , NS

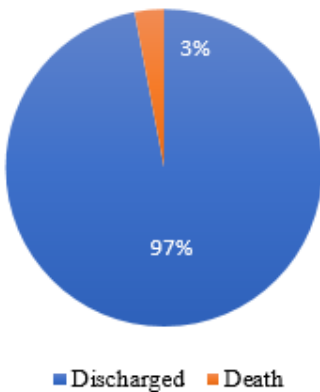
**Table 9:** Shows the correlation between co-morbidities and prognosis of the patients in the study group

Co-morbidities		Discharge	Death	Total
Diabetes	No.	31	1	32
	%	96.9%	3.1%	100%
Diabetes and Hypertension	No.	11	0	11
	%	100%		100%
Diabetes, Hypertension and Ischemic heart disease	No.	2	0	2
	%	100%		100%
Diabetes and pneumonia with long term steroid usage	No.	1	0	1
	%	100%		100%
Hypertension	No.	2	0	2
	%	100%		100%
Pneumonia with long term steroid usage	No.	0	1	1
	%		100%	100%
Pneumonia with steroid use and acute kidney injury with long term hospitalization	No.	0	1	1
	%		100%	100%
None	No.	49	0	49
	%	100%		100%
Chronic kidney disease with long term hospitalization	No.	1	0	1
	%	100%		100%
Hypertension with chronic kidney disease and long-term hospitalization	No.	97	3	100
	%	97%	3%	100%

$X^2=66.71, P<0.001, HS$



**Fig. 5:** Other complications and presentations of the patients in our study group



**Fig. 6:** Prognosis of the patients in the study group

(30%) underwent partial maxillectomy. Table 6

There was a positive correlation between medical management and posterior segment findings with  $P$  value  $< 0.001.58$  patients (68.2%) with normal posterior segment had no treatment while 24 patients (28.2%) received Injection Meropenem, Fluconazole and Amphotericin. 4 patients (57.1%) with grade 3 hypertension and mild non proliferative diabetic retinopathy received Injection Meropenem, Amphotericin and Fluconazole. Table 7

There was a positive correlation between posterior segment findings and surgical management with  $P$  value  $= 0.43$ . 7 patients (81.2%) with normal posterior segment underwent orbital exenteration and 52 (61.2%) had no treatment. Table 8

The table shows correlation of co-morbidities and prognosis. 31 (96.9%) diabetics were discharged while 1 patient amongst 3 deaths was a diabetic which is significant. 100% of patients with Pneumonia and Acute kidney injury with long term hospitalization and long term steroid usage experienced mortality while remaining patients were discharged with vast morbidities. Table 9

**4. Discussion**

Mucor mycosis is more commonly seen in patients with immunological suppression, like chronic uncontrolled steroids, chronic kidney disease on dialysis, long term inhalational steroids for pneumonia, malignancies, post organ transplantation and malnutrition. Although it can involve most organs in the body, rhino-orbito-cerebral type



is the most common. Thrombosis with inflammation and necrosis of the underlying tissue with infiltration of cells like eosinophils and giant cells is the pathology. It can be differentiated from other fungi by its hyphae diameter, branching angle, black pigmentation and classical clinical signs like periorbital edema, pain, loss of vision, necrosis with black eschar, facial pain, cranial nerve palsies and blood-tinged discharge.<sup>8</sup>

A multicentric study conducted by Prakash et al in 2019 in 388 patients who were confirmed or suspects of COVID 19, showed that 18% had diabetic ketoacidosis and 57% patients had uncontrolled diabetes.<sup>9</sup> Patel et al, in India showed in their study that rhino-orbital type was most common, 67.7% with diabetics and patients with malignancies comprising 73.5% and 9% totally.<sup>10</sup> Diabetes increases risk of mucor mycosis by 7.5-fold (Odd ratio 7.55. P=0.001).<sup>11</sup> In the study conducted by John et al, 93% had diabetes and 88% on long term usage of corticosteroids. Precipitation of ketoacidosis and acidic Ph is fertile for spore germination.<sup>12</sup> Steroids suppress phagocytic activity of white blood cells and suppress defense mechanisms. Expression of glucose regulator proteins and availability of free iron for chelation damages endothelium of cells and causes thrombosis, Angio invasion and tissue necrosis.<sup>13</sup>

## 5. Conclusion

The rising cases of mucor in India can be due to high genetic predisposition of patients to diabetes and hypertension which remain undiagnosed for a long time due to vast majority belonging to low socio-economic strata which could be the reason for delayed diagnosis and treatment. Moreover, patients belonging to the working class cannot afford expensive investigations and treatment. Chronic kidney disease is indirectly related to metabolic syndrome. Long term steroid usage amongst asthma, pneumonia due to pollution, organ transplant patients and genetic predisposition of patients to these diseases can also cause immune suppression. In order to contain symptomatology and grave prognosis amongst patients, early diagnosis, affordable treatment and follow-up including patient education about the etiology and pathogenesis of the disease must be available.

## 6. Source of Funding

None.

## 7. Conflict of Interest

None.

## References

1. Mohan BS, Nambiar V. COVID 19: An insight into SARS-CoV Pandemic Originated at Wuhan City in Hubei Province of China. *J Infect Dis Epidemiol.* 2020;6:146. doi:10.23937/2474-3658/1510146.
2. Raut A, Huy TN. Rising incidence of mucormycosis in patients with COVID-19: another challenge for India amidst the second wave? *Lancet Respir Med.* 2021;9(8):265-9. doi:10.1016/S2213-2600(21)00265-4.
3. Pan American Health Organization/ World Health Organization. Epidemiological Alert: COVID-19 associated Mucor mycosis. 11 June, Washington D.C.: PAHO/WHO; 2021.
4. Chakravarti J, Gupta M, Tilak R, Kumar R, Maurya RP, Nilesh K, et al. COVID-19-associated Mucormycosis: A clinic-epidemiological study. *J Diabetes Complications.* 2022;36(9):108284. doi:10.1016/j.jdiacomp.2022.108284.
5. Chandra S, Rawal R. The surge in Covid related mucormycosis. *J Infect.* 2021;83(3):381-412. doi:10.1016/j.jinf.2021.06.008.
6. Maurya RP. Indications for orbital exenteration in COVID-19 associated Rhino-orbito-cerebral Mucormycosis. *IP Int J Ocul Oncol Oculoplast.* 2021;7(2):105-8. doi:10.18231/j.ijoo.2021.023.
7. Aggrwal SK, Maurya RP. Invasive Sino-orbito-cerebral Mycosis: An overview. *Ind J Clin Exp Ophthalmol.* 2015;1(3):149-55.
8. Sugar AM. Mucormycosis. *Clin Infect Dis.* 1992;14(Suppl 1):126-9. doi:10.1093/clinids/14.supplement\_1.s126.
9. Prakash H, Ghosh AK, Rudramurthy SM, Singh P, Xess I, Savio J, et al. A prospective multicentric study on mucor mycosis in India: epidemiology, diagnosis and treatment. *Med Mycol.* 2019;57(4):395-402. doi:10.1093/mmy/myy060.
10. Patel A, Kaur H, Xess I. A multicentric observational study on the epidemiology, risk factors, management and outcomes of mucor mycosis in India. *Clin Microbiol Infect.* 2020;26(7):944.e9-e15.
11. Bala K, Chander J, Handa U. A prospective study of mucor mycosis in north India: experience from a tertiary care hospital. *Med Mycol.* 2015;53(3):248-57.
12. John TM, Jacob CN, Kontoyiannis DP. When uncontrolled diabetes mellitus and severe COVID 19 converge: the perfect storm for mucor mycosis. *J Fungi.* 2021;7(4):298.
13. Baldin C, Ibrahim AS. Molecular mechanisms of mucor mycosis-The bitter and sweet. *pLoS Pathog.* 2017;13(8):1006408.

## Author biography

**Madhusudhan C N**, Professor

**Raghavendra R**, Associate Professor

**Nischala Balakrishna**, Senior Resident

**DN Prakash**, Professor

**K Satish**, Professor and HOD

**Cite this article:** Madhusudhan C N, Raghavendra R, Balakrishna N, Prakash DN, Satish K. Clinical presentations, epidemiology and management of COVID-19 associated Mucor mycosis in a tertiary care hospital in South India. *IP Int J Ocul Oncol Oculoplasty* 2023;9(1):7-15.