

Content available at: <https://www.ipinnovative.com/open-access-journals>

IP International Journal of Ocular Oncology and Oculoplasty

Journal homepage: <https://ijooo.org/>

Original Research Article

Anophthalmic socket syndrome: Management and cosmetic outcome

Farzana Afzal^{1,*}, Sadia Sultana¹, Riffat Rashid¹, Syeed Mehbub Ul Kadir²¹Dept. of Oculoplasty, Ispahani Islamia Eye Institute and Hospital, Dhaka, Bangladesh²Dept. Orbit and Ophthalmic Plastic Services, Sheikh Fazilatunnesa Mujib Eye Hospital and Training Institute, Ghonapara, Bangladesh, India

ARTICLE INFO

Article history:

Received 10-03-2023

Accepted 25-03-2023

Available online 26-05-2023

Keywords:

Anophthalmic socket syndrome

Symbplepharon

Conjunctival granuloma

ABSTRACT

Purpose: To describe the management strategy and evaluate the outcome of Anophthalmic socket syndrome.**Materials and Methods:** This retrospective case study includes 40 patients with anophthalmic socket syndrome who attended the orbit and ocular oncology department of Ispahani Islamia Eye Hospital from January 1, 2018, to June 31, 2021 were included in this study. All the information regarding age, gender, initial pathology, type of initial surgery, implant, degree of contraction, the procedure of socket reconstruction, the management outcome and complication were recorded and analyzed correctly.**Results:** 17 males (42.5%) and 23 females (57.5%) with a mean age of 24.47 years were included in the study. Trauma (30%) and Tumour (25%) were the main reasons for initial eye removal. Enucleation performed in 24 (60%) cases was the most common initial surgery. The primary implant was not done in 20 (50%) cases. Mild socket contraction (grade 1) was recorded in 10 (25%) cases. Moderate contraction (grade 2 and 3) in 25(62.5%) cases and severe contraction (grade 4) in 5(12.5%) cases were recorded. Only fornix forming suture was done in 10 (25%) cases, mucous membrane graft (MMG) was done in 27 (67.5%) cases and dermis fat graft was done in 3 (7.5%) cases. All the patients were followed up routinely for six months. The outcome was good in 16 (40%) cases, acceptable in 20 (50%), and poor in 4 (10%) cases. A common complication was infection (5%) and fat atrophy (5%).**Conclusion:** Anophthalmic socket syndrome remains a challenging entity for the oculoplastic surgeon. Multiple factors help to determine the overall prognosis of socket reconstruction. The goal of management is to provide a socket that can maintain a cosmetically acceptable prosthesis. Timely detection, proper correction of the underlying pathology and a high level of care directly correlate with expected surgical outcomes.This is an Open Access (OA) journal, and articles are distributed under the terms of the [Creative Commons Attribution-NonCommercial-ShareAlike 4.0 License](https://creativecommons.org/licenses/by-nc-sa/4.0/), which allows others to remix, tweak, and build upon the work non-commercially, as long as appropriate credit is given and the new creations are licensed under the identical terms.For reprints contact: reprint@ipinnovative.com

1. Introduction

There are situations when keeping the eye ball preservation is impossible, functionality is lost, and the patient is in severe pain or aesthetic requirements are higher than to alleviate severe pain, protect a healthy contralateral eye, improve aesthetics or even save a patient's life, the

eyeball must be removed. Although this approach solves the patient's health problem, it can devastate their perception and self-confidence. Though the patient's visual function cannot be recovered, the doctor should take all measures to offer the patient an ideal ocular prosthesis so that he can have a "normal" look after surgery.¹ A contracted socket is a grievous complication of a surgical Anophthalmic socket, resulting in the unable to retain a ocular prosthesis. It is not a common problem but significant cosmetic concern for

* Corresponding author.

E-mail address: farzanaafzal82@gmail.com (F. Afzal).

ophthalmic plastic surgeon.²

Anophthalmic socket syndrome is the combination of contracted Anophthalmic socket, cosmetically significant volume deficit and additional pathologies like the fibrous band, symblepharon, conjunctival granuloma, entropion, ectropion, ptosis and many more. Many factors, including fibrosis due to initial trauma, poor surgical technique, multiple socket procedures, irradiation, alkali burns, and cicatrizing disease of the conjunctiva, maybe the reason for socket contraction.³ A contracted socket may occur any times from weeks to years after primary surgery.² While historically it was believed that the sulcus deformity, volume deficit, symblepharon and other pathologies associated with Anophthalmic socket syndrome were incurable,⁴ advances in the using grafting materials, alloplastic implants, and flaps have allowed contracted sockets to be reformed successfully, therefore returning the function of the normal fornix.³

In this study, we present our experience with patients attending with Anophthalmic socket syndrome. We intend to evaluate the demographic features of the patients, presenting pathologies along with gradings, different management techniques to treat the underlying pathologies and ultimate cosmetic outcome.

2. Materials and Methods

It is a retrospective case series. Forty patients with anophthalmic socket syndrome who were referred to the Oculoplasty and Ocular Oncology Department of Ispahani Islamia Eye Hospital from Jan 1 2018, to Jun 31 2021, were enrolled for the study. Patients, irrespective of age and gender, with anophthalmic socket syndrome (ASS) of grade 1 to grade 4 were included. Grade 5 socket contraction and cases with continuous progression of cicatrizing disease were excluded from the study.

Detailed history was taken in every patient. All eyes underwent thorough oculoplastic examination. The degree of contraction was classified as mild, moderate, and severe. Reasons for eye removal, type of initial surgery, and presence of an implant were recorded. Grading of socket contraction and other pathologies accompanying contraction was detected. All patients gave informed consent. A small group of 4 skilled surgeons performed the surgery. Surgeries were performed for the contracted socket, and additional pathologies were recorded. The final status was classified as good, acceptable, and poor. An ocular prosthesis was given after six weeks of surgery. All patients were followed up routinely for at least six months. All data are appropriately assessed and recorded. Tenets of Helsinki were followed in the study.

2.1. Grading of socket contraction

1. Grade 0: A healthy socket with deep and well-formed fornices.
2. Grade 1: Shallowing of the lower fornix.
3. Grade 2: Loss of the superior and inferior fornix.
4. Grade 3: Involvement of all four fornices
5. Grade 4: grade 3 with a reduction in the horizontal palpebral fissure
6. Grade 5: Recurrence of contraction after repeated failed attempts of Reconstruction

2.2. Surgical options

1. Management of shallow fornix can be successfully managed by fornix forming suture. Three double-arm 4-0 silk sutures are passed from the inferior fornix's depth. The needle engaged the periorbita and emerged through the skin near the inferior orbital rim. The double-armed suture is then tightened over a bolster on the skin.⁵
2. Management of socket contracture: Full-thickness mucous membrane grafting (MMG) is the most widely performed procedure for surface expansion of the socket.¹ The preferred donor sites for MMG are the oral mucosa of lips. The harvested graft must always be 30% bigger than the anticipated area to allow for subsequent shrinkage and healing.¹ The use of cautery was avoided when possible.
3. Correction of volume deficiency: where volume loss exceeds 50 per cent, MMG alone is insufficient. A secondary orbital implant or a dermis fat graft is required to substitute for the volume loss.¹ Dermis fat graft (DFG) is harvested from the gluteal region's outer and upper quadrant as this prevents damage to the sciatic nerve and doesn't involve the weight-bearing area.¹

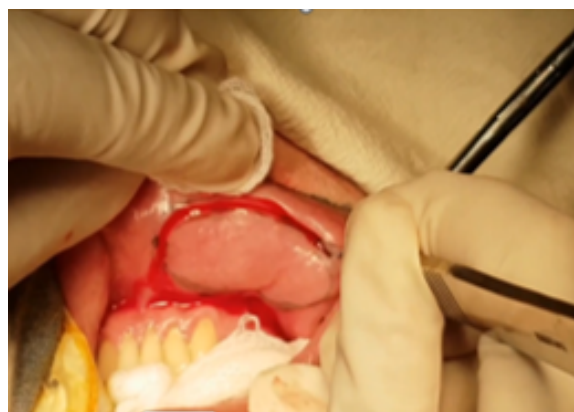

Fig. 1: Harvesting oral mucous membrane graft (MMG)

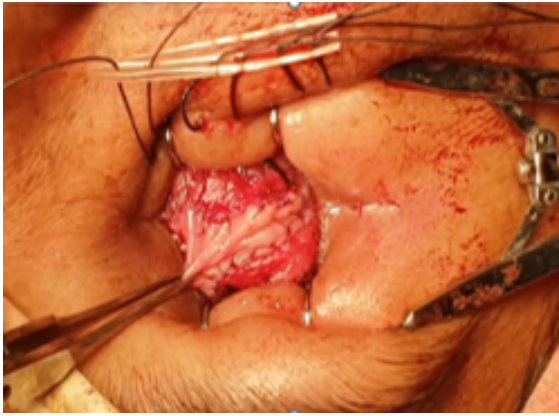

Fig. 2: Expansion of socket by covering bare area of conjunctiva with MMG

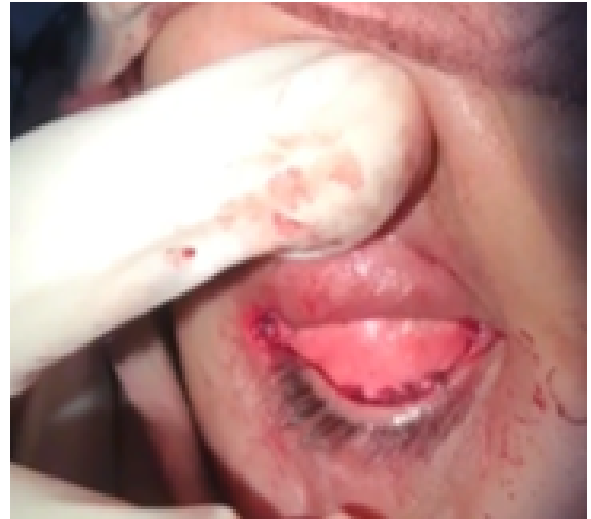

Fig. 5: Volume deficit correction by DFG

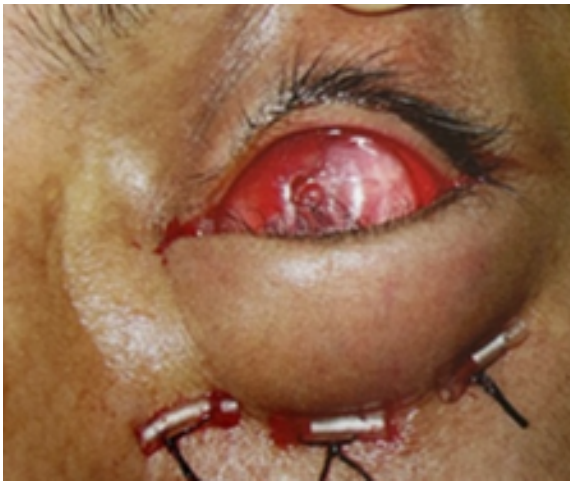

Fig. 3: Fornixforming suture

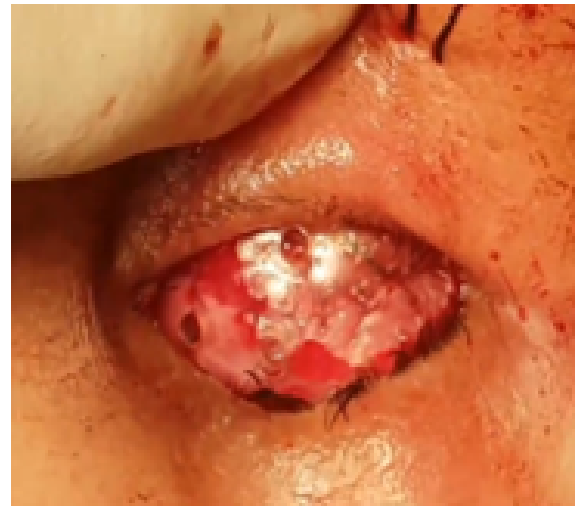

Fig. 6: Confirmmer is placed in the ocular surface

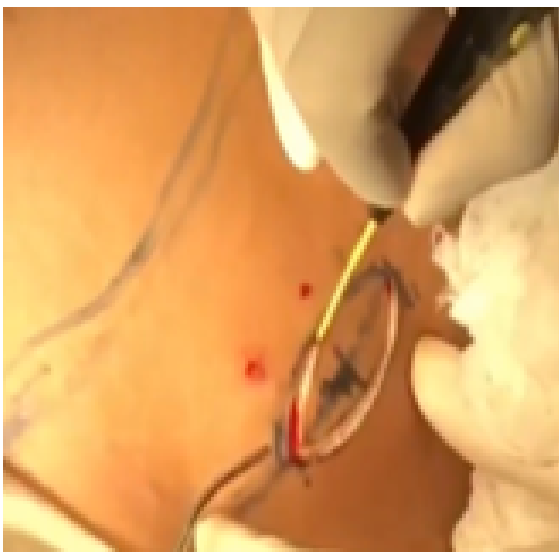

Fig. 4: Harvesting dermis fat graft (DFG)

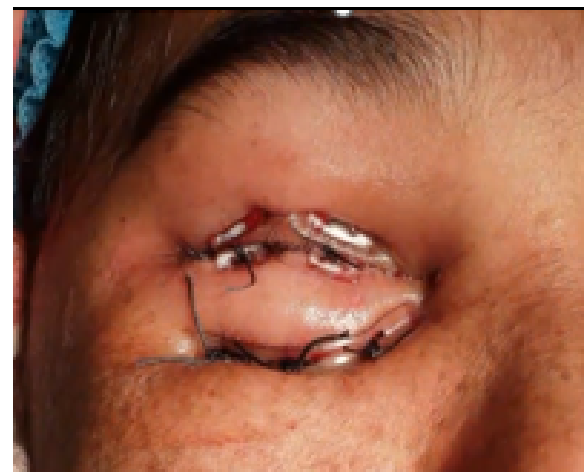

Fig. 7: Tarsorrhaphy

3. Results

Most of the patients presented with socket contraction were in the middle age group (20 to 40 years) (Table 1). The mean age of presentation was 24.47 years. Among 40 patients, 17 (42.5%) were male, and 23 (57.5%) were female, with female to male ratio of 1.35:1.

Table 1: Age distribution

Age (year)	Number (n)	Percentage (%)
< 20 years	13	32.5
≥ 20 year - < 40 year	22	55
≥ 40 years	5	12.5

The most common cause of eye removal was trauma (30%), followed by tumours (25%) and infection (17.5%). Pathology was unknown in 15% of cases (Figure 8).

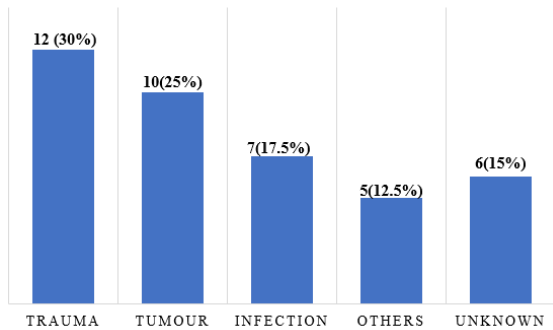


Fig. 8: Aetiology of eye removal

Evisceration was the initial surgery in 16 patients (40%), while enucleation (Figure 9) was done in 24 patients (60%).

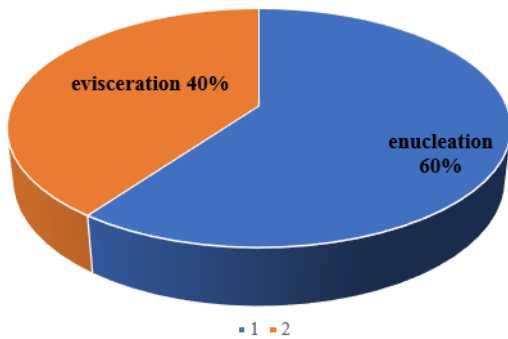


Fig. 9: Types of initial surgery

4. Discussion

The unfortunate loss of an eye causing aesthetic disfigurement of the face significantly affects the individual

Table 2: Degree of contraction

Degree of contraction	Number (n)	Percentage (%)
grade 1	10	25
grade 2	15	37.5
grade 3	10	25
grade 4	5	12.5

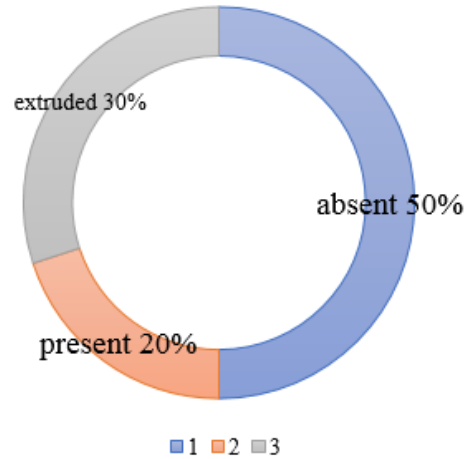


Fig. 10: Presence of primary implant

Table 3: Procedure of socket reconstruction

procedure	Number (n)	Percentage (%)
fornix forming suture	10	25
MMG with FFS	27	67.5
DFG with FFS	3	7.5

Table 4: Outcome of patients

Outcome	Number (n)	Percentage (%)
Good	16	40
Acceptable	20	50
Poor	4	10

Table 5: Post-operative complication

Complication	Number of patients (n)	Percentage (%)
Infection	2	5
Graft necrosis	1	2.5
Fat atrophy	2	5
Granuloma	2	5
Recurrence	1	2.5

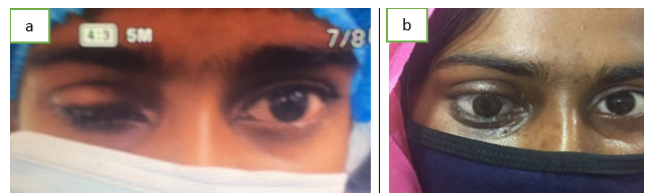


Fig. 11: a: Grade 2 socket contraction in the right eye, b: Insertion of a prosthesis after socket reconstruction.

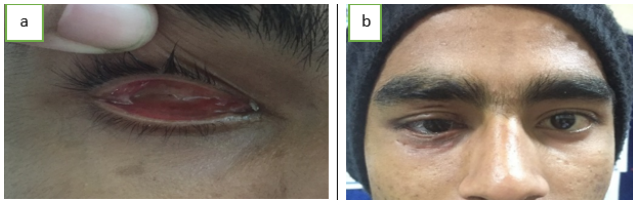


Fig. 12: a: Grade 3 socket contraction, **b:** After ocular prosthesis.

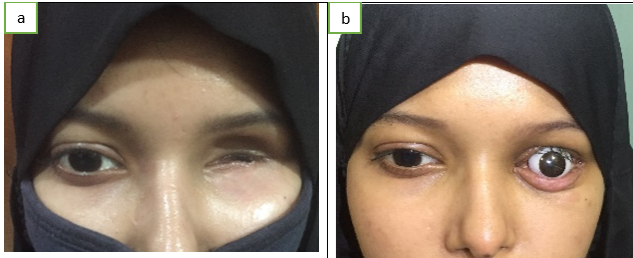


Fig. 13: a: grade 4 socket contraction with a volume deficit; **b:** prosthesis after dermis fat graft

physical, psychological, emotional, and social Well-being. So, the replacement of the anophthalmic socket by an appropriate prosthesis at the earliest period is significant. On the other hand, adequate conjunctival surface and deep fornices are crucial in supporting the cosmetically acceptable prosthesis. Socket contraction is one of the main problems following eye removal.^{3,4} Contraction is a progressive process that reduces socket volume and shortens the conjunctiva and shallow fornices.^{3,6} Management of contracted sockets is challenging. It makes the patient unable to keep the ocular prosthesis in the socket. As oculoplastic surgeons, we aim to form a socket with adequate fornices and conjunctival surface and correction of volume deficit by having an excellent cosmetic result with the ability to wear an acceptable prosthesis.

In this study, we present our experience with patients suffering from anophthalmic socket syndrome. This literature aims to describe the management strategy and evaluate the outcome of ASS.

In a study by Serin D et al., there were 53.72% male and 46.28% female patients, with ages between 1 and 78 years (mean 35.46 years). In our study, the mean age of presentation was 24.47 years. 55% of patients were from the 20 to 40 age group with slight female predominance (female 57.5% and male 42.5%). The slight female predominance of our study may be due to the need for knowledge and awareness of females and family members.

In our case series, the most common cause of eye removal was trauma (30%), followed by tumour (25%) and infection (17.5%). Pathology was unknown in 15% of cases. The aetiology of eye removal differs from area to area and from country to country. In Hirako's study,⁷ traumatic cause of eye removal was noted in 40% of the patients.

Trauma may play a role in contracture by causing tissue loss, promoting inflammation, or disturbing the vascular supply of the socket.

Among our study population, evisceration was the initial surgery in 16 (40%) patients, while enucleation was done in 24 (60%) patients. In a study by Serin D et al., enucleation was the primary surgery in 77.66% of the patients with contracted sockets.³ Enucleation itself is reported to be a possible cause of contraction.⁴ Intraorbital structures are disrupted more in enucleation surgery than in evisceration. Volume loss and the shortening of the conjunctiva must be addressed as two factors to cause contraction after enucleation.

The primary implant was absent in 20 (50%) of our patients. The implant was extruded in 12 (30%) cases later, and in the rest of the 8 (20%) cases, socket contraction occurred despite having a primary implant in situ. 76.06% of patients in a study by Serin D et al. did not have a primary implant.³ In Anophthalmic sockets, especially those without implants, it is reported that myofibroblasts may lead to progressive contraction, and the degree of contraction of the socket is affected mainly by the timing for eyeball implantation.⁸ Primary implant placement after enucleation and evisceration must be considered to reduce the possibility of socket contraction.^{9,10}

Among our 40 patients, 10 (25%) patients had mild socket contraction (grade 1), 25 (62.5%) patients were suffering from moderate (grade 2 and 3) contraction, and 5 (12.5%) patients had a severe contraction. In Serin D's study, moderate or severe contraction was recorded in 134 (71.28%) patients.³ Poorly fitted prosthesis or not wearing a prosthesis for prolonged periods, radiation exposure, Infection, severe injury (trauma/chemical burns) before orbital or recurrent anophthalmic surgery, poor surgical technique (destruction of conjunctiva, traumatic dissection), autoimmune (mucous membrane pemphigoid/Stevens-Johnson Syndrome/toxic epidermal necrolysis are several essential factors to result in socket contraction.¹

In mild socket contraction, fornix forming suture was sufficient to correct the socket contraction (25 % of our cases). Mucous membrane grafting is a well-known technique and was the most performed procedure for socket surface expansion in our series (67.5% cases). We preferred buccal mucosa. If the volume deficit with contraction persisted, we performed dermis-fat grafting (7.5%). Mucous membrane graft is also a well-known technique in other case series.^{11–13}

The degree of contraction inversely correlates with expected surgical outcomes. Mild to moderate sockets will likely have good results with MMGs. Severe contraction, volume deficit, and other cicatrizing diseases are associated with poor outcomes.^{1,5,14} Good or acceptable outcome with conjunctival surface and fornices that allowed the artificial eye to be worn was achieved in 90% (36 patients) of

the patients (Figures 12 and 13). The socket remained insufficient in only 10% (4 patients) of the operated eyes. A severe onset of contraction during the early years after primary surgery was significantly correlated with poor outcomes.³

The common post-operative complication in our case series is infection (5%), granuloma (5%) and fat atrophy (5%) (in dermis fat graft cases). The infection rate is usually higher in the presence of systemic immunosuppression or local orbital conditions such as prior radiation treatment.¹⁵ In dermis fat graft cases, there can be a marked degree of fat atrophy (up to 50%) which can be challenging to predict in adults. This can be overcome by intentionally placing more fat in the socket at the time of surgery.¹⁶ Timely detection and proper correction of the underlying condition causing the contraction are likely to improve the result of Reconstruction.

5. Conclusion

Socket reconstruction is often challenging for an oculoplastic surgeon. A contracted socket is not only a functional problem as well as a cosmetically disabling entity. Prevention is always better than cure. Scrupulous tissue handling during the primary procedure, placement of an adequately sized implant, layered closure over the implant, use of customized prosthesis post-operatively, and regular follow-ups may help prevent this debilitating condition. A lifelong follow-up is recommended to minimize subsequent complications and for the best outcomes. The treatment and the post-operative period demand a high level of care from the patient and the concerned clinician.

6. Conflict of Interest

The authors declare no relevant conflict of interest with respect to research, authorship and or publication of this article

7. Source of Funding

None.

References

1. Schmitzer S, Simionescu C, Alexandrescu C, Burcea M. The Anophthalmic Socket - Reconstruction Options. *J Med Life*. 2014;7:1-6. doi:10.4172/2161-1076.1000203.

2. Foster J. 2017-2018 Basic and Clinical Science Course (BCSC), Section 07: Orbit, Eyelids, and Lacrimal System. American Academy of Ophthalmology; 2017.
3. Serin D, Karslioglu S, Akbaba M, Buttanri IB, Fazil K. Clinical Evaluation of 188 Patients with Contracted Socket. *Surgery Curr Res*. 2014;4:203. doi:10.4172/2161-1076.1000203.
4. Wiener M. Restoration of the Conjunctival Cul de-Sac for the Insertion of an Artificial Eye. *JAMA*. 1908;LI(13):1070-2. doi:10.1001/jama.1908.25410130026002c.
5. Betharia SM, Kumar H. Surgical management of contracted socket. *Indian J Ophthalmol*. 1988;36(2):79-81. [cited 2021 Oct 11].
6. Tyers AG, Collin JR. Orbital implants and post-enucleation socket syndrome. *Trans Ophthalmol Soc U K*. 1982;102(Pt 1):90-2.
7. Yanaga H, Mori S. Eyelids and eye socket reconstruction using the expanded forehead flap and scapha composite grafting. *Plast Reconstr Surg*. 2001;108(1):8-16. doi:10.1097/00006534-200107000-00003.
8. Papel ID, Frodel J, Holt R. Facial Plastic and Reconstruction Surgery. 2nd ed. New York: Thieme Medical Publishers; 2002.
9. Ozgur OR, Akcay L, Dogan OK. Primary implant placement with evisceration in patients with endophthalmitis. *Am J Ophthalmol*. 2007;143(5):902-4. doi:10.1016/j.ajo.2006.11.029.
10. Tawfik HA, Budin H. Evisceration with primary implant placement in patients with endophthalmitis. *Ophthalmology*. 2007;114(6):1100-3. doi:10.1016/j.ophtha.2006.09.027.
11. Miglioni ME. Evaluation and management of the anophthalmic socket, Principles and Practice of Ophthalmic Plastic Reconstructive Surgery. Philadelphia: WB Saunders; 1996.
12. Quaranta-Leoni FM. Treatment of the anophthalmic socket. *Curr Opin Ophthalmol*. 2008;19(5):422-7. doi:10.1097/ICU.0b013e32830b1551.
13. Mai C, Bertelmann E. Oral mucosal grafts: an old technique in a new light. *Ophthalmic Res*. 2013;50(2):91-8. doi:10.1159/000351631.
14. Mavrikakis I, Malhotra R, Shelley MJ, Sneddon KJ. Surgical Management of the Severely Contracted Socket Following Reconstruction. *Orbit*. 2006;25(3):215-9. doi:10.1080/01676830600671383.
15. Vistnes LM, Iverson RE. Surgical Treatment of the Contracted Socket. *Plast Reconstr Surg*. 1974;53(5):563-70.
16. Choi CJ, Tran AQ, Tse DT. Hard palate-dermis fat, composite graft for Reconstruction Reconstruction of contracted anophthalmic socket. *Orbit*. 2018;38(3):199-204. doi:10.1080/01676830.2018.1505920.

Author biography

Farzana Afzal, Assistant Professor

Sadia Sultana, Professor

Riffat Rashid, Associate Professor

Syed Mehabub Ul Kadir, Assistant Professor

Cite this article: Afzal F, Sultana S, Rashid R, Kadir SMU. Anophthalmic socket syndrome: Management and cosmetic outcome. *IP Int J Ocul Oncol Oculoplasty* 2023;9(1):1-6.