

Content available at: <https://www.ipinnovative.com/open-access-journals>

IP International Journal of Ocular Oncology and Oculoplasty

Journal homepage: <https://ijooo.org/>

## Original Research Article

## Accuracy in clinical diagnosis of benign peri-ocular mass lesions

Shashikala P<sup>1</sup>, Shrithi Das Shetty<sup>1,\*</sup><sup>1</sup>Dept. of Ophthalmology, ESIC Medical College & PGIMS & Model Hospital, Rajajinagar, Bengaluru, Karnataka, India

## ARTICLE INFO

## Article history:

Received 10-10-2022

Accepted 08-11-2022

Available online 20-02-2023

## Keywords:

Eyelid

Histo-pathological

## ABSTRACT

**Aim:** To analyze accuracy in clinical diagnosis of peri-ocular benign lesions.**Materials and Methods:** A prospective, interventional study of 279 clinically diagnosed and or histo-pathologically confirmed eyelid mass lesions. At presentation, detailed demographic data, symptoms, duration since the mass noted, its location, size & physical appearance, progression/regression/recurrence of the lid mass if any and associated systemic ailments were noted. Then, a pre-treatment clinical diagnosis (PTCD) was made. The treatment given, its outcome and histo-pathological examination (HPE) report were noted. Results then analysed in terms of how many cases needed HPE and in how many did PTCD match with HPE reports.**Results:** Commonest lesions were of infective type (64.5%) followed by cysts and neoplastic which together contributed for 26.9% cases and others like congenital, traumatic, depositive etc., contributed for 8.6%. Totally, 25.8% sent for HPE; 94.4% did match with PTCD.**Conclusion:** Accuracy in clinical diagnosis is good with a thorough understanding of physical characteristics of lid mass lesions. Studies on a large scale would be extremely beneficial for the practicing ophthalmologists and the training residents and also for public health-care planning.This is an Open Access (OA) journal, and articles are distributed under the terms of the [Creative Commons Attribution-NonCommercial-ShareAlike 4.0 License](https://creativecommons.org/licenses/by-nc-sa/4.0/), which allows others to remix, tweak, and build upon the work non-commercially, as long as appropriate credit is given and the new creations are licensed under the identical terms.For reprints contact: [reprint@ipinnovative.com](mailto:reprint@ipinnovative.com)

## 1. Introduction

Eyelid and the peri-eyelid has skin which is not only the thinnest, but also among the most commonly exposed to sunlight, atmosphere; also, in addition comprise of all skin elements, appendages, muscle, modified glands, and mucous membrane.<sup>1</sup> So, would be a site for varieties of mass lesions. Peri-ocular mass lesions not only could be, cosmetically disturbing to patients but, also may pose diagnostic difficulties to family physicians, dermatologists and ophthalmologists. An understanding of the clinical profile, common physical characteristics and management of these lesions is essential to deal them efficiently and accurately in our routine practice. Many times we may still land up in diagnostic dilemma and may need histo-

pathological evaluation (HPE) to confirm the diagnosis. But, in which and what percentage of lid masses need HPE and how often it does match with our clinical diagnosis needs to be evaluated too. Hence, we designed a prospective, interventional study for which Institutional ethical committee approval was taken.

## 2. Materials and Methods

Aim of this study was to know the accuracy in clinical diagnosis of peri ocular benign mass lesions by analysing what percentage of histo-pathological diagnosis matched with the pre clinical diagnosis among the patients attending the outpatient department of Ophthalmology. We included all benign cutaneous mass lesions in and around the eyelid presenting in both genders, at all ages which may need medical and or surgical care while excluded malignant

\* Corresponding author.

E-mail address: [shri2011@gmail.com](mailto:shri2011@gmail.com) (S. D. Shetty).

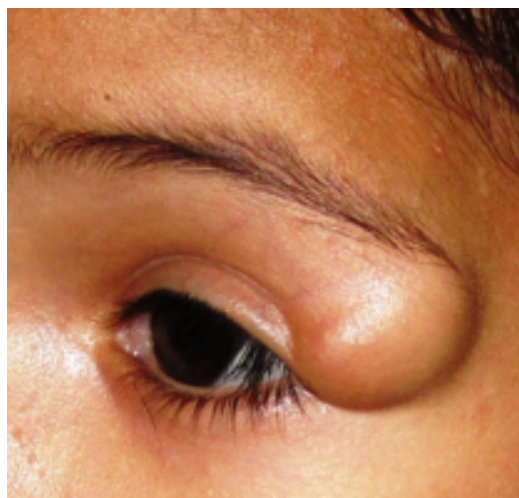lesions.

A total of 279 patients, either clinically diagnosed and or histo-pathologically confirmed benign eyelid masses that were treated between January 2014 and December 2016 were studied. At presentation, a detailed demographic data including age, gender and occupation of the patients, symptoms, the duration since lid mass noted, it's location, size and physical appearance, progression / regression/ recurrence if any and associated systemic ailments were collected. Then, a pre-treatment clinical diagnosis (PTCD) made. The treatment given either medical and or surgical was noted. HPE reports were collected for those cases done for academic interest, to rule out early malignancies and dilemma. Patients were followed for minimum of a week post treatment recovery. The results were then analysed.

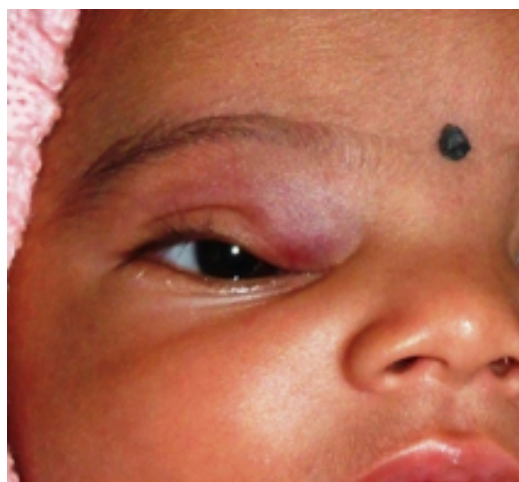### 3. Results

A total of 279 patients, age ranged from 6months to 86yrs; an average 35.3 years with female preponderance in 64.5%. Clinically, we categorized lid mass lesions as congenital, infective, neoplastic, retention cysts, solar keratosis, senile, dipositive and those associated with systemic ailments.<sup>2</sup> Congenital lesions seen were Dermoid cyst which presents as a round cystic subcutaneous mass at the tail end of the eye brow, capillary haemangioma as unilateral raised red lesion which blanch on pressure in 1<sup>st</sup> year of life, may cause mechanical ptosis or epidermal inclusion cyst which are inclusive cyst posing as chalazion.(Figures 1, 2 and 3)

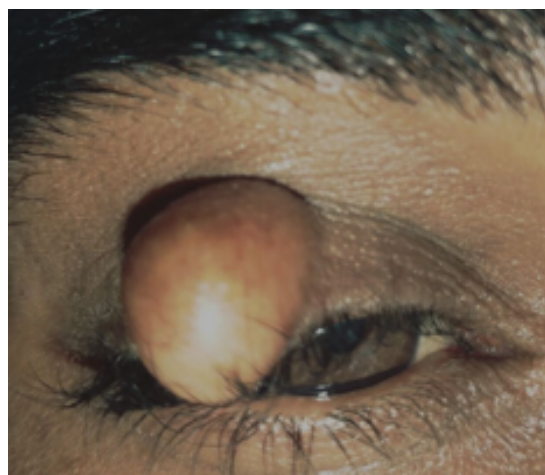
1. Common infective lesions in lid like chalazion and hordeolum internum / styte (an acute inflammation around eyelash), molluscum contagiosum which is a virus infection causing dome shaped swelling with pearly appearance and dimpled centre and keratoacanthoma as hyperkeratotic nodule within a crater caused by human papilloma virus (HPV) along with UV radiation, sebaceous cysts, warts caused by HPV or pyogenic granuloma caused by HPV type 2. (Figures 4, 5 and 6)
2. Hydrocystadenomas may be either transparent cysts of Moll or translucent cysts of Zeiss glands (Figures 7 and 8)
3. Benign neoplastic lesions like Junctional nevus, Papilloma (Figures 9 and 10)
4. Solar radiation induced Detmatosis papulosa nigra (DPN), skin tags, cutaneous horn and solar keratosis. (Figures 11 and 12)
5. Depositive lesions like Xanthelesma(yellow plaque subcutaneously (Figure 13)
6. Lid mass lesions associated with systemic conditions include Syringoma which results due to hyper active sweat glands common in teens and women with Diabetes mellitus or Down's syndrome and also nodules of neurofibromatosis.(Figures 13 and 14)



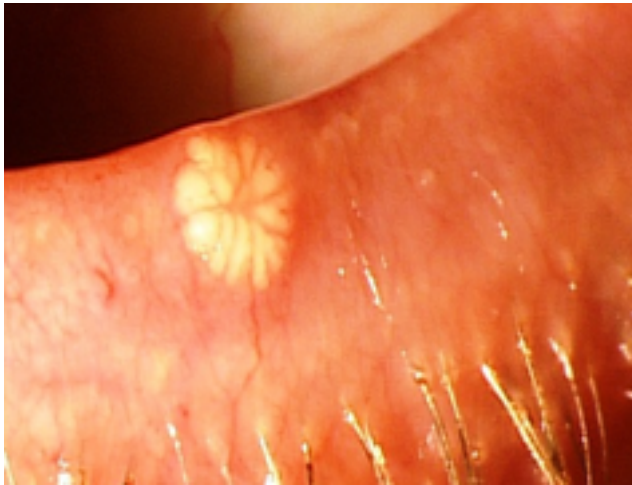**Fig. 1:** Dermoid cyst



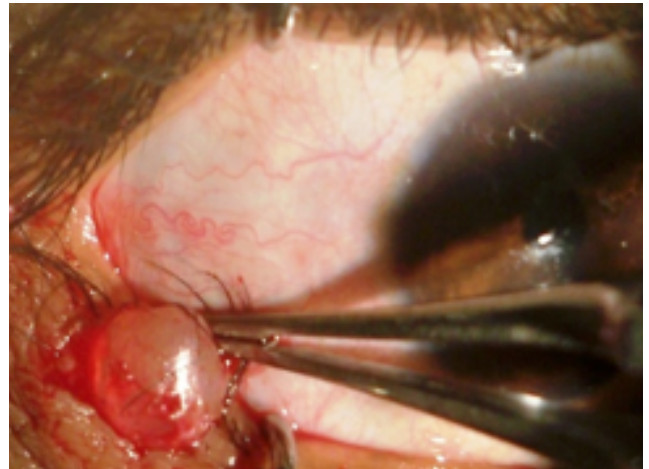
**Fig. 2:** Capillary hemangioma



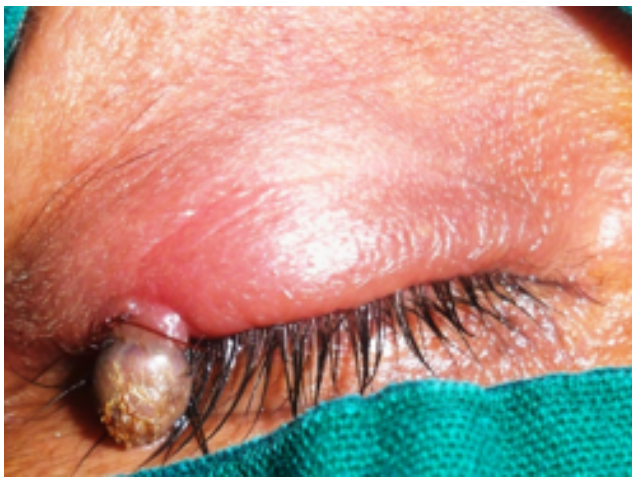**Fig. 3:** Epidermal cyst



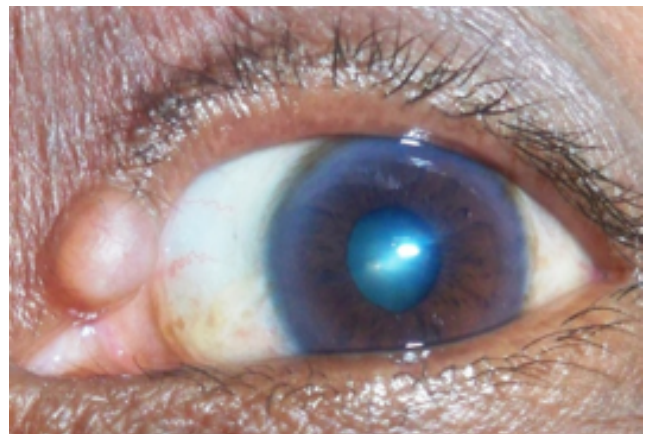
**Fig. 4:** Molluscum contagiosum



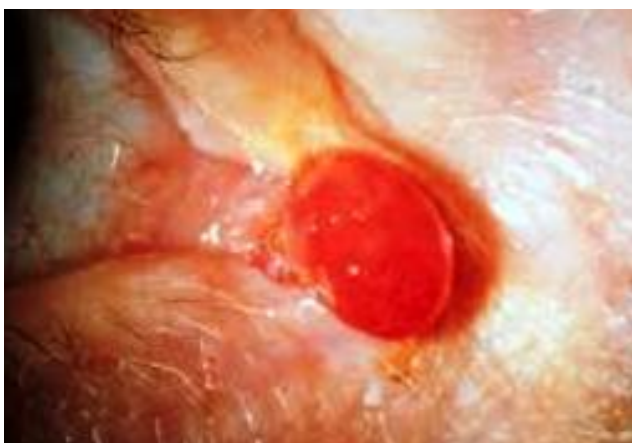**Fig. 7:** Moll cyst



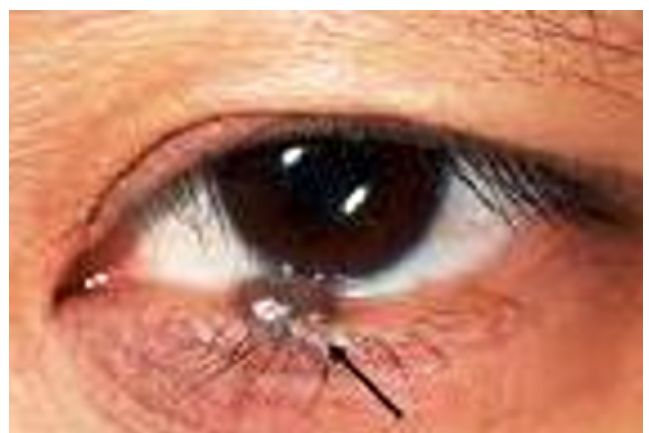**Fig. 5:** Kerato acanthoma



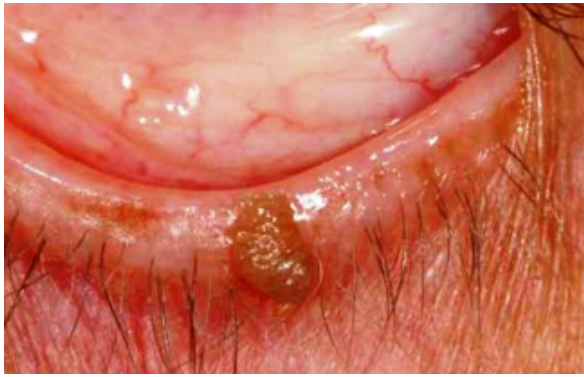
**Fig. 8:** Zeiss cyst



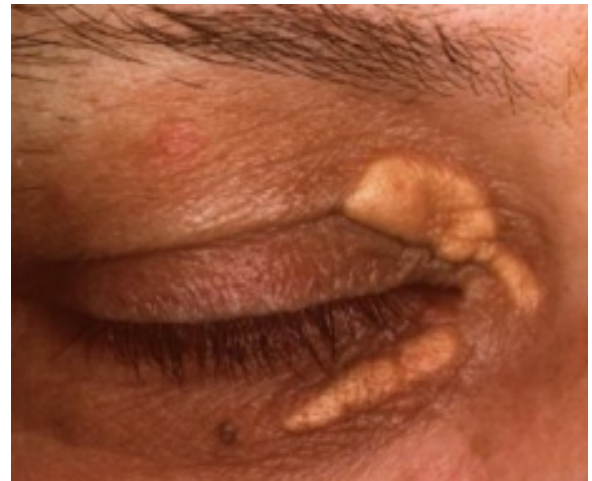**Fig. 6:** Pyogenic granuloma



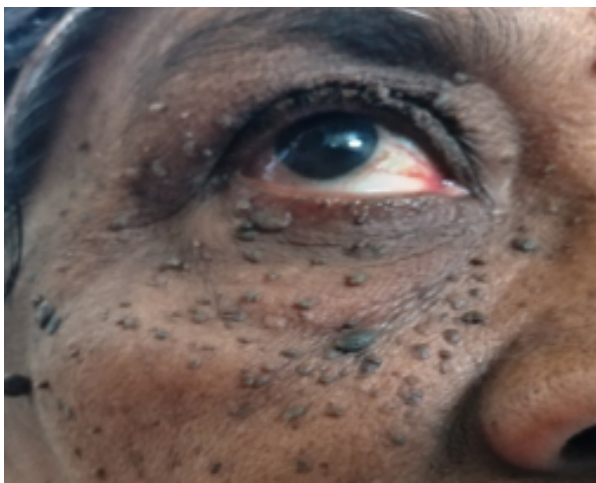**Fig. 9:** Nevus



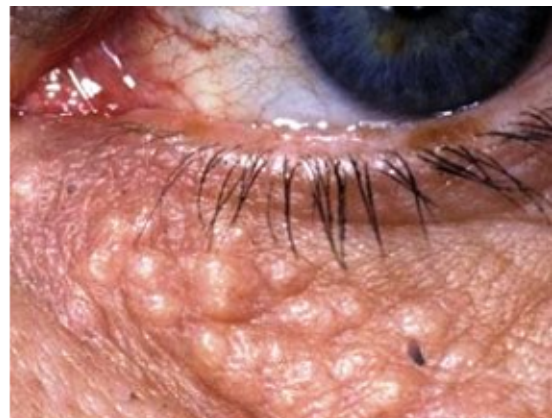**Fig. 10:** Papilloma



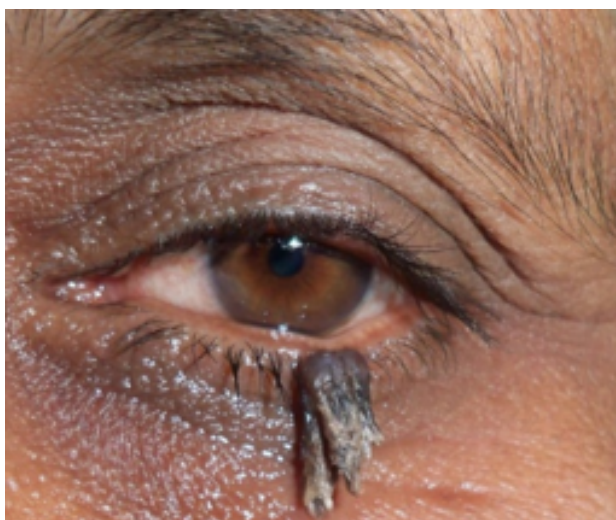**Fig. 13:** Xanthelasma



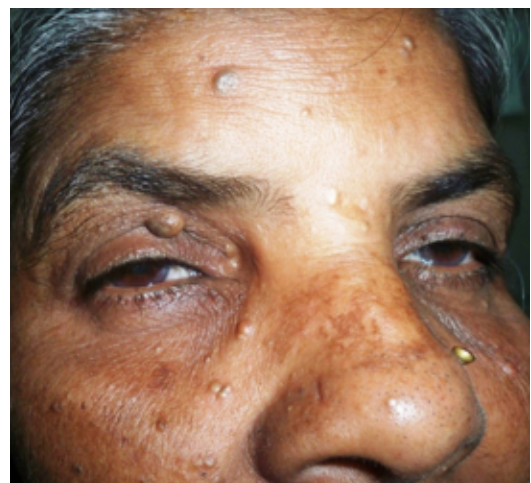**Fig. 11:** Solar keratosis & skin tag



**Fig. 14:** Syringoma

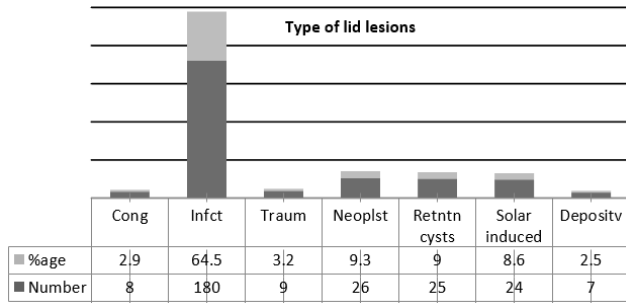


**Fig. 12:** Cutaneous horn



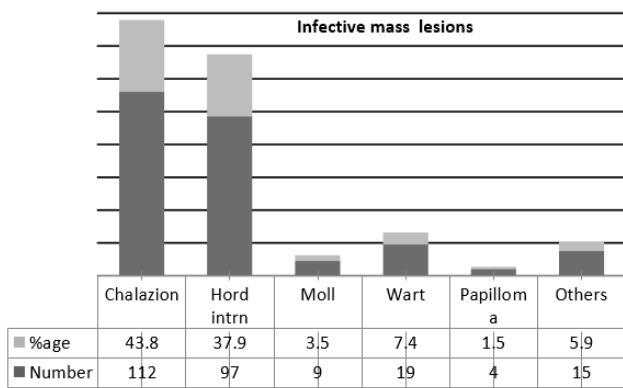
**Fig. 15:** Neurofibroma nodules

Statistical analysis of these clinical types in the present study showed commonest mass lesions were of infective types in 64.5% followed by neoplastic lesions which included lid nevi, Papillomas, Eccrine cysts, solar radiation induced lesions like DPN, solar keratosis, cutaneous horn etc., which together forms 26.9%, while others including congenital, depositive, traumatic, senile comedones etc., forms 8.6%.(Graph 1)



Graph 1: Type of lid mass lesions

Of the infective lesion, Chalazae and Hordeolum externum/stye formed 81.7% while rest is by Molluscum contagiosum, warts and Papillomas.(Graph 2)



Graph 2: Infective mass lesions in and around lid

We did ask for HPE even after making a PTCD in cases with diagnostic dilemma, to rule out early dysplasia or if of academic interest. A few of them are shown in figures like typical cyst wall of Dermoid cyst, typing of nevus possible only on HPE, Keratoacanthoma with keratin pearls in which early dysplasia need to be ruled out, laminated kaeratin in epidermal cyst along with skin components, collection of histiocytes as in Xanthoma etc.,

Here is a table (Table 1) showing how many and for what clinical lesions, HPE was done and how many did match with PTCD. We asked for HPE in 72 Of 279 cases. So, 25.8% specimen went for HPE of which 6 recurrent chalazae of total 112 chalazae were sent for HPE and 2 did not match with the PTCD and were histopathologically diagnosed as epidermal cyst. Six of nine

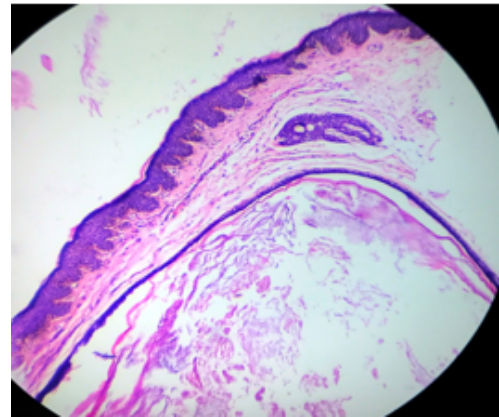


Fig. 16: Dermoid cyst

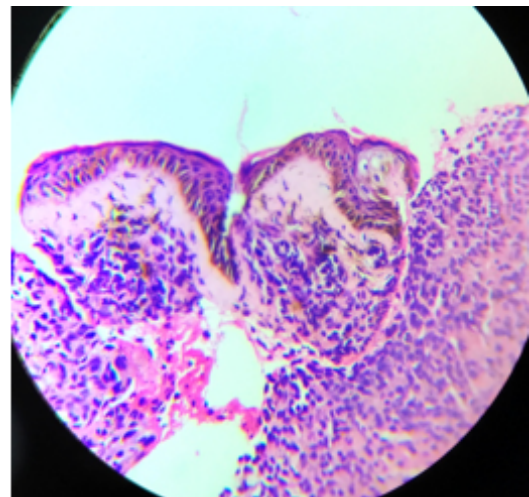


Fig. 17: Intradermal nevus

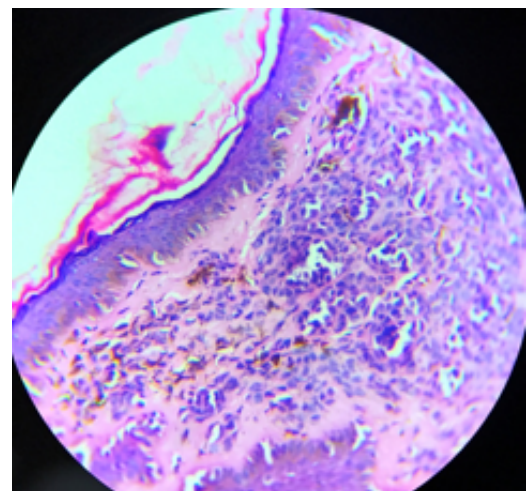
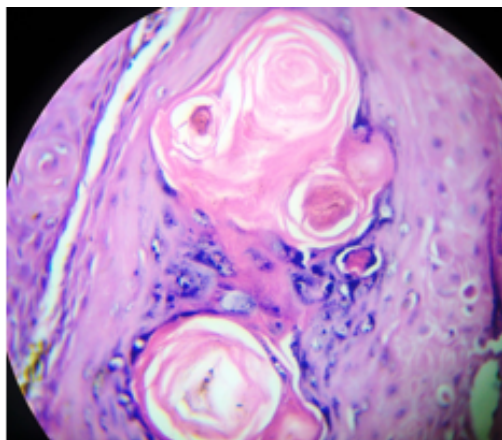
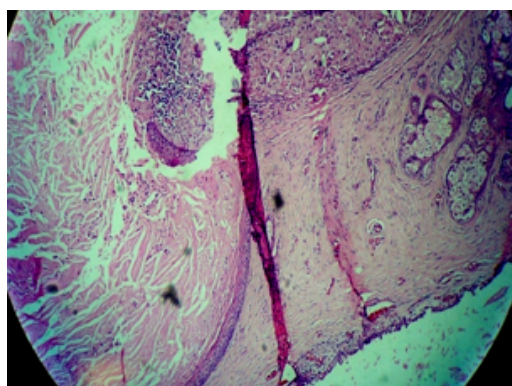


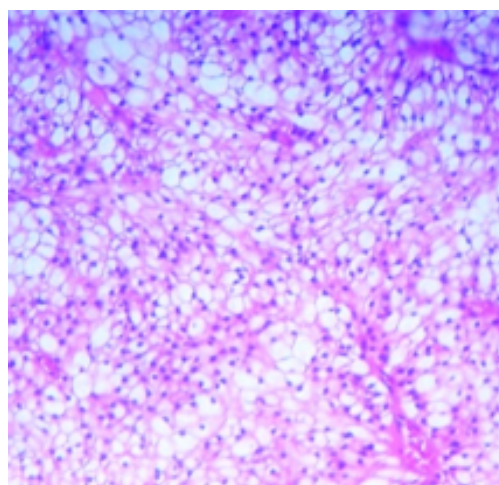
Fig. 18: Compound nevus



**Fig. 19:** Kerato acanthoma



**Fig. 20:** Epidermal cyst



**Fig. 21:** Xanthoma

cases of Molluscum contagiosum were sent for HPE and 5 matched while, one was reported as syringo cystadenoma pappiliferum. Of 20 cases, 19 clinically diagnosed as Keratoacanthoma(2 in number) and wart (17 in number) were sent; except one case of wart which was confirmed as seboric keratosis, rest did match with the PTCD. All cases (5 of 5) of Foreign body and pyogenic granuloma, 15 Of 25 cases of Hydrocystadenoma and 21 Of 22 cases clinically diagnosed as Nevus and Papilloma cases were sent for HPE and they all did co relate with the PTCD. In total, HPE reports did not match with PTCD in 5.4% while matched with PTCD in 94.4%.

**Table 1:** Analysis of PTCD co-relation with HPE reports

PTCD	No.	% age	HPE-same as PTCD	HPE-Differed from PTCD
Rec.Chalazia	6/112	5.6	4/6(66.6%)	2/6(33.3%) EDC
Moll. contagiosum	6/9	66.6	5/6(83.3%)	1/6(16.7) SCP
Hydrocystadenoma	15/25	92	100(15/15)	0
Keratoacanthoma+ warts	19/20	55	18/19(90.9%)	1/ 11(5.2%) SK
Nevus+ papilloma+ SK	21/22	95.4	21/21 (100%)	0
Fb + Pyogenic granuloma	5/5	100	100	0
Total	72/279	25.8%	94.4%	5.6%

EDC- Epidermal cyst, SK- Seborrhic keratosis, SCP-Syringo cystadenoma pappiliferum

Common associations found in this study are as follows

1. Chalazae and internal hordeolum are seen more in association with seborrhoea in 81.9%, at young Age (average 17.6yrs) and females.
2. Skin tags, Comedones, Solar keratosis with senility and exposure to sunlight in 91.8%.
3. Xanthelesma, Syringoma seen often in association with Diabetic mellitus in 97.2%.

#### 4. Discussion

Wide varieties of lesions like congenital, inflammatory, traumatic, neoplastic etc., affecting the eyelid are encountered in routine ophthalmology practice. These lesions are numerous due to the unique anatomical features of the eyelid having all skin elements.<sup>2</sup> Aside from aesthetic point of view, cutaneous peri-ocular mass lesions can block vision or alter the normal shape of the eyelids.

Most eyelid mass lesions in the present study occurred in relatively young individuals with an average age being 35.3 years as in other studies Yanoff M Ocular pathology Ocular melanocytic tumors, 2002 and G. Sotiropoulos et al.,

“Eyelid tumors at the university eye clinic. MEAJO 2015.<sup>3</sup>

Though majority of the studies showed no gender predilection, our study had female predilection, could be because infective lesions were more in females. The commonest peri-ocular mass lesions are of infective type (64.5%) with Chalazion as the most common lid lesion, similarly faced by other ophthalmologists.<sup>4,5</sup> Recurrent chalazion was the most common indication for chalazion biopsy as sebaceous cell carcinoma (SGC) as some cases of SGC can mimic this lesion.<sup>6</sup> One study reported as much as 20% of sebaceous carcinomas were initially misdiagnosed as recurrent chalazion.<sup>7</sup> In our study, 2 of recurrent chalaziae were misdiagnosed instead of epidermal cyst. Hence, indications for histopathological evaluation included recurrent chalazion, associated fleshy mass, abnormal content, fibrosed chalazion and extraordinarily large chalazion.

Papillomatous skin lesions are a wide descriptive name rather than a true clinical diagnosis that makes them very tricky. The lack of clear clinical sub-classification may lead to misdiagnosis or even mislabel malignant lesions as benign ones.<sup>8</sup> In this study, skin tags, warts and seborrheic keratosis were specifically mentioned clinically and clearly evaluated as separate subgroups of the papillomatous lesions, therefore no malignant lesion has been unexpectedly missed. The absence of the characteristic raspberry-like surface with same or slightly darker color of the skin was the common pathognomonic sign that was considered essential to rule out malignant forms.<sup>9</sup>

Molluscum contagiosum has peculiar clinical feature with high accuracy of clinical diagnosis.<sup>10</sup> Except one which was seen in elderly female, all of our cases were seen in otherwise normal children and that unexpectedly turned out as syringocystadenoma papilliferum on HPE.

Nevus were relatively less in our series, could be because ours is a tertiary care hospital. Compound nevus was the most common, similar to one reported by Hsu and Lin.<sup>11</sup> In our study, nevi were sent for HPE for 2 reasons; one for histo-pathological typing and secondly to rule out malignant potential especially in junctional nevi since, Intradermal nevi showed no malignant potential, while junctional nevus, had low malignant potential as reported by Chi and Beak.<sup>12</sup>

Histopathologic evaluation of wart (verruca) is important in terms of eradication of the disease and prevention of spreading of this papillomatous lesion as it has viral origin.

Seborrheic keratosis (basal cell papilloma) is another papillomatous lesion which can mimic other benign and malignant lid lesions owing to its clinical variability.<sup>8</sup>

Capillary hemangioma is frequently seen in pediatric population but rarely treated by surgical excision which explains the rarity of such a lesion in our study too.<sup>13</sup>

The other one was a rapidly growing, pedunculated, red lesion with bleeding, which placed keratoacanthoma in the differential diagnosis.<sup>9</sup>

Xanthelasma has a typical presentation and very rarely requires consideration for a differential diagnosis and yet omitted from most of the studies dealing with eyelid lesions.<sup>4</sup>

Though majority of the peri-ocular mass lesions do not require HPE, cases with diagnostic dilemmas or of academic interest or suspicious of dysplasia certainly demands HPE.<sup>8,9</sup> In our study, totally, 25.8% cases were sent for HPE; 5.6% did not match with PTCD. So, the accuracy in clinical diagnosis of benign peri ocular mass lesions was found to be 94.4%. This is similar to 94% accuracy found in Yasser H et al Epidemiology of benign eyelid lesions in patients presenting to a teaching hospital.<sup>2</sup>

## 5. Conclusion

Thorough understanding of physical characteristics is required for making an accurate PTCD and managing them effectively. Studies on a large scale would be extremely beneficial for the practicing ophthalmologists and the training residents and also for public health-care planning.

## 6. Conflict of Interest

None.

## 7. Source of Funding

None.

## References

- Huang Y, Liang W, Tsai C, Kao S, Yu W, Kau H, et al. Comparison of the Clinical Characteristics and Outcome of Benign and Malignant Eyelid Tumors: An Analysis of 4521 Eyelid Tumors in a Tertiary Medical Center. *Biomed Res Int*. 2015;p. 453091. doi:10.1155/2015/453091.
- Al-Faky YH. Epidemiology of benign eyelid lesions in patients presenting to a teaching hospital. *Saudi J Ophthalmol*. 2012;26(2):211–6. doi:10.1016/j.sjopt.2011.05.005.
- Asproudis I, Sotiropoulos G, Gartzios G, Raggos V, Papoudou-Bai A, Ntountas I, et al. Eyelid tumors at the university eye clinic. *MEAJO*. 2015;22(2):230–2.
- Nerad JA. The art of surgical technique in oculoplastic surgery: The requisites in ophthalmology. Mosby; 2005.
- Tran DT, Wolgamot GM, Olerud J, Hurst S, Argenyi Z. An ‘eruptive’ variant of juvenile xanthogranuloma associated with langerhans cell histiocytosis. *J Cutan Pathol*. 2008;35(1):50–4. doi:10.1111/j.1600-0560.2007.00959.x.
- Özdal P, Codère F, Callejo S, Caissie AL, Burnier MN. Accuracy of the clinical diagnosis of chalazion. *Eye (Lond)*. 2004;18(2):135–8. doi:10.1038/sj.eye.6700603.
- Shields JA, Demirci H, Marr BP, Eagle Jr RC, Shields CL. Sebaceous carcinoma of the eyelids, personal experience with 60 cases. *Ophthalmology*. 2004;111(12):2151–7. doi:10.1016/j.ophtha.2004.07.031.
- Kersten RC, Ewing-Chow D, Kulwin DR, Gallon M. Accuracy of clinical diagnosis of cutaneous eyelid lesions. *Ophthalmology*. 1997;104(3):479–84.
- Kanski JJ. Clinical ophthalmology : a systematic approach. Butterworth-Heinemann, Oxford; 1999. p. 62–3.
- Redmond RM. Molluscum contagiosum is not always benign. *BMJ*. 2004;329(7462):403. doi:10.1136/bmj.329.7462.403-c..

11. Hsu HC, Lin HF. Eyelid tumors in children: a clinicopathologic study of a 10-year review in southern Taiwan. *Ophthalmologica*. 2004;218(4):274–7.
12. Yan Z. Histopathological classification of 3,510 cases with eyelid tumor. *Zhonghua Yan Ke Za Zhi*. 1996;32(6):435–7.
13. Slaughter K, Sullivan T, Boulton J, Reagen P, Gole G. Early surgical intervention as definitive treatment for ocular adnexal capillary haemangioma. *Clin Exp Ophthalmol*. 2003;31(5):418–23.

### Author biography

**Shashikala P**, Assistant Professor

**Shrithi Das Shetty**, Senior Resident

**Cite this article:** Shashikala P, Shetty SD. Accuracy in clinical diagnosis of benign peri-ocular mass lesions. *IP Int J Ocul Oncol Oculoplasty* 2022;8(4):247-254.