

Content available at: <https://www.ipinnovative.com/open-access-journals>

IP International Journal of Ocular Oncology and Oculoplasty

Journal homepage: <https://ijooo.org/>**Original Research Article****Orbital apex syndrome in rhino-orbito-cerebralmucormycosis (ROCM) – A prospective observational study**Yogeswari Alagappan<sup>1</sup>, Mahalakshmi R P<sup>1</sup>, Gnanaoli Meenakshi Sundaram<sup>2</sup>, Niranjan Karthik Senthil Kumar<sup>2,\*</sup><sup>1</sup>Dept. of Orbit & Oculoplasty, Regional Institute of Ophthalmology and Government Ophthalmic Hospital, Chennai, Tamil Nadu, India<sup>2</sup>Dept. of Ophthalmology, Regional Institute of Ophthalmology and Government Ophthalmic Hospital, Chennai, Tamil Nadu, India**ARTICLE INFO***Article history:*

Received 02-08-2022

Accepted 14-08-2022

Available online 08-11-2022

*Keywords:*

Orbital apex syndrome

Rhino-orbito-cerebral mucormycosis

**ABSTRACT**

Orbital apex syndrome (OAS) is an uncommon clinical presentation consisting of complete ophthalmoplegia with vision loss, involving cranial nerves II, III, IV, V<sub>1</sub>, and VI.<sup>1</sup> OAS may result from trauma, malignancy, infection, inflammation, or vascular origins. Aims of the study were to analyse the incidence and presentation of orbital apex syndrome in rhino-orbital mucormycosis in a tertiary care hospital. A total of 29 cases (4.1%) out of 696 cases of invasive ROCM with OAS as a presenting feature were documented. Amphotericin B in both retrobulbar and intravenous routes played a crucial role in arresting the spread of the disease allowing only 8 (27%) cases to show disease progression. FESS if done appropriately with efficient debridement of necrotic infective tissue can be a powerful tool in redirecting the course of disease for the better (only 2 of 8 patients with CST at the time of presentation had a history of FESS done prior. ROCM is a severe, emergent and fatal infection requiring multidisciplinary management. It may often present with OAS initially. Mucormycosis must be considered in such patients and timely aggressive management must be initiated to avoid disastrous morbidity and mortality.

This is an Open Access (OA) journal, and articles are distributed under the terms of the [Creative Commons Attribution-NonCommercial-ShareAlike 4.0 License](https://creativecommons.org/licenses/by-nc-sa/4.0/), which allows others to remix, tweak, and build upon the work non-commercially, as long as appropriate credit is given and the new creations are licensed under the identical terms.

For reprints contact: [reprint@ipinnovative.com](mailto:reprint@ipinnovative.com)**1. Introductions**

Orbital apex syndrome (OAS) is an uncommon clinical presentation consisting of complete ophthalmoplegia with vision loss, involving cranial nerves II, III, IV, V<sub>1</sub>, and VI.<sup>1</sup> OAS may result from trauma, malignancy, infection, inflammation, or vascular origins. Rhino-orbito-cerebral mucormycosis (ROCM) is an invasive and often fatal fungal infection.<sup>2</sup> These infections are becoming increasingly more common and are associated with very poor survival rates. The increasing incidence of rhino-orbito-cerebral mucormycosis (ROCM) in the setting of COVID-19 in India and elsewhere has become a matter of immediate concern.

\* Corresponding author.

E-mail address: [s.niranjanarthik96@gmail.com](mailto:s.niranjanarthik96@gmail.com) (N. K. S. Kumar).

In the emergent setting, any patient with OAS who is either immune compromised or diabetic should be evaluated for the presence of mucormycosis.

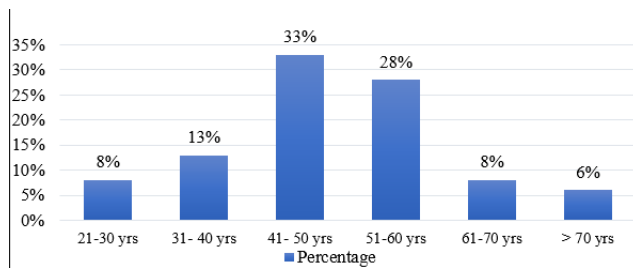
**2. Materials and Methods**

Aims of the study were to analyse the incidence and presentation of orbital apex syndrome in rhino-orbital mucormycosis in a tertiary care hospital. This was a prospective hospital based observational. ROCM. Exclusion criteria were those which were negative for mucormycosis in histo-pathological examination were deployed. Demographic details such as name, age, sex were recorded as obtained in detail including comorbidities diabetes, hypertension, coronary artery disease, pulmonary

TB, immunosuppression status, treatment details and resending ocular complaints were documented. Detail examination included visual acuity, extraocular movements, anterior segment evaluation, examination of cranial nerves and fundus examination. Panel of investigations performed were blood sugar, complete blood count, KOH/fungal culture, high nasal swab, DNE, Nasal mucosal biopsy, CT orbit with PNS, MRI Brain, orbit. Patients were monitored for signs of worsening (panophthalmitis, single eye). If present, orbital exenteration CNS involvement evident, urgent neurosurgery opinion, exenteration aggressive debridement of (turbineotomy+palatal+resection) followed not possible treatment was done.

**3. Results**

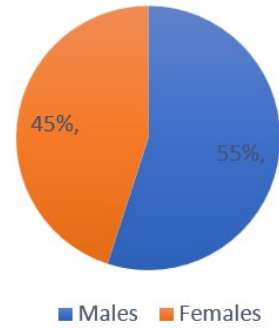
A total of 29 cases (4.1%) out of 696 cases of invasive ROCM with OAS as a presenting feature were documented. The range of age varied from as young as 23 years to 76 years of age . Mean age of presentation was 46.5 years. Most common age of presentation was between 41-50 years with 10 patients falling in this category. 16(55%) were males and 13 (45%) females 5(17%) cases were having bilateral presentation at manifestation. Most common presenting complaint was that of proptosis (100%) followed by restriction of extra ocular movements (89%). All patients had BCVA of 6/60 or less diabetes mellitus. Out of 29 cases, 7 patients had involvement of pterygopalatine fossa as was evidenced by CT scans. All 29 patients were treated with intravenous amphotericin B (5mg/kg body weight). All 29 patients were treated with retrobulbar amphotericin B (3.5mg/ml) for effective local treatment and closely monitored for worsening of clinical condition. Eight patients progressed rapidly and had involvement of cavernous sinus. Six of these eight patients were note to have brain abscess with temporal lobe involvement with sphenoidal sinusitis. Four of these patients were taken up for exenteration and postoperatively their general condition improved.



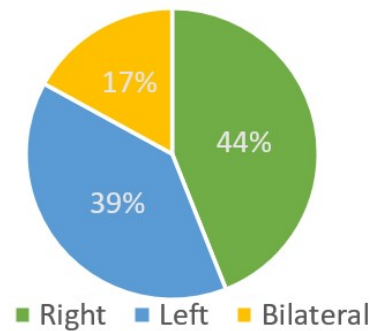
**Fig. 1:** Age distribution.

**4. Discussion**

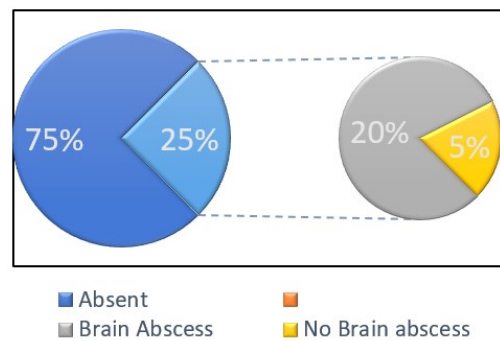
Around 5% of cases showing OAS in setting of mucormycosis, demonstrates the significant existence of



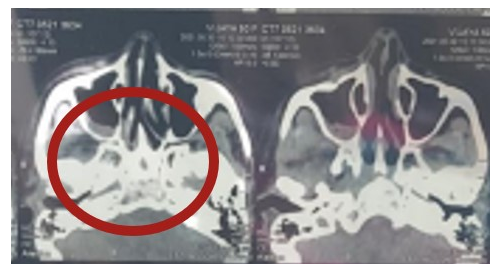**Fig. 2:** Gender.



**Fig. 3:** Laterality.



**Fig. 4:** CST Presentation.



**Fig. 5:**

this clinical entity. There was equal distribution among both genders. 5(17%) cases were having bilateral presentation at manifestation. This was similar in proportion to a study conducted by Songu et al.<sup>1</sup> 7 patients also had involvement of pterygopalatine fossa. Both these findings suggested the aggressive and devastating nature of the invasive fungus. All 29 patients had diabetes mellitus, in which neutrophils had an impaired ability of phagocytosis and chemotaxis. Turunc et al<sup>3</sup> and Jiang et al<sup>4</sup> studied 11 patients and all of these patients were having diabetes mellitus.. Presence of diabetic ketoacidosis increases predisposition to mucormycosis.<sup>5</sup> Acidosis disrupts iron binding of transferrin, resulting in increased proportion of unbound iron, which may promote growth and rapid spread of the fungus. In our study role of imaging was pivotal CT and MRI revealed a mass of the right sphenoid spreading into the orbit, indicative of a fungal infection. Study by Martel et al<sup>6</sup> demonstrated similar findings on CT and MRI in cases with OAS in mucormycosis. Hence awareness about these important radiological findings can aid in making the right diagnosis of OAS. In our study, Amphotericin B in both retrobulbar and intravenous routes played a crucial role in arresting the spread of the disease allowing only 8 (27%) cases to show disease progression. Jiang et al<sup>4</sup> in a study concluded that early diagnosis and urgent antifungal treatment associated to surgery are of extreme importance for successful eradication of infection and for patient survival. FESS if done appropriately with efficient debridement of necrotic infective tissue can be a powerful tool in redirecting the course of disease for the better (only 2 of 8 patients with CST at the time of presentation had a history of FESS done prior. With vessels being the main route of spread, aided by the valveless nature of the venous conduit (pterygoid plexus of veins) connecting several important areas of the brain, involvement of the brain parenchyma can be a significant complication as noted in our study with 6 patients (21%). Dooley et al<sup>7</sup> concluded that most patients end up in the involvement of brain parenchyma and brain infarct. Exenteration being a mutilating requiring general anaesthesia intraoperatively, prior meticulous planning with all necessary precautions in the form of fitness opinions obtained from department of neurology and neurosurgery, can go a long way in ensuring an uneventful intraoperative and postoperative course.

## 5. Conclusion

ROCM is a severe, emergent and fatal infection requiring multidisciplinary management. It may often present with OAS initially. Mucormycosis must be considered in such patients and timely aggressive management must be

initiated to avoid disastrous morbidity and mortality.

## 6. Abbreviations

OAS: Orbital apex syndrome; ROCM: Rhino-orbital-cerebral mucormycosis.

## 7. Source of Funding

None.

## 8. Conflict of Interest

None.

## References

1. Songu M, Unlu HH, Gunhan K, Ilker SS, Nese N. Orbital Exenteration: A Dilemma in Mucormycosis Presented with Orbital Apex Syndrome. *Am J Rhinol.* 2008;22(1):98–103.
2. Chakravarti J, Gupta MK, Tilak R, Kumar R, Maurya RP, Kumar N, et al. COVID-19-associated Mucormycosis : A clinico-epidemiological study. *J Diabet Compl.* 2022;36(9):108284. doi:10.1016/j.jdiacomp.2022.108284.
3. Turunc T, Demiroglu YZ, Aliskan H, Colakoglu S, Arslan H. Eleven cases of mucormycosis with atypical clinical manifestations in diabetic patients. *Diabetes Res Clin Pract.* 2008;82(2):203–8.
4. Jiang N, Zhao G, Yang S, Lin J, Hu L, Che C, et al. A retrospective analysis of eleven cases of invasive rhino-orbital-cerebral mucormycosis presented with orbital apex syndrome initially. *BMC Ophthalmol.* 2016;16(1):10. doi:10.1186/s12886-016-0189-1.
5. Maurya RP. Indications for orbital exenteration in COVID-19 associated Rhino-orbital-cerebral Mucormycosis. *IP Int J Ocul Oncol Oculoplast.* 2021;7(2):105–8.
6. Martel J, Anders U, Taylor E, Martel J. Acute orbital apex syndrome and rhino-orbital-cerebral mucormycosis. *Int Med Case Rep J.* 1993;8:93–6. doi:10.2147/IMCRJ.S83036.
7. Dooley DP, Hollsten DA, Grimes SR, Moss J. Indolent orbital apex syndrome caused by occult mucormycosis. *J Clin Neuroophthalmol.* 1992;12(4):245–9.

## Author biography

**Yogeswari Alagappan**, Professor and Unit Chief

**Mahalakshmi R P**, Assistant Professor

**Gnanaoli Meenakshi Sundaram**, Junior Resident

**Niranjan Karthik Senthil Kumar**, Junior Resident

**Cite this article:** Alagappan Y, Mahalakshmi R P, Sundaram GM, Kumar NKS. Orbital apex syndrome in rhino-orbital-cerebral mucormycosis (ROCM) – A prospective observational study. *IP Int J Ocul Oncol Oculoplasty* 2022;8(3):182-184.