

Content available at: <https://www.ipinnovative.com/open-access-journals>

IP International Journal of Ocular Oncology and Oculoplasty

Journal homepage: <https://ijooo.org/>

## Original Research Article

## Functional and cosmetic outcome in oculo-facial trauma at tertiary center-multidisciplinary approach

Vinita Ramnani<sup>1,\*</sup>, Sakshi Ramnani<sup>2</sup>, Sunil Rathore<sup>3</sup>, Nupur Sharma<sup>1</sup><sup>1</sup>Dept. of Eye, Bansal Hospital, Shahpura, Bhopal, Madhya Pradesh, India<sup>2</sup>Dept. of Eye, JSS Medical College, Mysore, Karnataka, India<sup>3</sup>Dept. of Plastic Surgen, Bansal Hospital, Shahpura, Bhopal, Madhya Pradesh, India

## ARTICLE INFO

## Article history:

Received 12-08-2022

Accepted 20-10-2022

Available online 08-11-2022

## Keywords:

Cosmetic  
Oculo-facial trauma  
Orbital fracture  
Ocular trauma

## ABSTRACT

**Purpose:** To assess the outcome of lid, adnexal and orbital injuries in poly trauma patients at multi specialty hospital.**Materials and Methods:** Papers of 104 consecutive patients with oculo-facial injuries were retrospectively reviewed. Data were analyzed with respect to extent, severity, type and location of oculo-facial injury. Treatment outcome assessed after surgeries performed by combined approach of ophthalmologist and plastic surgeon.**Results:** Periorbital soft tissue trauma observed in 65 (62.5%), orbital and Periorbital fracture in 39 (37.5%) cases and Intraocular injuries were noted in 43 patients (41.35 %). Accompanying other injuries was managed properly for better final outcome. Goal of repair is to restore anatomical and cosmetic appearance of patients. In our series of patients, we achieved 95% cosmetic satisfaction with loss of 5 eyes vision with best of our care.**Conclusions:** The oculo-facial trauma patients have tremendous fear of visual loss and aesthetic appearance. Functional and cosmetic outcome of oculo-facial injuries depends on multiple factors, well planned, appropriate, early intervention by multidisciplinary approach provides best surgical outcome.This is an Open Access (OA) journal, and articles are distributed under the terms of the [Creative Commons Attribution-NonCommercial-ShareAlike 4.0 License](https://creativecommons.org/licenses/by-nc-sa/4.0/), which allows others to remix, tweak, and build upon the work non-commercially, as long as appropriate credit is given and the new creations are licensed under the identical terms.For reprints contact: [reprint@ipinnovative.com](mailto:reprint@ipinnovative.com)

## 1. Introduction

Poly trauma patients presenting to multispecialty hospital mostly involves face with orbit and eye lids are frequent target.<sup>1</sup> The high rate of accidents with facial trauma occurs in productive age group of young patients, leads to economic and social burden due to loss of daily wages, increased costs for hospital care and family problems in patients below 45 years.<sup>2</sup> Various epidemiological studies showed variable etiology of facial fractures across the world, but road traffic vehicle accidents are among the most common causes of facial fractures.<sup>3</sup> Ocular trauma is leading causes of visual morbidity and blindness; about

6 million people worldwide are blind because of eye injuries, including 2.3 million bilateral blind and 19 million affected unilaterally.<sup>4</sup> Eye trauma is one of the leading causes of unilateral loss of vision particularly in developing countries<sup>5</sup> due to tremendous fear of vision loss and aesthetic appearance oculo-facial injuries are one of the most feared disabilities. The prevalence of ocular trauma study in urban slum population in Delhi, India reported (2.4%).<sup>6</sup> which is lower in comparison to a study from south India (3.97%).<sup>7</sup> Orbital fractures accounts for 36.3% of all facial fracture.<sup>8</sup> Orbital fractures mainly occur due to forces directed towards the eye and surrounding bones, as in vehicle accidents, falls, physical assault, and in sports injuries.<sup>9,10</sup> The three types of fracture can occur

\* Corresponding author.

E-mail address: [ramnanivinita@yahoo.co.in](mailto:ramnanivinita@yahoo.co.in) (V. Ramnani).

in orbital region are zygomatic complex, medial wall and orbital floor.<sup>11</sup> The most common type is floor or medial wall which is known as a "blow-out" fracture. A blow-out fracture leads to sinking of the orbital contents into bony defect; because of which eye also look sunken in orbit, which is called enophthalmos. Bony reconstruction of orbit helps to prevent or treat enophthalmos and to enhance patient's cosmetic satisfaction. Oculofacial trauma should be examined thoroughly by an ophthalmologist and oculofacial plastic surgeon and repair should be performed without delay. Inadequate surgical intervention for these types of injuries may result in eyelid deformity, incomplete eyelid closure, or tearing problems therefore proper reconstructive surgery should be performed jointly by both surgeons to enhance functional and cosmetic outcome. The aim of this paper is to assess the outcome of various ocular injuries involving lid, adnexal and orbit along with other facial and systemic injuries in poly trauma patients at multi specialty hospital.

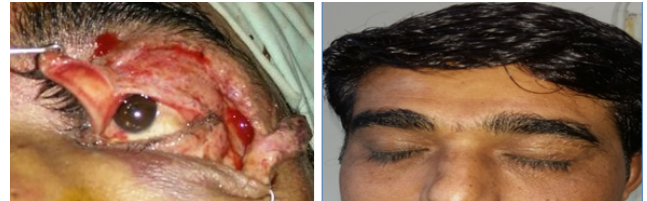**2. Materials and Methods**

This study was conducted in a tertiary care center after reviewing data of outcome measures for all the patients with ocular trauma presenting to the hospital between January 2017 to December 2017 with one year follow-up till December 2018. Records of patient's presenting to emergency and outpatient department of hospital with oculofacial trauma were reviewed for detailed history regarding type of injury with nature, force and direction of impact and severity and extent of injuries at various parts of body. After settling down the emergency and basic life support, subsequently detailed patients' ocular history regarding pre-morbid visual acuity, previous eye surgery, use of any corrective glasses or contact lenses, medications and tetanus status obtained. After history detailed physical examination is performed in a systematic manner to reduce any chance of missing injuries including external examination of the face, lids, orbit and adnexal structures. Testing for ocular motility, visual acuity, pupillary examination, anterior segment examination (with slit lamp if possible) and posterior segment evaluation (including indirect ophthalmoscopy) were performed. For evaluation of orbital and ocular trauma CT scan was the study of choice and is more sensitive than plain X-rays especially in the detection of foreign bodies. Detailed assessment of orbital fractures and severity of tissue loss in oculofacial trauma helps in deciding surgical strategies in poly trauma patients.

**3. Results**

We included all types of trauma cases presented at emergency unit of our hospital, irrespective of admission or OPD treatment of all kinds. Our study included 104

consecutive patients of oculofacial trauma, with male preponderance with patients 81 (77.88%) and females 23 (22.12%) presented in various age groups (shown in table 1). The presented associated combined multiple injuries were taken care by different specialists of multispecialty hospital like internist, orthopedic surgeon, neurosurgeon along with plastic surgeon and ophthalmologist as and when required. The main aim of treatment was to achieve best functional outcome followed by preference of cosmetic appearances.



**Fig. 1:** Lid laceration- post grafting.

**Table 1:** Age distribution of oculofacial trauma.

Age group	No	Percentage
0-20 Years	22	21.16%
21-40 Years	42	40.38%
41-60 Years	31	29.80%
Above 60Years	9	8.66%

Out of 104 total cases periorbital soft tissue trauma was commonest finding noted amongst 65 patients (62.5%) with bony orbital and periorbital fractures were found in 39 patients (37.5%) and intraocular injuries were noted in 43 patients (41.35 %) all 3 noted in Tables 2, 3 and 4). Details of intraocular injuries were noted and repaired accordingly.

**Table 2:** Periorbital soft tissue trauma

<b>I. Periorbital soft tissue trauma 65(62.5%)</b>		
Type of Injury	Number	Percentage
Periorbital edema and ecchymosis	27	41.54%
Lid Contusions, abrasions	16	24.61%
Lid tears	22	33.85%
Total	65	100%

Immediate primary treatment was given and those requiring surgical management like lid tear repair, corneal and scleral tear repair, fracture and other repairs were done in operation theater following CT scan, MRI, X-ray and all pertaining fitness investigations in local or general anesthesia as par case to case requirement. Luckily with so much of bony orbital and periorbital injuries, it is observed that eyes being protected by bony cage was not seriously

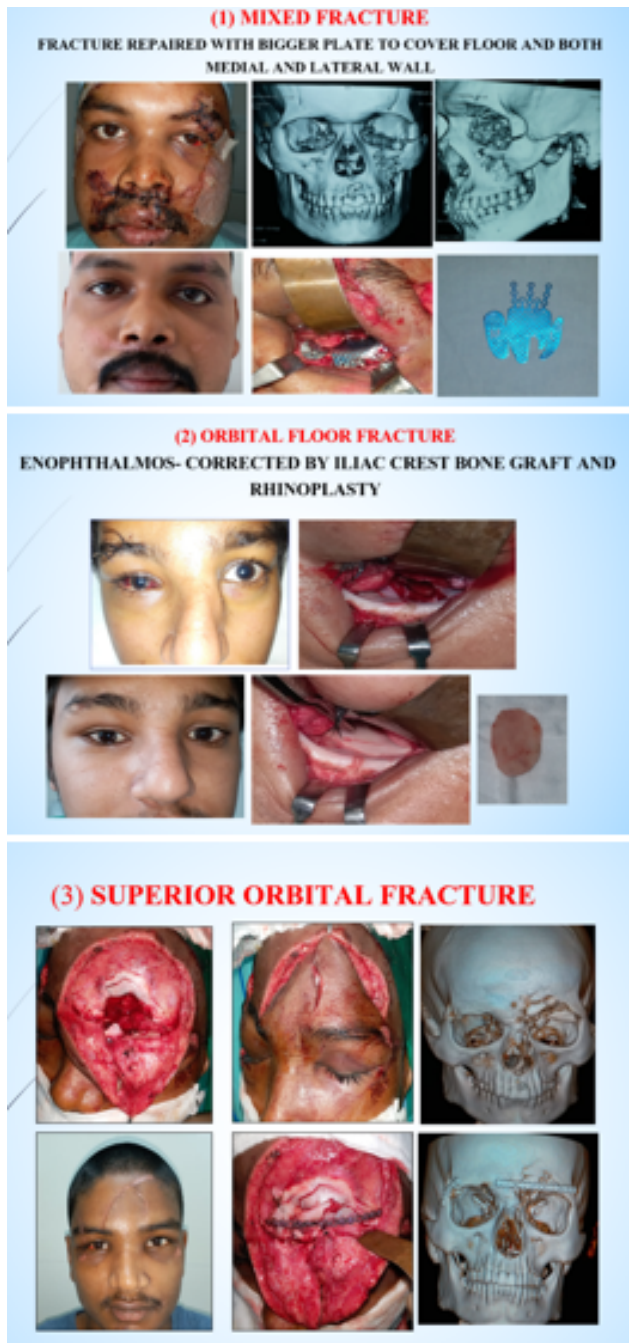

Fig. 2: Pre-operative & post-operative of orbital fractures.

Table 3: Orbital and periorbital fractures

III. Orbital and periorbital fracture- 39(37.5%)		
Type of Injury	Number	Percentage
Orbital floor fracture	6	15.39%
Lateral wall fracture	8	20.51%
Median wall fracture	9	23.08%
Mixed fracture	16	41.02%
Total	65	100%

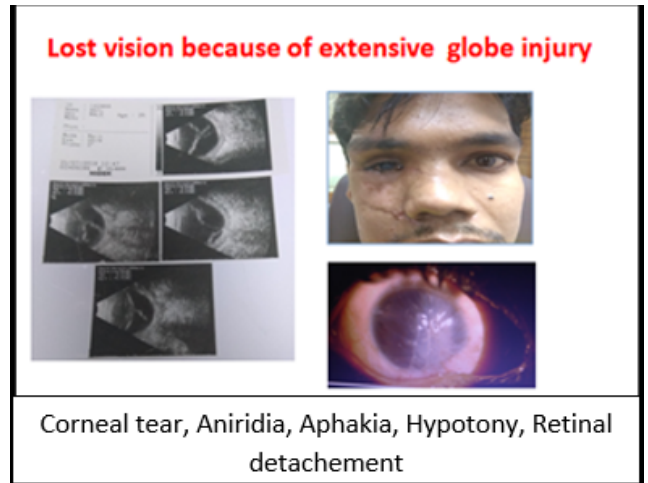


Fig. 3: Extensive oculofacial trauma with loss of structure and function of eye.

Table 4: Intraocular trauma

II. Intraocular injuries- 43(41.35%)		
Type of Injury	Number	Percentage
Cconjunctival tear	3	7%
Scleral tear	2	4.64%
Corneal tear	8	18.60%
HypHEMA	3	7%
Traumatic mydriasis	2	4.64%
Lens subluxation or dislocation-cataract	2	4.64%
Vitreous hemorrhage and retinal hemorrhages	2	4.64%
Choroidal tear or macular trauma	1	2.32%
Retinal detachment	1	4.64%
Traumatic Optic never injury	4	9.30%
Optic never avulsion	0	0
Globe rupture	3	7%
Carotid-cavernous fistula	1	2.32%
Loss of eye	4	9.30%
Post injury infection	1	2.32%
Post traumatic glaucoma	2	4.64%
Post traumatic cranial nevers involvement	3	7%

Table 5: Visual acuity on admission & discharge

Visual acuity presentation and on discharge (N=104)				
Visual acuity	At presentation		At discharge	
Above 6/12	36	34.62%	39	37.50%
6-12 to 6/36	30	25.85%	37	35.58%
6/60 – 3/60	17	16.34%	11	10.58%
Below 3/60	11	10.57%	12	11.54%
Pl+PR+	8	7.70%	2	1.92%
NO PL	2	1.92%	3	2.88%

involved and presentation vision was very good in majority of patients (83 out of 104 patients had better than 3/60 vision on presentation) and only 5 patients lost vision because of severe ocular involvement, rest all recovered. Details of presentation of vision on admission and on discharge was indicated in Table 5. Traumatic optic nerve injury without avulsion seen in 4 patients and they recovered on systemic methyl prednisolone injections.

Overall management of patients with poly trauma by a multitude of specialties with various goals for successful patient outcomes is major benefit in multispecialty hospital like us. The team including otolaryngology, ophthalmology, plastic surgery, orthosurgery, neuro and oral surgery as per need of trauma. Each of these specialties has its surgeon's training and expertise to influences their management of ploy trauma. It is important in oculofacial trauma to have comprehensive evaluation and management of patients by combine approach of both plastic surgeon and ophthalmologist as in our patients, as plastic surgeon would proceed with surgical correction to improve facial aesthetics, while ophthalmologist rather worries about the vision of patient. In our series of patients, we achieved 95% cosmetic satisfaction with loss of 5 eyes vision with best of our care.

#### 4. Discussion

Ocular injuries are commonly associated with facial injuries. Out of 1,608 patients with different types of craniomaxillofacial injuries over a 7-year period (1984 to 1990) ocular injuries were seen in 367 patients and suggested in study that a close relationship among ophthalmic surgeons, maxillofacial surgeons, and neurosurgeons is very important to decrease the incidence of complications in such cases.<sup>12</sup> Another study included 11,592 reported hospitalized maxillofacial trauma patients (39.4% of them were MVA, 33.5% were falls), with a male predominance of a 3:1 ratio.<sup>13</sup> Among the 32 children seen, 20 (63%) were males, 25 of 32 (78%) were between 4 and 7 years of age. Fall was the cause of injury in 31% (10/32) and assault in 28% (9/32). Medial canthal injury was the commonest of all periorbital injuries manifesting as lacrimal drainage obstruction and telecanthus. Associated fractures of the naso-orbital bones were present in 7 patients (22%) and ocular injuries were seen in 18 patients (56%). Secondary intervention was performed in 20 patients and lacrimal drainage procedure was the commonest surgery, performed in 15 out of 20 (75%).<sup>14</sup>

Trauma is the second leading cause of blindness; Ocular injuries occur commonly in patients with facial trauma.<sup>15,16</sup> Ocular contusions are common and cause significant morbidity. Epidemiology data shows that young men are most injured<sup>17</sup> Approximately 22% to 30% of orbital fractures have associated ocular injuries<sup>18</sup> In review of 1,436 cases of maxillofacial trauma presenting from

1973-1980, Fifty-one percent (727) underwent complete ophthalmologic examination and 67% of these sustained ocular injuries. Out of which 79% of the eye injuries were temporary, 18% were serious, and 3% were blinding.<sup>19</sup>

Simultaneous bilateral ocular injuries are not uncommon.<sup>20</sup> Blunt trauma can cause a wide range of ocular injuries, and some time an immediate evaluation is not possible, but one must carefully examine both eyes for ocular injuries associated with blunt trauma especially vision threatening damage to retina must be noted and recorded Early treatment of these lesions can help in preventing potentially long-term visual consequences.<sup>21</sup> Systematic review the literature of eleven articles for better understanding of specific fracture patterns associated with ocular injuries, including visual impairment and blindness. Periorbital and orbital blowout fractures were more often complicated by ocular injuries compared with other facial fracture patterns. High-impact zygomatic fractures were most commonly associated with blindness.<sup>22</sup>

Ocular injury can be associated with facial fractures in a significant percentage of cases. It is mandatory for surgeons treating such fractures to be familiar with the types of orbital injuries, the appropriate physical examination and diagnostic tests, and the management techniques involved in treating traumatic visual loss. reviews the diagnostic and therapeutic approaches to this important problem.<sup>23</sup> Retrospective analysis of 417 inpatients of the university-eye-hospital Erlangen from 1985-1995 with ocular contusion or globe rupture (EOCR - Erlangen Ocular Contusion-Registry). Ocular trauma includes hyphema (73%), rebleeding (4%), angle recession (71%), iris sphincter tears (20%), iridodialysis (10%), cyclodialysis (3-4%), traumatic aniridia (1%), lens dislocation (15%), traumatic cataract (10%), choroidal rupture (7%), retinal tear or detachment (7%), Berlin's edema (35.5%), globe rupture (4-6%), blow-out-fracture (8-3%). Vitreous prolapse (7-5%) was often associated with Vitreous hemorrhage (57%), hyphema (86%), globe rupture (20%), iris sphincter tear (44%), iridodialysis or cyclodialysis (43%), traumatic cataract (41%), lens dislocation (93%) and retinal tear or detachment (29%).<sup>24</sup>

Injuries to globe and adnexal structures occur frequently during blunt facial trauma. Holt et al. (1983), after formal facial trauma, found the following incidence of eye injuries—29% mandibular fractures, 59% nasal fractures, 76% mid-face fractures, and 89% frontal fractures. Holt et al. (1983) found that 90 patients had moderately severe eye injuries. Amongst them, 3% had mandibular fractures, 7% had nasal fractures, 70% mid-face fractures, and 20% frontal sinus and supra orbital fractures and also reported 79% temporary injuries in 382 patients (680 in number), 18% moderate injuries in 90 patients (401 in number), and 3% blinding injuries in 22 patients.<sup>25</sup>

In the present study we encountered periorbital soft tissue trauma observed in 65(62.5%), orbital and periorbital fracture in 39(37.5%) cases and intraocular injuries were noted in 43 patients (41.35%), in comparison to study by mittal et al<sup>26</sup> with 34.5% of the mandibular fractures, 25% of the nasal fractures, 95.7% of the mid face fractures, and 83.3% of the frontal fractures were associated with ophthalmic injury of some severity. this study shows 29.09% (27 of 93) with transient or permanent visual loss. The statistics is significantly comparable with the above studies. The concomitant occurrence of globe rupture and blow out fracture of the orbit is a rare occurring situation.

Al Qurainy et al. (1991) found an overall incidence of 90.6% ophthalmic injury in 363 patients with mid-facial injury. ) and out of presented 230 patients (230/363 = 63.4%) with temporary injuries, 57 patients (57/363 = 15.7%) with moderate injuries, and 42 patients (42/363 = 11.6%) with blinding injuries Al-Qurainy et al. (1991) reported a 15.4% (56 of 393) decrease in visual acuity<sup>27</sup> In a retrospective analysis by Ashar et al.(1998), of 49 patients admitted with mid-facial fractures, ten patients lost vision in one eye.<sup>28</sup> Shantha Amrith (2000) reported 23% patients with decrease in visual acuity, with 12.5% having permanent visual impairment.<sup>29</sup> Facial fractures have been reported to increase the risk of developing an ocular injury by a factor of 6.7 when compared with major trauma in patients with no facial fractures.<sup>30</sup>

The overall incidence of ophthalmic injury of any severity in the present study is 68.3% with the highest incidence in relation to midfacial trauma, i.e., 95.7%. The results of this present study reinforce the contention that road traffic accidents cause more severe ocular injuries than any other cause of facial trauma. Similarly, complex facial fractures are related with highest incidence of visual dysfunction. Two-third of all the patients with orbital fractures were associated with severe ocular disorder, followed by frontal fractures. Then came the

zygomaticomaxillary complex fractures, whereas no severe ocular complication was reported in mandibular or nasal fractures. Fortunately, many of the ocular injuries were transient and of no permanent consequence. However, the incidence of 9.6% (9 of 93) with blinding and serious injuries is significant. Of particular importance are those of optic nerve injury (6.4% or 6 patients).

## 5. Conclusion

The oculo-facial trauma patients have tremendous fear of visual loss and aesthetic appearance. Bony socket and periorbital structures, take the impact of the injury in road traffic accidents and protects eye ball to explain the type and distribution of injuries and ultimate outcome. Goal of repair is to restore anatomical and aesthetic appearance of patients. Functional and cosmetic outcome of oculo-facial injuries depends on multiple factors, well planned, appropriate early intervention by multidisciplinary approach provides best

surgical outcome.

## 6. Source of Funding

None.

## 7. Conflict of Interest

None.

## References

- Alvi A, Doherty T, Lewen G. Facial fractures and concomitant injuries in trauma patients. *Laryngoscope*. 2003;113(1):102–6. doi:10.1097/00005537-200301000-00019.
- Cannell H, Dyer PV, Paterson A. Maxillofacial injuries in the multiply injured. *Eur J Emerg Med*. 1996;3(1):43–7. doi:10.1097/00063110-199603000-00008.
- McGwin G, Owsley C. Incidence of emergency department treated eye injury in the United States. *Arch Ophthalmol*. 2015;123(5):662–6. doi:10.1001/archophth.123.5.662.
- Negrel AD, Thylefors B. The global impact of eye injuries. *Ophthalmic Epidemiol*. 1998;5(3):143–69. doi:10.1076/0967.5.3.143.8364.
- WHO Geneva. Strategies for the Prevention of Blindness in National programmes. A Primary Health Care Approach, 2nd edn. WHO Library Cataloguing: England; 1997.
- Vats S, Murthy GVS, Chandra M, Gupta SK. Vashist P Epidemiological study of ocular trauma in an urban slum population in Delhi, India. *Indian J Ophthalmol*;56(4):313–6. doi:10.4103/0301-4738.41413.
- Dandona L, Dandona R, Srinivas M, John RK, Mccarty CA. Ocular trauma in an urban population in southern India: the Andhra Pradesh Eye Disease Study. *Clin Exp Ophthalmol*. 2000;28(5):350–6. doi:10.1046/j.1442-9071.2000.00334.x.
- Cabalag MS, Wasiak J, Andrew NE. Epidemiology and management of maxillofacial fractures in an Australian trauma centre. *J Plast Reconstr Aesthet Surg*. 2014;67(2):183–9. doi:10.1016/j.bjps.2013.10.022.
- Rosado P, de Vicente J. Retrospective analysis of 314 orbital fractures. *Oral Surg Oral Med Oral Radiol*;113(2):168–71. doi:10.1016/j.tripleo.2011.01.035.
- Maurya RP, Jain P, Singh VP, Singh MK, Mishra CP, Varma A, et al. Etiology and pattern of orbital fractures in a teaching hospital. *IP Int J Ocul Oncol Oculoplast*. 2017;3(3):184–92.
- Cruz AAV, Eichenberger GC. Epidemiology and management of orbital fractures. *Curr Opin Ophthalmol*. 2004;15(7):416–21. doi:10.1097/01.icu.0000136113.56288.87.
- Taher AA. Ocular injuries in 367 patients with middle and upper third facial trauma: experience in Tehran. *J Craniofac Surg*. 1996;7(2):117–21. doi:10.1097/00001665-199603000-00007.
- Einy S, Rahman NA, Siman-Tov M, Aizenbud D, Peleg K. Maxillofacial Trauma Following Road Accidents and Falls. *J Craniofac Surg*. 2016;27(4):857–61. doi:10.1097/SCS.0000000000002555.
- Pushker N, Bajaj MS, Sharma V, Balasubramanya R. Profile of trauma-related residual periorbital deformities in Indian children. *Int Ophthalmol*. 2004;25(4):239–42.
- Larian B, Wong B, Crumley RL, Moeinolmolki B, Muranaka E, Keates RH, et al. Facial trauma and ocular/orbital injury. *J Craniomaxillofac Trauma*. 1999;5(4):15–24.
- Maurya RP, Srivastav T, Singh VP, Mishra CP, and AAM. The epidemiology of ocular trauma in northern India: A teaching hospital study. *Oman J Ophthalmol*. 2019;12(2):78–83. doi:10.4103/ojo.OJO\_149\_2018.
- Montard R. Ocular injuries in mild facial trauma. *Rev Stomatol Chir Maxillofac*. 2006;107(4):264–72.



18. Cole P, Kaufman Y, Hollier L. Principles of facial trauma: orbital fracture management. *J Craniofac Surg.* 2009;20(1):101–4.
19. Holt JE, Holt GR, Blodgett JM. Ocular injuries sustained during blunt facial trauma. *Ophthalmology.* 1983;90(1):14–8. doi:10.1016/s0161-6420(83)34597-8.
20. Maurya RP, Singh VP, Ul-Kadir SM, Das JK, Boshak SK, Prajapat MK, et al. The Study of simultaneous bilateral ocular trauma in Northern India: Clinical presentation, epidemiology and pattern of injury. *Int Ophthalmol.* 2022;42(2):11193–203. doi:10.1007/s10792-021-02104-5.
21. Giovinazzo VJ. The ocular sequelae of blunt trauma. *Adv Ophthalmic Plast Reconstr Surg.* 1987;6:107–14.
22. Magarakis M, Munding GS, Kelamis JA, Dorafshar AH, Bojovic B, Rodriguez ED, et al. Ocular injury, visual impairment, and blindness associated with facial fractures: a systematic literature review. *Plast Reconstr Surg.* 2012;129(1):227–33.
23. Weisman RA, Savino PJ. Management of patients with facial trauma and associated ocular/orbital injuries. *Otolaryngol Clin North Am.* 1991;24(1):37–57.
24. Viestenz A, Kuchle M. Retrospective analysis of 417 cases of contusion and rupture of the globe with frequent avoidable causes of trauma: the Erlangen Ocular Contusion-Registry (EOCR) 1985 - 1995. *Klin Monbl Augenheilkd.* 2001;218(10):662–9. doi:10.1055/s-2001-18388.
25. Holt GR, Holt JE. Incidence of eye injuries in facial fractures: An analysis of 727 cases. *Otolaryngol Head Neck Surg.* 1983;91(3):276–9. doi:10.1177/019459988309100313.
26. Mittal G, Singh N, Suvarana S, Mittal SR. A prospective study on ophthalmic injuries related to maxillofacial trauma in Indian population. *Natl J Maxillofac Surg.* 2012;3(2):152–8. doi:10.4103/0975-5950.111370.
27. al Qurainy A, Stassen LF, Dutton GN, Moos KF, el Attar A. The characteristics of mid facial fractures and the association with ocular injury: A prospective study. *Br J Oral Maxillofac Surg.* 1991;29(5):291–301. doi:10.1016/0266-4356(91)90114-k.
28. Ashar A, Kovacs A, Khan S, Hakim J. Blindness associated with mid facial fractures. *J Oral Maxillofac Surg.* 1998;56(10):1146–50. doi:10.1016/s0278-2391(98)90757-1.
29. Amrith S, Saw SM, Lim TC, Lee TK. Ophthalmic involvement in craniofacial trauma. *J Craniomaxillofac Surg.* 2000;28(3):140–7. doi:10.1054/jcms.2000.0138.
30. Guly CM, Guly HR, Bouamra O, Gray RH, Lecky FE. Ocular injuries in patients with major trauma. *Emerg Med J.* 2006;23(12):915–7. doi:10.1136/emj.2006.038562.

## Author biography

**Vinita Ramnani**, Consultant

**Sakshi Ramnani**, Resident

**Sunil Rathore**, Consultant

**Nupur Sharma**, Consultant

**Cite this article:** Ramnani V, Ramnani S, Rathore S, Sharma N. Functional and cosmetic outcome in oculo-facial trauma at tertiary center- multidisciplinary approach. *IP Int J Ocul Oncol Oculoplasty* 2022;8(3):176-181.