

## Sebaceous gland carcinoma and its correlation with different signaling pathways with emphasis on p53

Royana Singh<sup>1\*</sup>, Rajendra P. Maurya<sup>2</sup>, Sanjay Bosak<sup>3</sup>, Mahendra K. Singh<sup>4</sup>, Virendra P. Singh<sup>5</sup>

<sup>1</sup>Professor, Department of Anatomy, <sup>2</sup>Assistant Professor, <sup>3</sup>Junior Resident, <sup>4,5</sup>Professor, Department of Ophthalmology, Institute of Medical Sciences, Banaras Hindu University, Varanasi

**\*Corresponding Author:**

Email: drroyana@gmail.com

---

### Introduction

In humans, sebaceous glands are microscopic glands in the skin that secrete sebum. Sebaceous glands are part of epidermal appendages. They are found abundantly in the face and scalp, and are present throughout the skin except palm and sole. Sebaceous glands are associated with hair follicles; arising at the junction of the inferior portion of the follicular infundibulum and the isthmus[1].

### Surgical anatomy

The eyelid can be divided into anterior and posterior lamellae. The skin, orbicularis muscle, eyelashes and their follicles are present in the anterior lamella while the posterior lamella consists of the mucocutaneous junction, meibomian gland orifices and tarsal plate. Sebaceous glands are found in the tarsal plate (upper and lower), caruncle and eye brow.

### Epidemiology

Sebaceous gland carcinoma is an aggressive, uncommon, cutaneous tumor, first well-described by Allaire in 1891[2]. Neoplasm of the sebaceous glands may be benign or malignant e.g., sebaceous hyperplasia or sebaceous gland adenomas and malignant sebaceous gland carcinoma, respectively. This tumor is thought to arise from sebaceous glands in the skin and, thus, may arise anywhere on the body where these glands exist, including the genitalia[3,4,5,6]. Approximately 75% of these tumors arise in the periocular region, an area rich in varieties of sebaceous glands[6,7]. Very few cases have been reported at extraocular sites. The most common site of origin is the meibomian glands of the eyelids, caruncle, the glands of Zeis and in the eyebrow. The meibomian glands originate in the tarsus and number approximately 25 in the upper eyelid and 20 in the lower eyelid. They are oil-producing sebaceous glands.

Zeis glands are small, modified sebaceous glands that open into the hair follicles at the base of the eyelashes. The incidence of sebaceous cell carcinoma is 0.8% of all eyelid tumors. The mortality rate is 22%.

In a retrospective study, 31 patients were diagnosed with sebaceous cell carcinoma of the ocular adnexa on histopathology. Twenty (65%) of the patients were women and 11 were men. The upper eyelid was

involved in 18 patients, the lower eyelid in 10 in 1 and the caruncle in 2[2].

Sebaceous cell carcinomas are typically found in women, more often in the seventh decade of life, and they usually are on the upper eyelid margin. They may be seen in younger patients with a history of radiation to the face. Diagnosis and therapy tends to be delayed because sebaceous carcinoma is frequently mistaken for more common benign entities like chalazion (an inflammation caused by obstruction of the meibomian glands) or chronic blepharitis, further complicating treatment of this aggressive malignancy[8-13]. In addition to its varied clinical appearance, a varied histologic appearance may occur and delayed diagnosis or misdiagnosis following a biopsy is not uncommon[8-10].

It tends to invade locally, as well as spreading to regional lymph nodes. Sebaceous cell carcinomas may grow in nests with central necrosis. The intraepithelial spread may lead to the erroneous histologic diagnosis of epithelial dysplasia or carcinoma in situ. Foamy cytoplasm is seen only in sebaceous carcinoma but it is absent in conjunctival or cutaneous squamous cell carcinoma. It can also histologically mimic basal cell carcinoma, squamous carcinoma or Merkel cell tumor.

When arising in the periocular region, the clinical presentation is often variable, and sebaceous gland carcinoma is often not initially suspected. Instead, patients may receive multiple courses of incision and drainage for chalazion before a definitive biopsy is performed[8,14,15]. Sebaceous cell carcinoma is a lethal eyelid malignancy and carries a significant mortality rate with metastasis.

### Frequency

Sebaceous gland carcinoma seems to occur with greater frequency relative to other skin cancers in Asian populations. In a large retrospective series from China, sebaceous gland carcinoma was the second most common periocular tumor after basal cell carcinoma, reported to represent 33% of eyelid malignancies[16].

### Mortality/Morbidity

Sebaceous gland carcinoma is an aggressive tumor, with a tendency for both local recurrence and distant metastasis. Reported local recurrence rate ranges from

9-36%, with larger series reporting recurrence rate in 30% range. Local recurrence tends to occur within 5 years.[6,10]

The rate of metastasis in extraocular and ocular sebaceous carcinoma is thought to be similar, occurring in 14-25% of cases, first to the draining lymph nodes and then to distant sites[8,19]. Sites of distant metastasis include the liver, lungs, bones, and brain[8,17,18]. Metastasis has been reported to occur as late as 5 years after the initial diagnosis, lending support to continuous surveillance of patients with sebaceous carcinoma[18].

### **Etiology**

Most sebaceous gland carcinomas have no obvious etiology. Only a few are associated with Muir-Torre syndrome. Although sebaceous adenoma and epithelioma are more specific markers for Muir-Torre syndrome, an evaluation for this syndrome is advisable once sebaceous gland carcinoma is diagnosed [20]. In approximately 40% of cases, patients with Muir-Torre syndrome develop some type of sebaceous tumor before or concurrent with visceral malignancy[21]. *Rb* and *p53* mutations[23-25], HIV[19], and HPV[23,26] have also been shown to be associated with it.

### **Clinical features**

The upper lid is more frequently involved by SGC than the lower lid.[27] It masquerades not only various inflammatory conditions such as blepharoconjunctivitis or chalazion but also as premalignant lesions and other benign or malignant tumors.[26 -31] The nodular form of SGC presents as a discrete, hard, immobile nodule commonly located in the upper tarsal plate having a yellowish appearance. The pagetoid variety of SGC occurs with intraepithelial infiltration of the lid margin and/or conjunctiva causing diffuse thickening and loss of eyelashes resembling chronic blepharoconjunctivitis.[32,33]

### **Diagnosis**

Modern tumor classification schemes name the tumors for the type of normal adult tissue towards which the tumor appears to be differentiating. Microscopic examination is the gold standard in diagnosis and confirmation of SGC. Most patients have a moderately differentiated tumor[35,36]. The tumor cells are arranged in the form of sheets or lobules, sometimes with central comedonecrosis

The cell of origin is often not known. Sebaceous gland carcinoma clearly resembles normal sebaceous glands[34]. One may reasonably speculate that sebaceous gland carcinoma arises from mature sebaceous glands. Histologic studies have suggested that periocular sebaceous gland carcinomas arise from the sebaceous glands in this region.

In Schwartz's histologic series, 51% of cases reportedly arose from a specialized sebaceous gland of the eyelid, the meibomian gland. Indeed, sebaceous gland carcinoma is sometimes referred to as meibomian gland carcinoma. In the same series, 10% of cases arose from the glands of Zeis, less than 10% of cases arose from the caruncle and the eyebrow each, and 12% were multicentric with no obvious source of origin[35].

Isolated case reports describe sebaceous gland carcinoma limited to the epithelium, with no obvious connection to the underlying sebaceous glands[36]. In these rare cases, the sebaceous gland carcinoma may fill the conjunctival epithelium and create the appearance of squamous cell carcinoma in situ. Whether these tumors truly have an epithelial origin or whether the dermal connection has been lost or is simply unappreciated is unknown.

Approximately, 30 case reports have described the development of sebaceous carcinoma in a sebaceous nevus of Jadassohn[37-42]. Sebaceous carcinoma arising from a nevus sebaceous is more common in women and elderly persons, described as a nodule or ulcerated tumor that usually demonstrates rapid growth prior to diagnosis[38]. Although generally larger in diameter, this distinct entity tends to possess more benign features and follows a more favorable course[43]. Controversy exists regarding the prophylactic removal of a nevus sebaceous, but when malignant neoplasms are suspected, removal is warranted[44].

Recently, several molecular markers have been identified that may help elucidate the pathophysiologic progression of sebaceous carcinoma. Promotion of tumor metastasis and a poor clinical outcome have been associated with epigenetic inactivation of E-cadherin and subsequent loss of cell-to-cell adhesion in sebaceous carcinoma[45]. Hormonal receptors may also play a significant role. Increased expression of androgen receptor in the nucleus of periocular sebaceous carcinoma may indicate a greater likelihood of recurrence and help distinguish this entity from squamous cell and basal cell carcinomas[46,47]. Immunostaining for androgen receptor (AR) in SGC has been extensively described in the recent literature suggesting AR to be a reliable marker of sebaceous differentiation[51-55]. A panel of antibodies comprising carcino-embryonic antigen (CEA) seen in approximately 39% patients[49,50,52-56]. Intra-epithelial spread, a common cause of misdiagnosis, is a characteristic feature of SGC. Intra-epithelial spread can have a Bowenoid, pagetoid or mixed pattern. Reports in the literature describe the Bowenoid and pagetoid patterns in up to 35% and 47% of SGC, respectively[48,57].

### **Syndromes and Genes associated with SGC**

**Muir-Torre syndrome and mismatch repair genes:** Muir-Torre syndrome is diagnosed if a person has one

or more of the skin changes and one or more of the internal cancers listed above. A person diagnosed with Muir-Torre syndrome can have a blood test to see if they have a mutation in the MLH1 or MSH2 genes. However, not everyone with Muir-Torre syndrome will have a detectable mutation in one of these two genes. Several studies have investigated the relationship between MTS and SGC.[1,58-60] A subset of patients with clinical or phenotypic MTS have a defect in the DNA mismatch repair (MMR) genes and are at a risk for developing future malignancy[58]. An MMR defect results in the accumulation of replication errors or unstable microsatellite sequences[61]. In MTS, germline mutation in one of the MMR-genes is complemented by a second somatic molecular alteration in a neoplasm.

A sebaceous lesion is present either before or concurrent with the first visceral malignancy in 63% patients with MMR-deficient MTS[62].

It should also prompt the laboratory to perform immunostaining for the commonly absent MMR proteins (MSH2, MLH1, PMS1 and PMS2). One-third of patients with clinical MTS demonstrate failure to express normal MMR proteins[61]. Mutations in MSH2 and MLH1 are more frequent than those in MSH6, MSH3, MLH3, PMS2 and PMS1. Many cell signaling pathways have been shown to be dysregulated in SGC.

**Wnt/b-catenin pathway:** The Wnt/b-Catenin pathway regulates stem cell pluripotency and cell fate decisions during development. In the absence of Wnt, glycogen synthase kinase 3 (GSK-3) constitutively phosphorylates the b-catenin protein. Overexpression of b-catenin has been demonstrated in SGC thus suggesting a possible dysregulation of the Wnt/b-catenin pathway[64-66]. Further, it was also shown that reduced membranous expression of b-catenin correlated

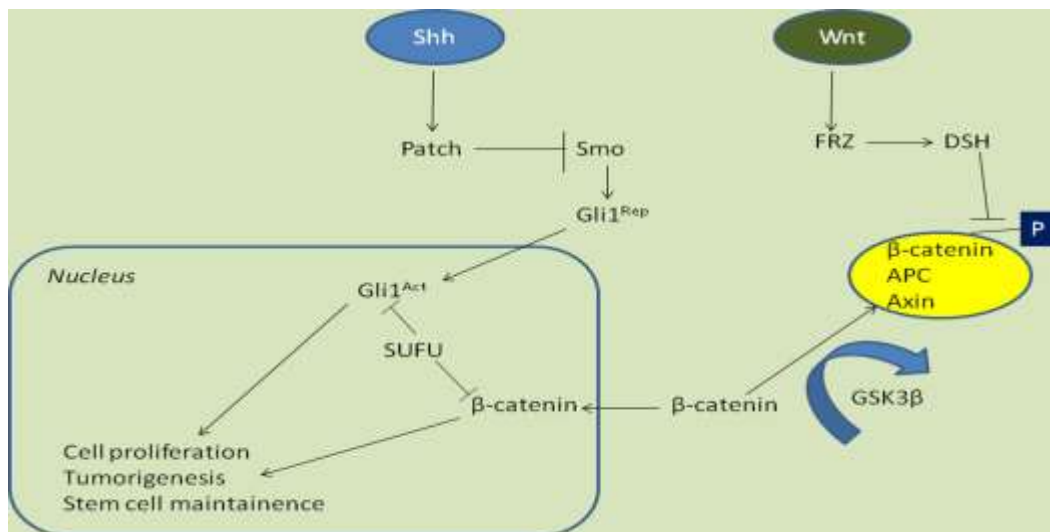
with invasion and metastasis, especially at the site of invasion[64].

**p21/WAF1:** p21WAF1, a cyclin-dependent kinase inhibitor, regulates G1-S transition and mediates G1 cell cycle arrest. It can be transcriptionally upregulated by p53 but may be activated independently. Compartmentalization of p21WAF1 in the differentiated component of the gland, seen in normal sebaceous glands and benign sebaceous lesions, is lost in SGC[67]. A recent study associated down regulation of p21 with lymph node metastasis in SGC[68].

**Sonic hedgehog pathway:** The sonic hedgehog (Shh) signaling pathway is also altered in SGC with Shh and ABCG2 proteins being overexpressed in patients with a metastatic disease[64]. This study thus suggested that activation of Wnt and Shh signaling pathways is associated with higher cumulative incidences of lymph node and distant metastasis in SGC[62].

**Androgen receptor:** AR has been identified as a MYC target gene in mouse epidermis[66]. p53 can inhibit AR gene expression by direct association with AR promoter[67] and by inhibiting AR protein activity [70]. On the other hand, strong AR activity can inhibit p53 expression [71] and p53 activity[72]. Thus, the expressions of AR and p53 are inversely related to each other in SGC[73].

**E-cadherin:** E-cadherin promoter hyper methylation through Wnt/ bcatenin/ TCF pathway has been associated with poor clinical outcome like reduced disease-free survival, size>2 cm, lymphnode metastases and poor differentiation[7]. Sonic hedgehog and Wnt/b-catenin signaling pathways in sebaceous gland carcinoma[72]



**TP53:** p53 Mutations in SGC, as demonstrated by overexpression, suggest a possible role of UV radiation and subsequent signal alterations[44].

Sebaceous neoplasm should prompt the clinician to carry analysis of p53 mutation and its expression in sebaceous carcinoma of the eyelid. Taking into consideration the single strand conformation polymorphism technique, sequencing of the coding axons 5-8 of the p 53 gene is usually done

The expression of the p 53 protein is analyzed by immunohistochemistry. In a study, 66.67% point mutation were detected in the p 53 gene. CC to TT double base changes (tandem mutations which are known to be caused only by the UV were not detected in any of the mutations. Correlation between the p 53 mutation and expression were found to be statistically significant ( $P < 0.007$ ). Among the cancers, the sebaceous carcinoma of the eyelid may be one of those showing most frequent mutation of the p 53 gene which may not be caused by exposure to UV.

**Sebaceous carcinoma in young age and P 53 correlation:** Authors described a sebaceous carcinoma presenting in a 32 year-old woman. This case was previously included in a series of seven cases[73]. Here, we revisit this case to provide further clinical, histopathological and molecular studies. The case emphasizes that this highly aggressive cancer can occur in young patients without history of retinoblastoma, radiation therapy, or hereditary cancer syndrome. Finally, the case suggests that the role of UV radiation and p53 mutations in sebaceous carcinoma deserve further study.

**Pathologic and molecular observations:** In a study, the initial full thickness wedge biopsy revealed in a study a moderately well differentiated sebaceous carcinoma (grade II [74]). Subsequently, the upper eyelid was removed under frozen section control between the medial and lateral canthal angles, and to the fornix superiorly. Histologically, the tumor filled the eyelid replacing most of the tarsus. The deep surgical margin was found to be focally involved. The tumor had a lobular pattern and extensively invaded the tarsus, dermis and muscle. There was no Pagetoid involvement of the conjunctiva or epidermis. Mitotic figures were numerous, and often atypical in appearance. In most areas, the cytoplasm contained small but distinct Oil-red-O positive vacuoles. These vacuoles did not stain with mucicarmine or periodic acid-Schiff (data not illustrated). The tumor was previously shown to stain focally for epithelial membrane antigen and p21<sup>WAF1/CIP1</sup>; Bcl-2 was negative as was HPV by *in situ* hybridization and PCR[73]; p53 showed striking nuclear positivity[73].

To know the nature of the mutation responsible for the p53 nuclear accumulation, we sequenced exons 5 through 9. To do this, DNA from a tumor metastasis was extracted. Hematoxylin & eosin stained frozen sections were used to establish that the portion of the tissue used for the DNA extraction consisted only of

tumor without contaminating normal tissue. The DNA was extracted and purified by acid-phenol chloroform[75]. From the purified tumor genomic DNA, p53 exons 5 and 6, and 7 through 9 were amplified separately by PCR, and subjected to automated fluorescence DNA sequencing using magnetic beads, and dye-primer and dye-terminating chemistries. The strategy and primers used have been previously described[73]. DNA sequencing identified a G:C→A:T (GGA to AGA) missense mutation at a dipyrimidine site in exon 6. The mutation results in substitution of arginine for the highly conserved glycine at codon 199 located at the dimer-dimer interface. Energy minimization modeling anticipates that this substitution will significantly alter the ionic environment at the p53 dimer-dimer interface.

Epidemiological studies suggest a role of sunlight and radiation in sebaceous carcinoma. A recent retrospective study of 1,349 cases, showed that Caucasians are more frequently affected with sebaceous carcinoma compared to Asian/Pacific Islanders and Blacks[76]. Furthermore, Rao et al. (1982) found only four Blacks among 75 patients with sebaceous carcinoma[77], and Zürcher et al. (1998) noted no black patients in their series of 43 cases (42, Caucasian; one, Chinese)[78]. Finally, sebaceous carcinoma has occurred at non-ocular sites in the setting of radiation exposure[79-80] and sunlight[81]. Interestingly, the G199R substitution detected in our patient was due to a G:C→A:T mutation at a dipyrimidine site (GGA to AGA, sense strand; TCC to TCT, antisense strand). UV light is known to cause C→T substitutions at dipyrimidines, or CC→TT substitutions in the p53 gene[80]. Although this class of mutation is typical of UV light induced mutations, it does not prove that the mutation was caused by UV exposure. Among 11 cases of sebaceous carcinoma with documented p53 mutations, 5 showed C→T mutations at dipyrimidine sites[83]. An additional reported case from a 75 year-old woman showed a G:C→T:A typical of bulky carcinogens[73]. The diversity of mutations suggests that different mechanisms may play a role in different cases (Table 1). Known p53 mutations in ocular sebaceous carcinoma.

**Table 1: Different cases with known p 53 mutation**

Age / sex	Site	Mutation			
		Location	Codon	Amino acid	Type
3 yrs/F [79]	Lower lid	Exon 5	TACt to TAGt	Y126stop	C:G→G:C
5 yrs/M [79]	Upper lid	Exon 5	GTG to ATG	V173M	G:C→A:T
36 yrs/F [79]	Lower lid	Exon 5	CGC to CAC	R175H	G: C→A:T
78 yrs/M [79]	Upper lid	Exon 6	CAT to CGT, AGT to GGT	H193R, S215G	A:T→G:C A:T→G:C
2 yrs/F*	Upper lid	Exon 6	GG A to AG A	G199R	G:C→A:T
85 yrs/M [79]	Lower lid	Exon 7	GG C to AG C	G245S	G:C→A:T
42 yrs/M [82]	NP	Exon 7	cC GG to cT GG	R248Y	C:G→T:A
76 yrs/F [79]	Lower lid	Exon 7	cC GG to cT GG	R248W	C:G→T:A
61 yrs/M [15]	Lower lid	Exon 8	gG TG to gA TG	V272M	G:C→A:T
61 yrs/F [15]	Upper lid	Exon 8	TGT to TAT	C275Y	G:C→A:T
75 yrs/F [3]	Lower lid	Exon 8	TGT to TTT	C277F	G:C→T:A
47 yrs/F [15]	Upper lid	Int 1	TGg t to TGt t	NA	G:C→T:A
68 yrs/M [15]	Lower lid	Int 1	agG T to aaG T	NA	G:C→A:T

Clinical data and molecular studies suggest that G199R interferes with p53 function. Early X-ray structures of p53 showed that the known "hot-spot" mutations are often involved in DNA binding. However, codon 199 lies outside the direct DNA-protein binding site. Nevertheless, missense mutations of this codon are listed in 48 tumors in the International Agency for Research on Cancer database[82]. Of those, 12 are G199R substitutions[82]. In many of these cases, a link between G199R and p53 function can be seen. Cyclophosphamide induced bladder cancer is more commonly associated with G199R compared to sporadic, smoking-related and schistosomiasis-linked tumors[83]. In a study of giant cell glioblastomamultiforme, G199R was more often associated with evidence for microsatellite instability compared to other mutations[8]. G199R, which was observed in BRCA-1 associated familial breast cancer [85], shows reduced activity in yeast transactivation capacity assays. Thus, although not directly involved in DNA-protein binding, G199 appears to have a critical role in p53 function.

X-ray crystallography is providing key insights into the structure-function significance of p53 mutations[86]. An emerging picture is that p53 functions as homotetrameric complexes interacting with the DNA helix, and a multitude of regulatory proteins. DNA-p53 and p53-p53 monomer contacts are important in stabilizing the tetrameric complex. The tetramer is composed of two p53 dimers each straddling the DNA helix. The dimers come together through binding closely spaced DNA decameric half-sites[87,88]. The resulting dimer-dimer is further stabilized by specific p53-p53 interaction sites. G199, which is located in such a key interface termed "patch I", makes critical contacts with residues of the adjacent p53 monomer[88].

To evaluate the effect of the arginine substitution, in silico energy minimization within a 10Å sphere

surrounding G199R was performed using the Molecular Operating Environment. Although the analysis anticipates only a subtle conformational change in the interface site, the electrostatic environment is significantly altered. The arginine residue affects interactions with other amino acids much more than the neutral glycine residue originally did. The modeling predicts that the substitution of arginine for glycine at position 199 will neutralize negative charges contributed by nearby inter- and intramonomeric glutamate residues (E171 and E198, respectively). It is therefore likely that G199R would destabilize the tetramer, acting in a dominant negative manner reducing its DNA affinity, and disrupting cooperative interactions between its subunits, and perhaps regulatory proteins. Taken together, the above observations suggest that G199R probably contributed to the molecular events leading to the development of sebaceous carcinoma in this patient.

In summary, the present review on the sebaceous carcinoma emphasizes that young age should not exclude consideration of sebaceous carcinoma. Further studies are needed to determine if sebaceous carcinoma may arise through different sets of environmental factors.

Immunohistochemical evaluation of several markers, including p53, Ki-67, bcl-2, and p21, may be diagnostically useful in cases of incompletely sampled, difficult, or borderline sebaceous lesions. As a potential practical application of these results, we would recommend using a panel including p53, Ki-67, p21, and bcl-2 for difficult cases in which the following results would favor sebaceous carcinoma over a benign lesion.

## References

1. Shalin SC, Lyle S, Calonje E, Lazar A. Sebaceous neoplasia and the Muir-Torre syndrome: important

- connections with clinical implications. *Histopathology* 2010;56(1):133-47.
2. Song A, Carter KD, Syed NA, et al. Sebaceous cell carcinoma of the ocular adnexa: clinical presentations, histopathology, and outcomes. *Ophthalm Plast Reconstr Surg.* 2008 May-Jun. 24(3):194-200. [Medline].
  3. Kass LG, Hornblass A. Sebaceous carcinoma of the ocular adnexa. *Surv Ophthalmol.* 1989 May-Jun. 33(6):477-90. [Medline].
  4. Gomes CC, Lacerda JC, Pimenta FJ, do Carmo MA, Gomez RS. Intraoral sebaceous carcinoma. *Eur Arch Otorhinolaryngol.* 2007 Jul. 264(7):829-32.[Medline]
  5. Jacobs DM, Sandles LG, Leboit PE. Sebaceous carcinoma arising from Bowen's disease of the vulva. *Arch Dermatol.* 1986 Oct. 122(10):1191-3.[Medline]
  6. Tan O, Ergen D, Arslan R. Sebaceous carcinoma on the scalp. *Dermatol Surg.* 2006 Oct. 32(10):1290-3.[Medline]
  7. Pusiol T, Morichetti D, Zorzi MG. Sebaceous carcinoma of the vulva: critical approach to grading and review of the literature. *Pathologica.* 2011 Jun. 103(3):64-7.[Medline]
  8. Nelson BR, Hamlet KR, Gillard M, Railan D, Johnson TM. Sebaceous carcinoma. *J Am Acad Dermatol.* 1995 Jul. 33(1):1-15; quiz 16-8.[Medline]
  9. Shields JA, Demirci H, Marr BP, Eagle RC Jr, Shields CL. Sebaceous carcinoma of the ocular region: a review. *Surv Ophthalmol.* 2005 Mar-Apr. 50(2):103-22.[Medline]
  10. Doxanas MT, Green WR. Sebaceous gland carcinoma. Review of 40 cases. *Arch Ophthalmol.* 1984 Feb. 102(2):245-9. [Medline].
  11. Maurya R P, Bhatia RP, Thakur V, Maurya OPS, Kumar M. A clinic-pathological study of meibomian gland carcinoma. *Ann Ophthalmol* 1997;29(1):27-30.
  12. Khan JA, Grove AS Jr, Joseph MP, Goodman M. Sebaceous carcinoma. Diuretic use, lacrimal system spread, and surgical margins. *Ophthalm Plast Reconstr Surg.* 1989. 5(4):227-34.[Medline]
  13. Maurya R P, Singh VP, Singh MK, Jain P, Kuwanr A. Recurrent Meibomian gland carcinoma of lower eyelid in male: A case report. *Ind J ClinExpOphthalmol.*2015;1(3):181-183.
  14. Song A, Carter KD, Syed NA, Song J, Nerad JA. Sebaceous cell carcinoma of the ocular adnexa: clinical presentations, histopathology, and outcomes. *Ophthalm Plast Reconstr Surg.* 2008 May-Jun. 24(3):194-200.[Medline]
  15. Wolfe JT 3rd, Yeatts RP, Wick MR, Campbell RJ, Waller RR. Sebaceous carcinoma of the eyelid. Errors in clinical and pathologic diagnosis. *Am J Surg Pathol.* 1984 Aug. 8(8):597-606.[Medline]
  16. Ni C, Searl SS, Kuo PK, Chu FR, Chong CS, Albert DM. Sebaceous cell carcinomas of the ocular adnexa. *Int Ophthalmol Clin.* 1982 Spring. 22(1):23-61.[Medline]
  17. Berlin AL, Amin SP, Goldberg DJ. Extraocular sebaceous carcinoma treated with Mohs micrographic surgery: report of a case and review of literature. *Dermatol Surg.* 2008 Feb. 34(2):254-7.[Medline]
  18. Husain A, Blumenschein G, Esmaeli B. Treatment and outcomes for metastatic sebaceous cell carcinoma of the eyelid. *Int J Dermatol.* 2008 Mar. 47(3):276-9.[Medline]
  19. Sung D, Kaltreider SA, Gonzalez-Fernandez F. Early onset sebaceous carcinoma. *Diagn Pathol.* 2011 Sep 5. 6:81.[Medline][Full Text]
  20. Pang P, Rodriguez-Sains RS. Ophthalmologic oncology: sebaceous carcinomas of the eyelids. *J Dermatol Surg Oncol.* 1985 Mar. 11(3):260-4.[Medline]
  21. Schwartz RA, Torre DP. The Muir-Torre syndrome: a 25-year retrospect. *J Am Acad Dermatol.* 1995 Jul. 33(1):90-104.[Medline]
  22. Gonzalez-Fernandez F, Kaltreider SA, Patnaik BD, Retief JD, Bao Y, Newman S, Stoler MH, Levine PA: Sebaceous carcinoma. Tumor progression through mutational inactivation of p53. *Ophthalmology.* 1998,105(3):497-506. 10.1016/S0161-6420(98)93034-2.View Article PubMed
  23. Kiyosaki K, Nakada C, Hijiya N, Tsukamoto Y, Matsuura K, Nakatsuka K, Daa T, Yokoyama S, Imaizumi M, Moriyama M: Analysis of p53 mutations and the expression of p53 and p21WAF1/CIP1 protein in 15 cases of sebaceous carcinoma of the eyelid. *Invest Ophthalmol Vis Sci.* 2010,51(1):7-11. 10.1167/iovs.09-4127.View Article PubMed
  24. Kivela T, Asko-Seljavaara S, Pihkala U, Hovi L, Heikkonen J: Sebaceous carcinoma of the eyelid associated with retinoblastoma. *Ophthalmology.* 2001,108(6):1124-1128. 10.1016/S0161-6420(01)00555-3. View Article PubMed
  25. Yen MT, Tse DT: Sebaceous cell carcinoma of the eyelid and the human immunodeficiency virus. *Ophthalm Plast Reconstr Surg.* 2000,16(3):206-210. 10.1097/00002341-200005000-00007. View Article PubMed
  26. Hayashi N, Furihata M, Ohtsuki Y, Ueno H: Search for accumulation of p53 protein and detection of human papillomavirus genomes in sebaceous gland carcinoma of the eyelid. *Virchows Arch.* 1994,424(5):503-509. View Article PubMed
  27. Rao NA, Hidayat AA, McLean IW, Zimmerman LE. Sebaceous carcinomas of the ocular adnexa: a clinicopathologic study of 104 cases, with five-year follow-up data. *Hum Pathol* 1982;13:113-22.
  28. Shet T, Kelkar G, Juvekar S, Mistry R, Borges A. Masquerade syndrome: sebaceous carcinoma presenting as an unknown primary with pagetoid spread to the nasal cavity. *J Laryngol Otol* 2004;118(4):307-9.
  29. Ozdal PC, Codère F, Callejo S, Caissie AL, Burnier MN. Accuracy of the clinical diagnosis of chalazion. *Eye (Lond)* 2004;18(2):135-8.
  30. Leibovitch I, Selva D, Huilgol S, Davis G, Dodd T, James CL. Intraepithelial sebaceous carcinoma of the eyelid misdiagnosed as Bowen's disease. *J CutanPathol* 2006;33(4):303-8.
  31. Muqit MM, Foot B, Walters SJ, Mudhar HS, Roberts F, Rennie IG. Observational prospective cohort study of patients with newly diagnosed ocular sebaceous carcinoma. *Br J Ophthalmol* 2013;97(1):47-51.
  32. Wali UK, Al-Mujaini A. Sebaceous gland carcinoma of the eyelid. *Oman J Ophthalmol* 2010;3(3):117-21.
  33. Sinard JH. Immunohistochemical distinction of ocular sebaceous carcinoma from basal cell and squamous cell carcinoma. *Ophthalmology* 1999;117(6):776-83.
  34. Beach A, Severance AO. Sebaceous gland Carcinoma. *Ann Surg.* 1942 Feb. 115(2):258-66. [Medline]
  35. Schwartz RA, Torre DP. The Muir-Torre syndrome: a 25-year retrospect. *J Am Acad Dermatol.* 1995 Jul. 33(1):90-104.[Medline]
  36. Pang P, Rodriguez-Sains RS. Ophthalmologic oncology: sebaceous carcinomas of the eyelids. *J Dermatol Surg Oncol.* 1985 Mar. 11(3):260-4.[Medline]
  37. Rao NA, Hidayat AA, McLean IW, Zimmerman LE. Sebaceous carcinomas of the ocular adnexa: A

- clinicopathologic study of 104 cases, with five-year follow-up data. *Hum Pathol.* 1982 Feb. 13(2):113-22.[Medline]
38. Arshad AR, Azman WS, Kreetharan A. Solitary sebaceous nevus of Jadassohn complicated by squamous cell carcinoma and basal cell carcinoma. *Head Neck.* 2008 Apr. 30(4):544-8.[Medline]
  39. Duncan A, Wilson N, Leonard N. Squamous cell carcinoma developing in a naevus sebaceous of Jadassohn. *Am J Dermatopathol.* 2008 Jun. 30(3):269-70.[Medline]
  40. Kazakov DV, Calonje E, Zelger B, et al. Sebaceous carcinoma arising in nevus sebaceus of Jadassohn: a clinicopathological study of five cases. *Am J Dermatopathol.* 2007 Jun. 29(3):242-8.[Medline]
  41. Matsuda K, Doi T, Kosaka H, Tasaki N, Yoshioka H, Kakibuchi M. Sebaceous carcinoma arising in nevus sebaceus. *J Dermatol.* 2005 Aug. 32(8):641-4.[Medline]
  42. Miller CJ, Ioffreda MD, Billingsley EM. Sebaceous carcinoma, basal cell carcinoma, trichoadenoma, trichoblastoma, and syringocystadenoma papilliferum arising within a nevus sebaceus. *Dermatol Surg.* 2004 Dec. 30(12 Pt 2):1546-9.[Medline]
  43. Wang E, Lee JS, Kazakov DV. A rare combination of sebaceoma with carcinomatous change (sebaceous carcinoma), trichoblastoma, and poroma arising from a nevus sebaceus. *J CutanPathol.* 2013 Jul. 40(7):676-82.[Medline]
  44. Izumi M, Tang X, Chiu CS, Nagai T, Matsubayashi J, Iwaya K. Ten cases of sebaceous carcinoma arising in nevus sebaceus. *J Dermatol.* 2008 Nov. 35(11):704-11.[Medline]
  45. Barkham MC, White N, Brundler MA, Richard B, Moss C. Should naevussebaceus be excised prophylactically? A clinical audit. *J Plast Reconstr Aesthet Surg.* 2007. 60(11):1269-70.[Medline]
  46. Jayaraj P, Sen S, Sharma A, Chosdol K, Kashyap S, Rai A. Epigenetic inactivation of the E-cadherin gene in eyelid sebaceous gland carcinoma. *Br J Dermatol.* 2012 Sep. 167(3):583-90.[Medline]
  47. Mulay K, Shah SJ, Aggarwal E, White VA, Honavar SG. Periocular sebaceous gland carcinoma: do androgen receptor (NR3C4) and nuclear survivin (BIRC5) have a prognostic significance? *Acta Ophthalmol.* 2014 Dec. 92(8):e681-7.[Medline]
  48. Shields JA, Demirci H, Marr BOP, et al. Sebaceous carcinoma of the eyelids: personal experience with 60 cases. *Ophthalmology* 2004;111:2151-7.
  49. Muthusamy K, Halbert G, Roberts F. Immunohistochemical staining for adipophilin, perilipin and TIP47. *J Clin Pathol* 2006;59:1166-70.
  50. Ostler DA, Prieto VG, Reed JA, Deavers MT, Lazar AJ, Ivan D. Adipophilin expression in sebaceous tumours and other cutaneous lesions with clear cell histology: an immunohistochemical study of 117 cases. *Mod Pathol* 2010;23:567-73.
  51. Alhumaidi A. Practical immunohistochemistry of epithelial skin tumor. *Indian J Dermatol Venereol Leprol* 2012;78(6):698-708.
  52. Asadi-Amoli F, Khoshnevis F, Haeri H, Jahanzad I, Pazira R, Shahsiah R. Comparative examination of androgen receptor reactivity for differential diagnosis of sebaceous carcinoma from squamous cell and basal cell carcinoma. *Am J ClinPathol* 2010;134(1):22-6.
  53. Sramek B, Lisle A, Loy T. Immunohistochemistry in ocular carcinomas. *J CutanPathol* 2008;35(7):641-6.
  54. Bayer-Garner IB, Givens V, Smoller B. Immunohistochemical staining for androgen receptors: a sensitive marker of sebaceous differentiation. *Am J Dermatopathol* 1999;21(5):426-31.
  55. Ansai S, Takeichi H, Arase S, Kawana S, Kimura T. Sebaceous carcinoma: an immunohistochemical reappraisal. *Am J Dermatopathol* 2011;33(6):579-87.
  56. Clarke LE, Conway AB, Warner NM, Barnwell PN, Sceppa J, Helm KF. Expression of CK7, Cam 5.2 and Ber-Ep4 in cutaneous squamous cell carcinoma. *J Cutan Pathol.* 2013 Mar 1. doi: 10.1111/cup.12135. Epub ahead of print.
  57. Song A, Carter KD, Syed NA, et al. Sebaceous cell carcinoma of the ocular adnexa: clinical presentations, histopathology, and outcomes. *Ophthal Plast Reconstr Surg* 2008;24:194-200.
  58. Okan G, Vural P, Ince Ü, Yazar A, Uras C, Saruç M. Muir-Torre syndrome: a case report and review of the literature. *Turk J Gastroenterol* 2012;23(4):394-8.
  59. Rishi K, Font RL. Sebaceous gland tumors of the eyelids and conjunctiva in the Muir-Torre syndrome: a clinicopathologic study of five cases and literature review. *Ophthal Plast Reconstr Surg* 2004;20(1):31-6.
  60. Gaskin JB, Fernando BS, Sullivan CA, Whitehead K, Sullivan TJ. The significance of DNA mismatch repair genes in the diagnosis and management of periocular sebaceous cell carcinoma and Muire Torre syndrome. *Br J Ophthalmol* 2011;95(12):1686-90.
  61. Honchel R, Halling KC, Schaid DJ, et al. Microsatellite instability in Muire Torre syndrome. *Cancer Res* 1994;54:1159-63.
  62. Cohen PR, Kohn SR, Kurzrock R. Association of sebaceous gland tumors and internal malignancy: the Muire Torre syndrome. *Am J Med* 1991;90:606-13.
  63. Landis MN, Davis CL, Bellus GA, Wolverton SE. Immunosuppression and sebaceous tumors: a confirmed diagnosis of Muir-Torre syndrome unmasked by immunosuppressive therapy. *J Am Acad Dermatol.* 2011 Nov. 65(5):1054-1058.e1.[Medline]
  64. Boennelycke M, Thomsen BM, Holck S. Sebaceous neoplasms and the immunoprofile of mismatch-repair proteins as a screening target for syndromic cases. *Pathol Res Pract.* 2014 Oct 23.[Medline]
  65. Nemoto Y, Arita R, Mizota A, Sasajima Y. Differentiation between chalazion and sebaceous carcinoma by noninvasive meibography. *Clin Ophthalmol.* 2014. 8:1869-75.[Medline]
  66. Harvey JT, Anderson RL. The management of meibomian gland carcinoma. *Ophthalmic Surg.* 1982 Jan. 13(1):56-61.[Medline]
  67. Hood IC, Qizilbash AH, Salama SS, Young JE, Archibald SD. Needle aspiration cytology of sebaceous carcinoma. *Acta Cytol.* 1984 May-Jun. 28(3):305-12.[Medline]
  68. Maheshwari R, Maheshwari S, Shekde S. Role of fine needle aspiration cytology in diagnosis of eyelid sebaceous carcinoma. *Indian J Ophthalmol.* 2007 May-Jun. 55(3):217-9.[Medline]
  69. Goyal S, Honavar SG, Naik M, Vemuganti GK. Fine needle aspiration cytology in diagnosis of metastatic sebaceous gland carcinoma of the eyelid to the lymph nodes with clinicopathological correlation. *Acta Cytol.* 2011. 55(5):408-12.[Medline]
  70. Putterman AM. Conjunctival map biopsy to determine pagetoid spread. *Am J Ophthalmol.* 1986 Jul 15. 102(1):87-90.[Medline]
  71. Rapini RP. Sebaceous Neoplasms. Practical Dermatopathology. Elsevier Inc; 2005.283-4.
  72. Shahi MH, Diaz E. Transcription factor targets as treatment for medulloblastoma. In: Abujamra AL editor,

- Brain tumours – current and emerging therapeutic strategies, In Tech; 2011. DOI: 10.5772/21658. Available from: <http://www.intechopen.com/books/brain-tumors-current-and-emerging-therapeutic-strategies/transcription-factor-targets-as-treatment-for-medulloblastoma>.
73. Gonzalez-Fernandez F, Kaltreider SA, Patnaik BD, Retief JD, Bao Y, Newman S, Stoler MH, Levine PA: Sebaceous carcinoma. Tumor progression through mutational inactivation of p53. *Ophthalmology*. 1998,105(3):497-506. 10.1016/S0161-6420(98)93034-2. View Article PubMed
  74. Wolfe JT, Yeatts RP, Wick MR, Campbell RJ, Waller RR: Sebaceous carcinoma of the eyelid. Errors in clinical and pathologic diagnosis. *Am J Surg Pathol*. 1984,8(8):597-606. 10.1097/00000478-198408000-00003. View Article PubMed
  75. Chomczynski P: A reagent for the single-step simultaneous isolation of RNA, DNA and proteins from cell and tissue samples. *Biotechniques*. 1993,15(3):532-534. 536-537. PubMed
  76. Dasgupta T, Wilson LD, Yu JB: A retrospective review of 1349 cases of sebaceous carcinoma. *Cancer*. 2009,115(1):158-165. 10.1002/cncr.23952. View Article PubMed
  77. Rao NA, Hidayat AA, McLean IW, Zimmerman LE: Sebaceous carcinomas of the ocular adnexa: A clinicopathologic study of 104 cases, with five-year follow-up data. *Hum Pathol*. 1982,13(2):113-122. 10.1016/S0046-8177(82)80115-9. View Article PubMed
  78. Zurcher M, Hintschich CR, Garner A, Bunce C, Collin JR: Sebaceous carcinoma of the eyelid: a clinicopathological study. *Br J Ophthalmol*. 1998,82(9):1049-1055. 10.1136/bjo.82.9.1049. PubMed Central View Article PubMed
  79. Dowd MB, Kumar RJ, Sharma R, Murali R: Diagnosis and management of sebaceous carcinoma: an Australian experience. *ANZ J Surg*. 2008,78(3):158-163. 10.1111/j.1445-2197.2007.04393.x. View Article PubMed
  80. Justi RA: Sebaceous carcinoma; report of case developing in area of radiodermatitis. *AMA Arch Derm*. 1958,77(2):195-200. 10.1001/archderm.1958.01560020047005. View Article PubMed
  81. Constant E, Leahy MS: Sebaceous cell carcinoma. *Plast Reconstr Surg*. 1968,41(5):433-437. 10.1097/00006534-196805000-00003. View Article PubMed
  82. Brash DE, Rudolph JA, Simon JA, Lin A, McKenna GJ, Baden HP, Halperin AJ, Ponten J: A role for sunlight in skin cancer: UV-induced p53 mutations in squamous cell carcinoma. *Proc Natl Acad Sci USA*. 1991,88(22):10124-10128. 10.1073/pnas.88.22.10124. PubMed Central View Article PubMed
  83. Kiyosaki K, Nakada C, Hijjiya N, Tsukamoto Y, Matsuura K, Nakatsuka K, Daa T, Yokoyama S, Imaizumi M, Moriyama M: Analysis of p53 mutations and the expression of p53 and p21WAF1/CIP1 protein in 15 cases of sebaceous carcinoma of the eyelid. *Invest Ophthalmol Vis Sci*. 2010,51(1):7-11. 10.1167/iovs.09-4127. View Article PubMed
  84. Becker K, Goldberg M, Helmbold P, Holbach LM, Loeffler KU, Ballhausen WG: Deletions of BRCA1/2 and p53 R248W gain-of-function mutation suggest impaired homologous recombination repair in fragile histidine triad-negative sebaceous gland carcinomas. *Br J Dermatol*. 2008,159(6):1282-1289. 10.1111/j.1365-2133.2008.08783.x. View Article PubMed
  85. Inga A, Storici F, Darden TA, Resnick MA: Differential transactivation by the p53 transcription factor is highly dependent on p53 level and promoter target sequence. *Mol Cell Biol*. 2002,22(24):8612-8625. 10.1128/MCB.22.24.8612-8625.2002. PubMed Central View Article PubMed
  86. Joerger AC, Fersht AR: Structure-function-rescue: the diverse nature of common p53 cancer mutants. *Oncogene*. 2007,26(15):2226-2242. 10.1038/sj.onc.1210291. View Article PubMed
  87. Funk WD, Pak DT, Karas RH, Wright WE, Shay JW: A transcriptionally active DNA-binding site for human p53 protein complexes. *Mol Cell Biol*. 1992,12(6):2866-2871. PubMed Central View Article PubMed
  88. el-Deiry WS, Kern SE, Pietenpol JA, Kinzler KW, Vogelstein B: Definition of a consensus binding site for p53. *Nat Genet*. 1992,1(1):45-49. 10.1038/ng0492-45. View Article PubMed
  89. Chen Y, Dey R, Chen L: Crystal structure of the p53 core domain bound to a full consensus site as a self-assembled tetramer. *Structure*. 2010,18(2):246-256. 10.1016/j.str.2009.11.011. PubMed Central View Article PubMed