

Ocular surface squamous neoplasia (OSSN)

Jayasri Krishnaraj^{1,*}, Sagnik Surya Das², Kalaimamani Ezhil Vendhan³

¹Associate Professor, ²Postgraduate Student, ³Professor & HOD, Vinayaka Mission Kirupananda Variyar Medical College, Salem, Tamil Nadu, India.

***Corresponding Author:**

Email: jayasridr@gmail.com

Abstract

OSSN is the third most common conjunctival malignancy worldwide and is commonest in the tropics. It is a tumor of the elderly and is usually misdiagnosed, as it resembles benign conditions like pinguecula and pterygium. We are now equipped with a wide array of investigative modalities ranging from Impression cytology to confocal microscopy. Treatment of choice for OSSN is surgical excision with cryotherapy and may be combined with other modalities like immunotherapy, topical chemotherapeutic agents and radiotherapy. Recently pegylated interferon has shown promising results in management of recurrent OSSN.

Key Words: Cryotherapy, Human Papilloma Virus, Impression cytology, Interferon, Squamous neoplasia

Introduction

Ocular surface squamous neoplasia (OSSN) is the term coined to denote the wide spectrum of dysplastic changes involving epithelium of conjunctiva, cornea and limbus. These tumors are rare but important because of their potential for causing ocular and even systemic morbidity and mortality. It includes squamous dysplasia, carcinoma-in-situ i.e., conjunctival and corneal intraepithelial neoplasia (CIN) and squamous cell carcinoma (SCC). Squamous lesions may involve conjunctiva or cornea, but more commonly begin in the conjunctiva and extend across the limbus to the adjacent cornea. First case of OSSN was described by Von Graefe¹ in 1860. The management of these lesions has changed significantly in the past decade.

The initial cases described in the literature were cases of squamous cell carcinoma.² Later it was recognized that both invasive and non-invasive types of squamous neoplasms occur.³⁻⁸ Various terminology used to describe the noninvasive forms include conjunctival dysplasia, intraepithelial epithelioma, epithelial plaque, dyskeratosis, Bowenoid epithelioma, and precancerous epithelioma. Jakobiec and Pizzarello⁹ classified conjunctival intraepithelial neoplasms as mild, moderate and severe dysplasia based on the extent of involvement. Mild lesions were those that involved the basal one-third of the conjunctiva, those involving the inner two-thirds were classified as moderate, and lesions that were full thickness were termed severe dysplasia.

Warring et al¹⁰ included cornea, and Erie et al¹¹ further included invasive neoplasia.

Ocular Surface Squamous Neoplasia (OSSN) was a term given by Lee and Hirst¹² which has three grades:

- a) Benign dysplasia
 1. Papilloma
 2. Pseudotheliomatous hyperplasia
- b) Pre-invasive OSSN
 1. Conjunctival/corneal carcinoma in situ
- c) Invasive OSSN
 1. Squamous carcinoma
 2. Mucoepidermoid carcinoma

Incidence: OSSN primarily affects older males.¹² Predominantly seen in dark skinned Caucasians and higher in areas closer to the equator. The average age of occurrence is in mid-60 years, ranging from 20 to 88 years, who have a history of extensive solar exposure.¹³ Various authors have placed the incidence between 0.02 to 3.5/100000.¹⁴ The incidence of carcinoma in situ lesions is 5-9 years lower than invasive OSSN. Xeroderma pigmentosa and human immune-deficiency virus (HIV) patients develop OSSN at an earlier age.

In the older population, OSSN is the third most common ocular tumor after melanoma and lymphoma.¹⁵ Benign lesions are three times as frequent as malignant lesions.

Etiology and Pathogenesis

1. **Ultraviolet-B light:** UV-B light causes damage to DNA. Risk factors for OSSN

include fair skin color, pale iris, increased exposure to sunlight. UV-B has also been shown to cause p53 gene mutation, which is associated with OSSN.¹⁶ Inability in repairing of DNA as in xeroderma pigmentosa (Fig.1) can also lead to OSSN.

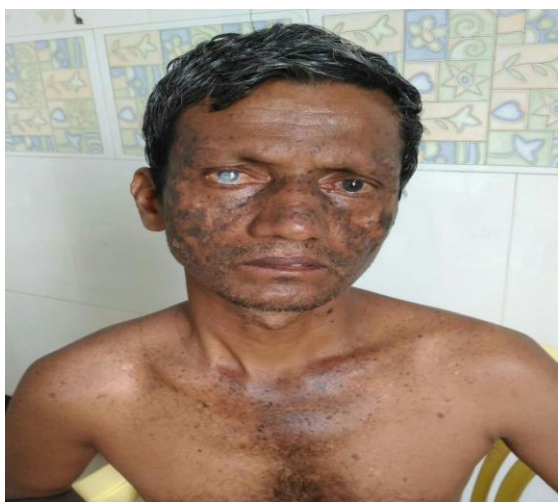

Fig. 1: Case of Xeroderma Pigmentosa, with ocular involvement

2. **Human Papilloma Virus:** HPV genotypes 6, 8 and 11 have been demonstrated in a large number of papillomas as well as dysplastic and malignant lesions of the cornea and conjunctiva. Scott et al demonstrated that HPV 16 and 18 cases prove a causal relationship. The protein coded by the E6 region of HPV 16 and 18 forms a complex with the protein coded by the p53 tumor suppressor gene in the host.¹⁷
3. **Stem cell theory:** UV-B irradiation and HPV cause damage to the limbal transition zone leading to abnormal maturation of corneal epithelium.
4. **Other causes:** People with HIV also tend to develop CIN at earlier age (less than 50 years). Some risk factors also include chemical

exposure (trifluridine, beryllium, arsenicals, petroleum products) cigarette smoking, vitamin A deficiency, and viruses like herpes simplex virus (HSV) Type I.

Clinical Features

The typical presentation of OSSN is a growth on the ocular surface. Symptoms are foreign body sensation, irritation, redness and rarely, diminution of vision due to high astigmatism or involvement of visual axis. It usually starts in inter-palpebral conjunctiva and then grows across the limbus and then may or may not involve the cornea. Most OSSN lesions are slightly elevated and have a pearly grey appearance with tufts of vessels commonly known as sentinel vessels. Larger lesions have a greater likelihood of malignancy. Other features suggestive of malignant histology are- prominent epibulbar vasculature of the lesion, corneo-scleral or intraocular invasion, anterior orbital invasion and spontaneous bleeding.

Morphological Classification

Conjunctival Lesions

1. **Gelatinous:** Circumscribed gelatinous lesions (Fig. 2) are the most common. The nodular type (Fig. 3) is rapidly growing with a mulberry appearance and a high incidence of metastasis to adjacent lymph nodes. They are frequently accompanied by a leash of feeder vessels. The diffuse type (Fig. 4) can mimic a chronic conjunctivitis and thus delay the diagnosis.
2. **Leukoplakic:** They are well defined lesions with a keratinized surface and are usually pre-invasive. (Fig. 5)
3. **Papilliform:** This type typically are exophytic, strawberry like, with a stippled red appearance corresponding to its fibrovascular core (Fig. 6). They are clinically benign.

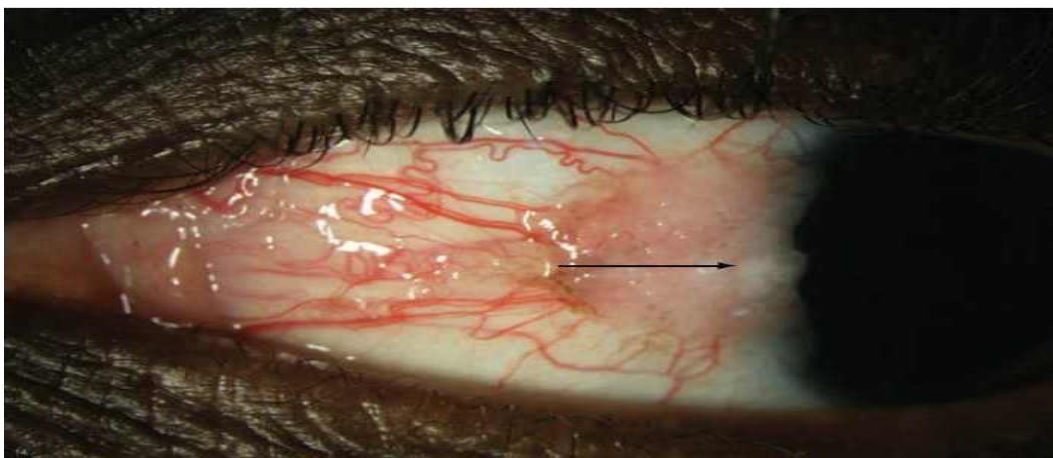


Fig. 2: Common Gelatinous variant of OSSN.

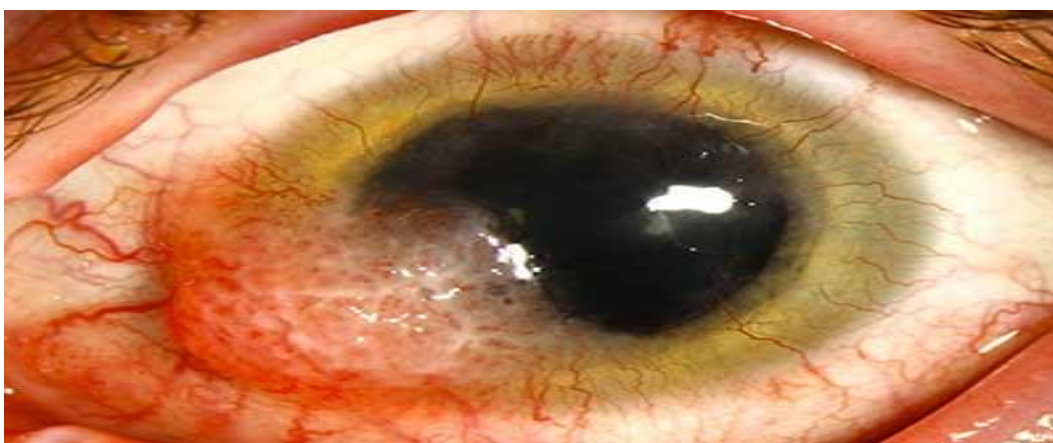


Fig. 3: Localized Nodular type of OSSN

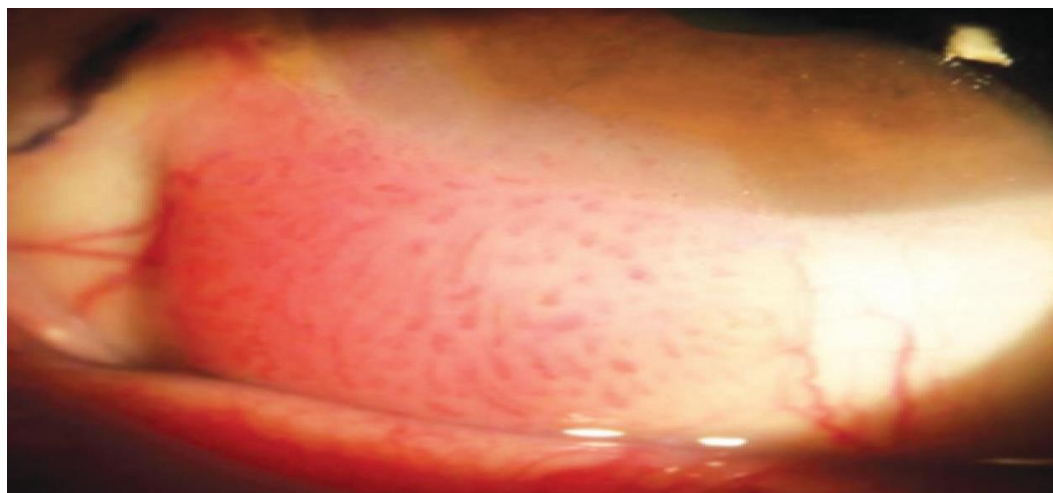


Fig. 4: Diffuse type of OSSN, which can be easily missed

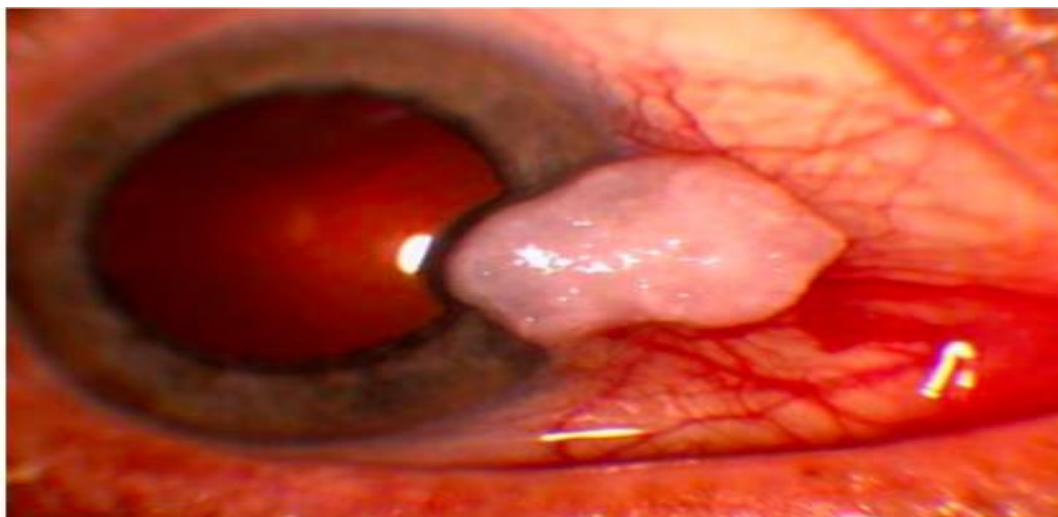


Fig. 5: Leukoplakic type of OSSN

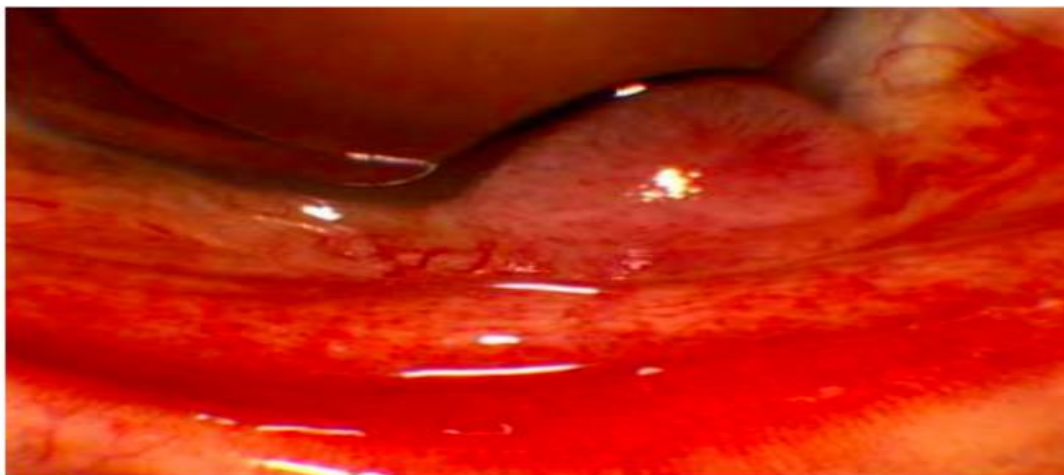


Fig. 6: Papilliform type of OSSN

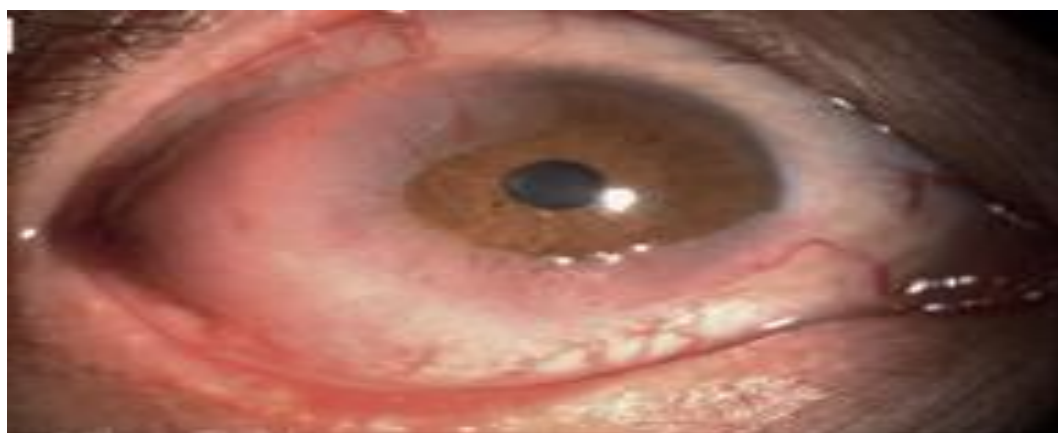


Fig. 7: Corneal involvement of OSSN

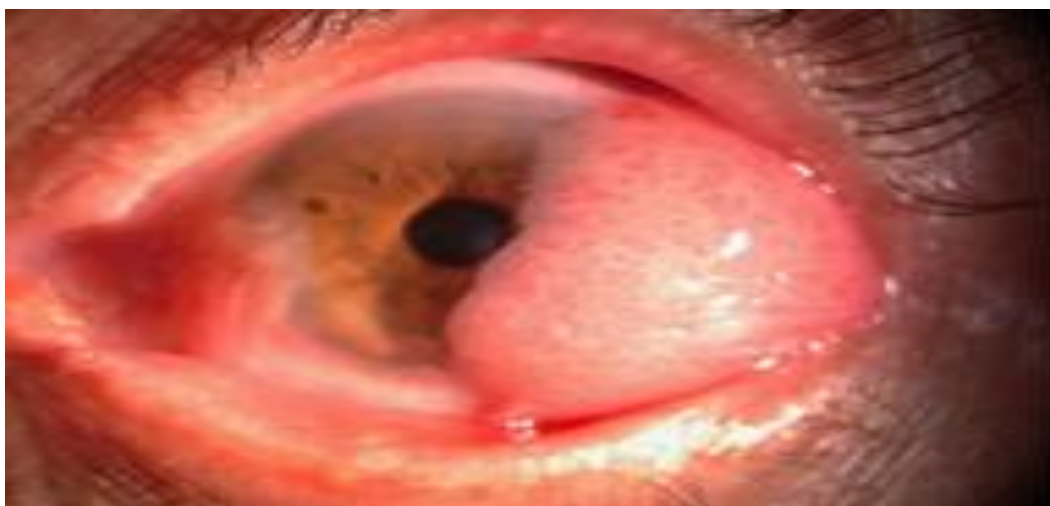


Fig 8: Mucoepidermoid Variant of OSSN: has a high risk of intra-ocular extension

Corneal Lesions: Corneal OSSN lesions are usually pre invasive, with a mottled ground glass appearance. They have sharply defined fimbriated borders (Fig. 7), the convex leading edge spreads away from the limbus. They are usually avascular. These lesions are slow growing, indolent and prone to recurrence.

The different variants of OSSN are mucoepidermoid carcinoma (Fig. 8), adenoid cystic carcinoma, and spindle cell carcinoma.

Metastasis: Metastasis occurs in 10-20% of the patients. In the early stages the clinical signs of intraocular and orbital extension are subtle. Warning signs are circumciliary injection, anterior chamber reaction, peripheral anterior synechiae, opaque sheet of cells on the iris surface, undiagnosed corneal perforation and irregular sclera with focal vascular tufts. In late stages they present with intraocular and orbital mass with disorganized anterior segment. Risk factors are long standing recurrent tumors-mucoepidermoid and adenoid squamous carcinoma. Distal metastasis are to the pre-auricular, cervical, submandibular lymph node, parotid gland, lungs and bones.

Differential Diagnosis: The differential diagnosis of OSSN include- Pinguecula, Pterygium, Dermoid, Choristoma, Lymphoma, Pannus, Papilloma, Vitamin A deficiency, Benign intraepithelial dyskeratosis, Pyogenic granuloma, Keratoacanthoma, pseudoepitheliomatous hyperplasia, malignant melanoma and naevi.

Diagnostic Tests

Exfoliative and Impression Cytology: A cytobrush is used to collect the exfoliated cells from the surface of the lesion. Malignant cells have poor cell to cell attachment and hence have a tendency to desquamate when located on the mucosal surface. Impression cytology using cellulose acetate paper (CAP) is a simple technique with added advantage of maintained cell-to-cell relationship.¹⁸ However, CAP specimens require immediate processing. A correlation of 80% between impression cytology and histopathology specimens obtained from incisional biopsy was seen. Biopore membrane is presently the procedure of choice due to a better cell adherence and storage for subsequent analysis.¹⁹

In the intraepithelial group, keratinized dysplastic cells, often accompanied by hyperkeratosis, and non-keratinized dysplastic cells are seen. In the invasive group, cells with mild to marked keratinization and prominent macronucleoli are described. Keratinization is used to monitor regression of lesion and response of the lesion to chemotherapeutic modulators. Mitomycin C (MMC) is used for the treatment of recurrent and extensive OSSN where extensive excision may compromise limbal stem cell function. Mc Kelvie et al have followed patients after treatment with MMC for OSSN. They used impression cytology in these cases and demonstrated eradication of malignant cells, mainly by apoptosis, and necrosis accompanied by inflammatory cells.²⁰

However using impression cytology as the only diagnostic tool has its pitfalls. In Keratinizing

malignancies there are false negatives because of paucity of cells in the specimen. Several patients may have histological CIN or partial thickness epithelial atypia just adjacent to the invasive disease, which may be missed if sampled by impression cytology. Endophytic lesions and orbital invasion cannot be identified with impression cytology, thus limiting its use as a diagnostic aid.

Histopathology

In small lesions the specimens are obtained from excision biopsies, where they can be removed in toto. In cases of large infiltrating lesions incisional biopsy is done. Papillomas demonstrate papillary fibro vascular fronds covered by acanthotic epithelium. Varying degrees of dysplasia (Fig. 9) can be seen, but the normal polarity and basal layers of the cell are often unremarkable. Preinvasive OSSN have been classified as mild, moderate or severe based on the degree of involvement of the dysplastic epithelium and the layers affected. They are characterized by an intact basement membrane without invasion of the underlying substantia propria.

1. **Mild- CIN grade I:** dysplasia confined to lower third of the epithelium.
2. **Moderate-CIN grade II:** dysplasia extends into the middle third.
3. **Severe-CIN grade III:** full thickness dysplasia, also called carcinoma-in-situ (Fig.10).

Invasive OSSN show nests of infiltrating cells that have penetrated the epithelial basement membrane (Fig. 11) and spread into the conjunctival substantia propria. These cells can may be well differentiated, easily recognizable, or poorly differentiated and difficult to differentiate. The latter are uncommon and more aggressive. Spindle cells and mucoepidermoid cells may be seen interspersed with squamous cells in these tumors.²¹

Anterior Segment Optical Coherence Tomography (ASOCT): Ultra high resolution spectral domain anterior segment OCT (UHR OCT) is a custom built OCT with an axial resolution of approximately 2microns for evaluation of corneal pathologic features.²²⁻²⁴ UHR OCT in ocular surface squamous neoplasia gives the epithelial thickening and increased reflectivity of the epithelium. Typically, there is sharp

disparity in reflectivity of normal and diseased epithelium which aids in exact localization of the tumor margins. The images of ocular surface squamous neoplasia using this may be helpful in the delineation of the tumor. It is a promising diagnostic aid which can be used to detect early subclinical recurrences.²⁵

Ultrasound Bio microscopy (UBM): UBM is an ultrasound guided contact bio microscopy which is helpful if corneal or scleral invasion is suspected.

Confocal Microscopy: Ocular surface cytological examination with in vivo confocal microscopy is a simple and relatively non- invasive diagnostic tool.^{26,27} In vivo confocal microscopy helps in the initial clinical diagnosis of OSSN, identification of recurrence and evaluation of response to topical chemotherapeutic agents in patients with ocular surface squamous lesions. Evaluation with confocal microscopy is capable distinguishing different stages of OSSN in all the cases.²⁸

Treatment

Surgery: The options for treatment range from simple excision to exenteration. Factors that influence the method of treatment include: The size and extent of the lesion, clinical invasiveness and location of the lesion, the health and age of the patient and the status of fellow eye. If the lesion is a discrete nodular limbal mass, it can be removed by simple excision with 2mm clearance.²⁹ If the lesion is strongly adherent to the sclera at the limbus, superficial lamellarkerato-sclerectomy²⁹ (Fig. 12) can be performed to ensure complete removal of the tumor.

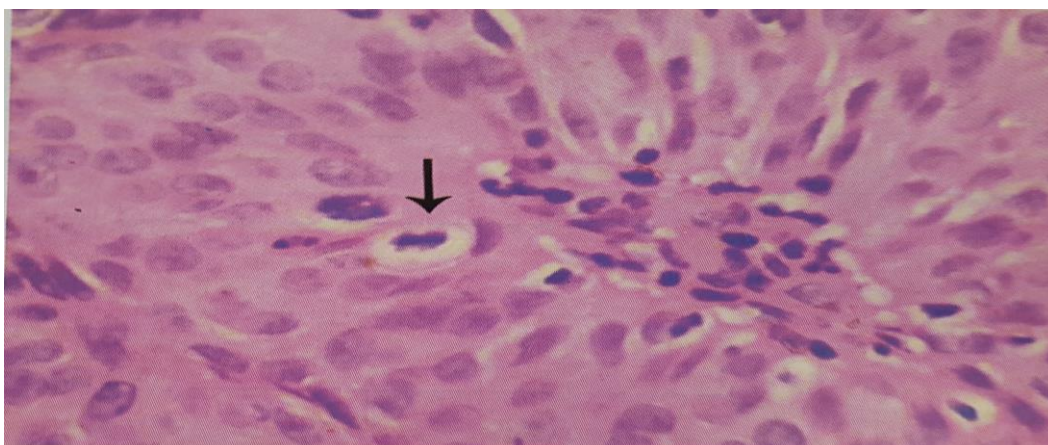


Fig. 9: Light photomicrograph of neoplastic cells with moderate amount of cytoplasm, hyperchromatic nuclei and mitotic figures (Courtesy: Dr. Geeta K. Vemuganti)

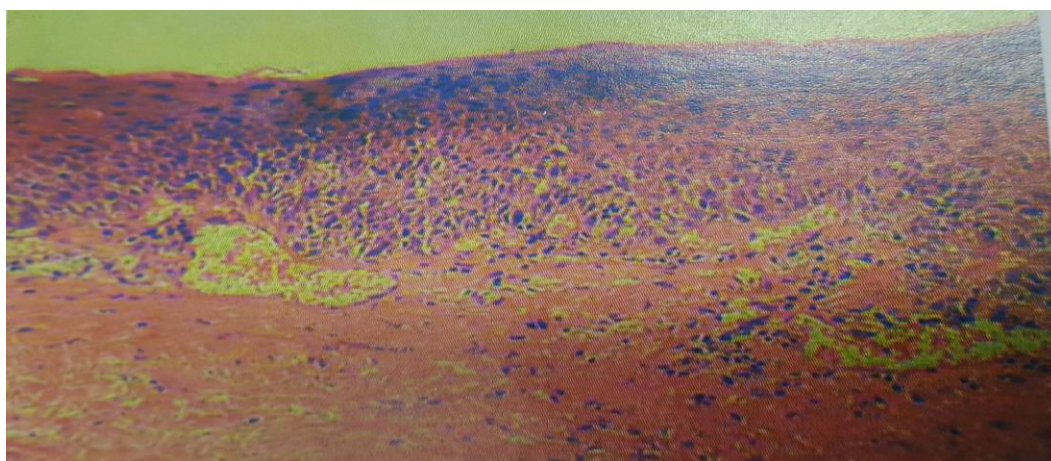


Fig. 10: Carcinoma in Situ: An in situ lesion with an intact basement membrane (Courtesy: Dr. Geeta K. Vemuganti)




Fig. 11: Invasive Squamous Cell Carcinoma: this section shows tumor cells infiltrating the underlying stroma (Courtesy: Dr. Geeta K. Vemuganti)

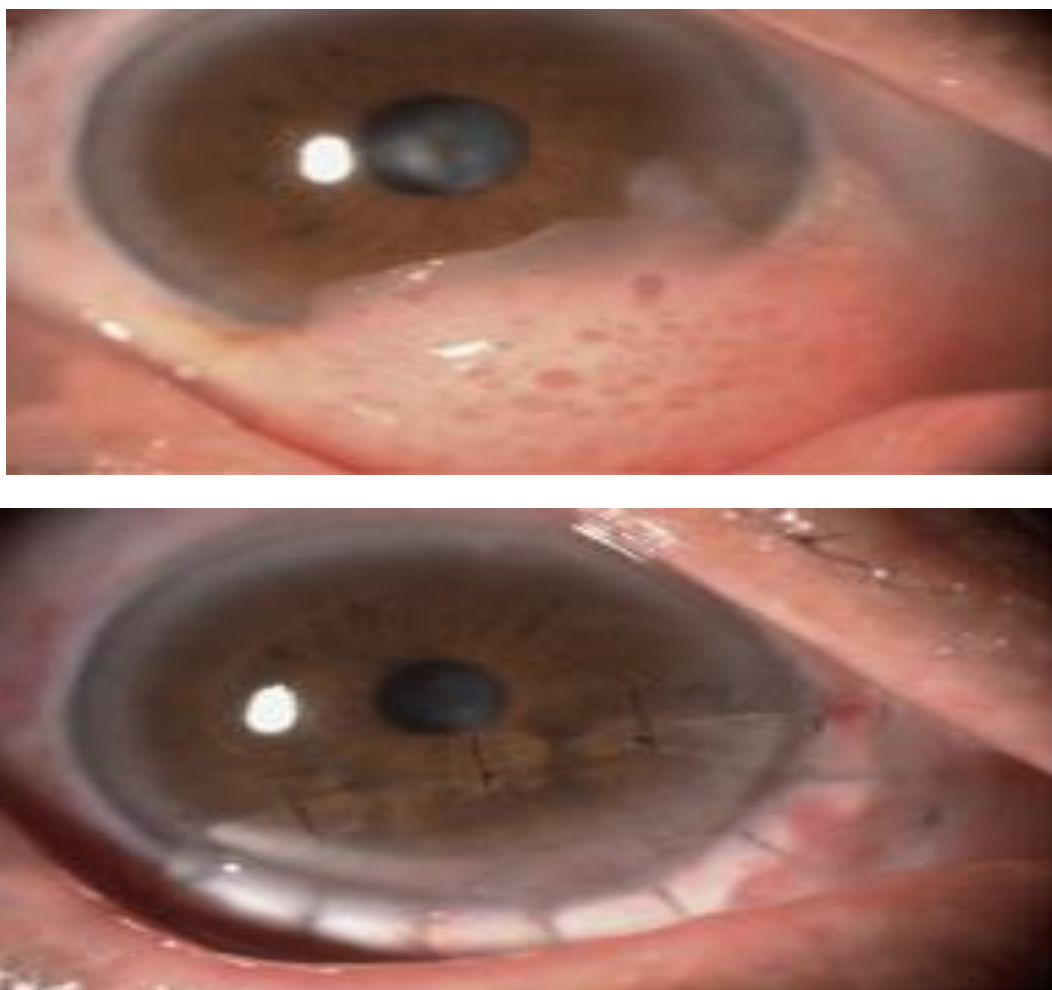
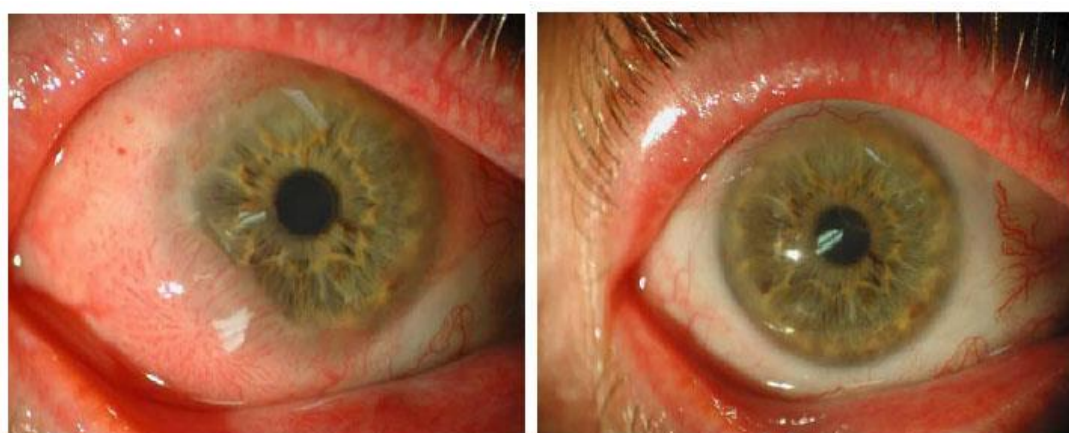

Fig. 12: Pre and Post-Operative pictures of papilliform OSSN (above and below)



Recurrent OSSN Pre-Treatment

Resolved OSSN after topical Interferon

Fig. 13

No touch technique is used wherein direct manipulation of the tumor is avoided to prevent tumor seeding. Frozen section can be used to assess the adequacy of excision, and is accurate in delineating horizontal tumor spread. Bunn's

modification of Moh's technique of tumor margin surveillance can be used. In this if residual tumor is evident even after excision of a 2 mm surgical margin the free conjunctival edge is excised for another 2 mm.³⁰ Enucleation and rarely

exenteration may be required in cases of intraocular or intraorbital spread. Mucoepidermoid carcinoma is particularly aggressive and most frequently requires enucleation or exenteration.³¹

Radiotherapy: Strontium-90 (beta irradiation) and radium (gamma radiation) were used earlier. But due to the high incidence of side effects and prolonged duration of treatment required, it is rarely used now. The surface dose used varies between 4500 rads given as 750 weekly fractions to 10,000-18,000 rads in daily fractions of 1000 rads. The limiting factor with radiotherapy is complications like cataract, secondary glaucoma, inflammation, dry eye and tissue necrosis.

Cryotherapy: Cryotherapy is often used along with surgery. It decreases the temperature and hence causes ischemic necrosis, leading to cell death. Intraoperative cryotherapy reduces the recurrence rate by destroying any residual tumour tissue beyond the surgical margin of excision.

Double freeze thaw technique: Nitrous oxide cryoprobe tip (2.5 or 5mm) is used to form an ice ball extending 2mm in the conjunctiva and 0.5mm in the cornea. Limbal region is included during cryotherapy, and should not exceed three seconds. Extensive surgical excision and cryotherapy can cause limbal stem cell loss. It may cause symblepharon, scleral melting and restricted ocular motility and these complications may be avoided by “reverse cryotherapy” where the probe is held under the conjunctiva, lifting it away from the sclera.

Chemotherapy: Topical chemotherapy decreases the risk of limbal stem cell deficiency, and removes the need for clear tumor margins as it treats the entire ocular surface, including the potentially dysplastic cells.³² The disadvantages are limited drug penetration in large tumors, and on longer use causes harmful effect on the ocular surface and nasopharyngeal epithelium.

1. **Mitomycin C (MMC):** An anti-tumor antibiotic that inhibits DNA synthesis in the G1 and S phases. Tumor tissues have an increased hypoxic environment which facilitates the intracellular reduction of MMC thereby giving a selective action of the drug. MMC causes cell death by apoptosis and necrosis.³³ It is used in the concentration of 0.02-0.04% four times a day in alternate

weeks in alternating cycles for a maximum of 8 weeks. The one week on, one week off regimen prevents damage to slowly dividing epithelial cells and limbal stem cells, allowing them to repair their DNA. Application of MMC is done after complete epithelial healing. This is done to avoid serious complications like corneal epitheliopathy, uveitis, glaucoma, cataract, scleral ulceration and melting.

2. **5-Fluorouracil- 5FU (1%):** An antimetabolite that acts during the S phase of the cell cycle, it's converted to 5-Fluoro dexoyuridine monophosphate, which inhibits thymidylate kinase thus preventing DNA and RNA synthesis. Both MMC and 5FU are being used four times a day for 1-2 weeks, the treatment being repeated after every 1-2 weeks. This pulsed treatment of one week on and one week off provides good efficacy and tolerance.

Immunotherapy: Interferon alpha2b (IFN- α 2b) is a natural glycoprotein that acts by binding to cell surface receptors resulting in anti-tumor and antiviral properties. It has been used in the treatment of many disorders like hepatitis³⁴, cervical intraepithelial neoplasia³⁵ and cutaneous squamous cell carcinoma.³⁶ Topical drops and subconjunctival injections of interferon- α 2b (IFN- α 2b) are used to treat OSSN. It has been used for extensive, residual, diffuse, multifocal lesions and lesions which affect vision. Interferon alfa2b is shown to be an important treatment for recalcitrant OSSN, effective in both, primary tumors not responding to treatment, as well as recurrences (Fig. 13). It is not used as a first line of therapy since it takes a longer time for complete resolution compared to MMC, and is more toxic than MMC. It is preserved for lesions non responsive to topical MMC. IFN-alpha 2b drops 1 million international unit/ml (IU/ ml) is used four times a day until resolution, and a month thereafter. The average time taken for resolution has been reported to be around 54 days (range 28-188 days), with a mean follow up of 3to 18 months.³⁷

Two doses of 1 and 3 million IU/ml are recommended. These doses were retrospectively compared for efficacy. The mean time taken for tumor resolution was about 12 weeks. At the end of the study the recommendation was to continue using the 1 million IU/ml dose in the treatment of CIN as before.³⁷

Pegylated Interferon Alpha 2b: Pegylation of therapeutic proteins is a proven method for prolonging duration of action and decreasing immunogenicity.³⁸ It modifies proteins like tumor necrosis factor- alpha (TNF- α) and human growth hormone.^{39,40,41} In some cases, the pegylated protein has been more effective than the native protein.³⁹ Pegylated interferon alpha 2b is a derivative of recombinant interferon alpha 2b. A single straight-chain polyethylene glycol (PEG; molecular weight of 12,000 Da), attached to interferon alpha significantly delays the renal clearance and increases plasma half-life tenfold compared to non-pegylated interferon.^{42,43} This allows dosing of pegylated interferon to be once in a week for systemic diseases in contrast to non-pegylated interferon (recombinant), which is given 3 times per week to daily. The safety of PEGIFN α 2b has been proven in patients with chronic hepatitis C, renal cell carcinoma, and chronic myelogenous leukemia (CML).⁴⁴ A recent study comparing the quality of life and toxicity of PEGIFN α 2b to non-pegylated interferon found less systemic side effects in the PEGIFN α 2b group.⁴⁵ However, the disadvantage of the PEGIFN α 2b over non- pegylated interferon is its increased price.

A study was conducted to evaluate the effectiveness and side-effect profile of this modality in OSSN.⁴⁶ It was seen that PEGIFN α 2b was effective in this pilot study for treating OSSN as complete resolution of the lesion was seen in all patients. A total of 3 injections were needed for tumor resolution in a case series using PEGIFN α 2b. In comparison, a previous case series using sub-conjunctival and topical recombinant interferon for the treatment of CIN reported that a mean of 5 injections were needed for tumor resolution.⁴⁷

Recurrence: Recurrence rates of OSSN range from 15-52%, average being 30%. Recurrences are higher in case of inadequate excision margins, occurring within two years of surgery. These usually exhibit more aggressive behavior due to the tissue disruption associated with the primary excision enhancing the ability of the tumor cells to enter the eye. The main predictors for recurrence include age, adequacy of margins at initial excision, histological grade of the lesion, corneal location, larger size (>2 mm), and a high proliferation index. Immunostaining with antibody to Ki-67, a nuclear antigen expressed in

proliferating cells, helps in evaluation of the growth fraction of normal and neoplastic cells giving the proliferation index.⁴⁸

Recommended Therapeutic Strategy and Current Therapeutic Practice:

Recent advances and current status of the diagnostic modalities and management of squamous neoplasms as reviewed by Basti et al⁴⁹ have made the following recommendations. Though the clinical diagnosis of in situ disease is high (86%), invasive carcinoma is seen less (35%). Large lesions and those with hyperkeratosis are more likely to be accurately diagnosed in a pre-op scenario. Impression cytology does not reliably differentiate in situ from minimally invasive disease, and hence has limitations in the accurate diagnosis of OSSN.

1. **Suspected OSSN 1-3 clock hours:** Complete excision biopsy recommended
 - If residual tumor is present in the margins, chemotherapy with MMC is given, 3 monthly review done to evaluate tumor resolution. Thereafter, follow up every six months
 - If tumor margins are free of tumor, 3 monthly follow up done for a year to confirm absence of recurrences; with a follow up of every six months.
2. **Suspected OSSN 3-6 clock hours:** Biopsy done to evaluate invasiveness of tumor
 - If pre-invasive: start chemotherapy with MMC
 - Follow up monthly, with quarterly evaluation for tumor resolution. If there is complete resolution then follow up every six months
 - If invasive: then start topical chemotherapy to achieve chemo reduction
 - Surgical excision of any residual tumor with cryotherapy to bed. Cover the exposed area with amniotic membrane graft
 - Follow up monthly with quarterly evaluation to confirm absence of recurrence of tumor. Thereafter, follow up every three months
3. **Suspected OSSN >6 clock hours:** Biopsy to decide if invasive or pre-invasive
 - If pre-invasive: start chemotherapy
 - Monthly follow up, with quarterly evaluation of tumor resolution. If there is complete resolution, follow up every six months
 - If invasive: give high dose chemotherapy with MMC
 - If there is complete resolution, follow up monthly for a year, and quarterly after that
 - If partial resolution and chemo-reduction is

achieved, then surgical excision of any residual tumor and cryotherapy to bed. Cover exposed area with amniotic membrane graft

- Follow up monthly, and evaluate every three months to confirm absence of tumor recurrence. Thereafter, follow up every three months
- If OSSN >6 clock hours after chemotherapy, give palliative treatment with radiotherapy
- In a survey of ophthalmologists treating OSSN, about 54% ophthalmic surgeons believe that sufficient evidence exists to justify use of Mitomycin C in treatment of OSSN, and 15% felt that the published literature justified the use of 5-fluorouracil or interferon. About 50% of ophthalmic surgeons always performed a biopsy before institution of topical therapy. The use of topical chemotherapy as an adjunct to surgical excision increased with the size of the lesion. Nearly 45% of the respondents utilized topical therapy along with surgery for lesions greater than 8mm in diameter.⁵⁰ Metastasis and local extension are managed by enucleation, exenteration, palliative radiotherapy, along with chemotherapy, parotidectomy and radical neck dissection.

Conclusion

Squamous lesions of cornea and conjunctiva are rare but they do demand appropriate attention as they can cause visual loss and systemic morbidity and mortality. Newer diagnostic modalities allow non-invasive evaluation which correlates well with histopathological tissue diagnosis. Further evolution of newer therapeutic options might allow cell specific anti-cancer treatment with preservation of the limbal stem cells and ocular surface.

References

1. Duke-Elder S, Leigh AG. Diseases of the outer eye. In: Duke-Elder S, ed. Systems of Ophthalmology, Vol 7, Part 2. St Louis: CV Mosby, 1985:1154–1159.
2. Nichols JV. Epithelial plaques of the conjunctiva and cornea. Arch Ophthalmol 1939;22:370–6.
3. McGavic JS. Intraepithelial epithelioma of the cornea and conjunctiva (Bowen's disease). Am J Ophthalmol 1942; 25:167–76.
4. Ash JE, Wilder HC. Epithelial tumors of the limbus. Am J Ophthalmol 1942;25:926–32.
5. Janert H. Zur peracancerose der cornea und conjunctiva. Von Graefes Arch Ophthalmol 1956;157:380–96.
6. Lugosy G. Precancerous conditions of the bulbar conjunctiva. Am J Ophthalmol 1956;42:112–25.
7. Winter FC, Kleh TR. Precancerous epithelioma of the limbus. Arch Ophthalmol 1960;64:208–15.
8. Irvine AR Jr. Dyskeratotic epibulbar tumors. Trans Am Ophthalmol Soc 1963;61:243–73.
9. Pizzarello LD, Jakobiec FA. Bowen's disease of the conjunctiva: a misomer. In: Jakobiec FA, ed. Ocular Adnexal Tumors, Birmingham, AL: Aesculapius, 1978:553–571.
10. Waring GO III, Roth AM, Ekins MB. Clinical and pathological description of 17 cases of corneal intraepithelial neoplasia. Am J Ophthalmol 1984;97:547–59.
11. Erie JC, Campbell RJ, Leisgang J. Conjunctival and corneal intraepithelial and invasive neoplasia. Ophthalmology 1986;93:176–83.
12. Lee GA, Hirst LW. Ocular surface squamous neoplasia. Surv Ophthalmol 1995;39:429–50.
13. Lee GA, Hirst LW: Incidence of ocular surface epithelial dysplasia in metropolitan Brisbane. A 10 year survey. Arch Ophthalmol 1992;110:525-7.
14. Yang J, Foster CS: Squamous Cell Carcinoma of Conjunctiva. Int Ophthalmol Clin 1997;73-84.
15. Sun EC, Fears TR, Goedert JJ. Epidemiology of squamous cell conjunctival cancer. Cancer Epidemiol Biomarkers Prev. 1997;6:73–77.
16. Mahomed A, Chetty R Human immunodeficiency virus infection, Bcl-2, p53 protein, and Ki-67 analysis in OSSN. Arch Ophthalmol 2002;120:554-8.
17. Sen S, Sharma A, Panda a Immunohistochemical localization of human papilloma virus in conjunctival neoplasias: a retrospective study. Indian J Ophthalmol 2007;55(5):361-3.
18. Nolan GR, Hirst LW, Bancroft BJ The cytomorphology of ocular surface squamous neoplasia by using impression cytology. Cancer 2001;25:93(1):60-5.
19. Tole DM, McKelvie PA, Daniell M. Reliability of impression cytology for the diagnosis of ocular surface squamous neoplasia employing the Biopore membrane. Br J Ophthalmol 2001;85(9):1115-9.
20. McKelvie PA, Daniell M. Impression cytology following mitomycin C therapy for ocular surface neoplasia. Br J Ophthalmol 2000;85:1115–19.
21. McKelvie PA, Daniell M, McNab A, Loughnan M, Santamaria JD. Squamous cell carcinoma of the conjunctiva: a series of 26 cases Br J Ophthalmol 2002;86(2):168-73.
22. Shousha MA, Perez VL, Wang J, et al. Use of ultra-high-resolution optical coherence tomography to detect in vivo characteristics of Descemet's membrane in Fuchs' dystrophy. Ophthalmology 2010;117:1220–7.
23. Wojtkowski M, Bajraszewski T, Gorczynska I, et al. Ophthalmic imaging by spectral optical coherence tomography. Am J Ophthalmol 2004;138:412–9.
24. Christopoulos V, Kagemann L, Wollstein G, et al. In vivo corneal high-speed, ultra high-resolution optical coherence tomography. Arch Ophthalmol 2007;125:1027–35.
25. Ultra high-resolution anterior segment optical coherence tomography in the evaluation of anterior corneal dystrophies and degenerations. Lejla M. Vajzovic, MD, Carol L. Karp, MD, Payman Haft, MD, et al. Ophthalmology 2011;118:1291–6.
26. Balestrazzi A, Martone G, Pichierrri P, Tosi GM, Caporossi A. Corneal invasion of ocular surface squamous neoplasia after clear corneal phacoemulsification: in vivo confocal microscopy analysis. J Cataract Refract Surg 2008;34(6):1038–43.
27. Gentile CM, Burchakchi AI, Oscar CJ. In vivo confocal microscopy study of ocular surface neoplasia manifesting after radial keratotomy and laser in situ keratomileusis.

- Cornea 2009;28(3):357–9.
28. The clinical value of in vivo confocal microscopy for diagnosis of ocular surface squamous neoplasia. Y Xu, Z Zhou, Y Xu, M Wang, F Liu, H Qu and J Hongl. *Eye* 2012;26:781–7.
 29. Shields JA, Shields CL, De Potter P. Surgical management of conjunctival tumors. *Arch Ophthalmol* 1997; 115:808-15.
 30. Buuns DR Tse. DT, Folberg R. Micro scopically controlled excision of conjunctival squamous cell carcinoma. *Am J Ophthalmol* 1994;117:97-102.
 31. Hwang IP, Jordan DR, Brownstein S, et al. Mucoepidermoid carcinoma of the conjunctiva. A series of 3 cases. *Ophthalmology* 2000;107:801-5.
 32. Chen C, Louis D, Dodd T, Muecke J Mitomycin C as an adjunct in the treatment of localized ocular surface squamous neoplasia. *Br J Ophthalmol* 2004;88(1):17-28.
 33. Sepulveda R, Pe'er J, Midena E, Seregard S, Dua H, Singh AD. Topical chemotherapy for ocular surface squamous neoplasia: current status. *Current Status. Br J Ophthalmol.* 2010;95(5):532-5.
 34. Pawlitsky JM. Interferon-based therapy of hepatitis C. *Adv Drug Deliv Rev* 2007;59:1222–41.
 35. Chakalova G, Ganchev G. Local administration of interferon-alpha in cases of cervical intraepithelial neoplasia associated with human papillomavirus infection. *J Buon* 2004;9:399–402.
 36. Edwards L, Berman B, Rapini RP, et al. Treatment of cutaneous squamous cell carcinomas by intralesional interferon alfa-2b therapy. *Arch Dermatol* 1992;128:1486–9.
 37. Topical Interferon Alpha 2b Eye-drops for Ocular Surface Squamous Neoplasia. A Galor; C L Karp; S Chhabra; S Barnes; E C Alfonso. *Br J Ophthalmol* 2010;94(5):551-4.
 38. Mehvar R. Modulation of the pharmacokinetics and pharmacodynamics of proteins by polyethylene glycol conjugation. *J Pharm Pharm Sci* 2000;3(1):125–36.
 39. Delgado C, Francis GE, Fisher D. The uses and properties of PEG-linked proteins. *Crit Rev Ther Drug Carrier Syst* 1992;9:249–304.
 40. Eliason JF. Pegylated cytokines: potential application in immunotherapy of cancer. *Bio Drugs* 2001;15(11):705–11.
 41. Bukowski RM, Tendler C, Cutler D, Rose E, Laughlin MM, Statkevich P. Treating cancer with PEG Intron: pharmacokinetic profile and dosing guidelines for an improved interferon-alpha-2b formulation. *Cancer* 2002;95(2):389–96.
 42. Glue P, Fang JW, Rouzier-Panis R, et al. Pegylated interferonalph2b: pharmacokinetics, pharmacodynamics, safety, and preliminary efficacy data. Hepatitis C Intervention Therapy Group. *Clin Pharmacol Ther* 2000;68(5):556–67.
 43. Wang YS, Youngster S, Grace M, Bausch J, Bordens R, Wyss DF. Structural and biological characterization of pegylated recombinant interferon alpha-2b and its therapeutic implications. *Adv Drug Deliv Rev* 2002;54(4):547–70.
 44. Talpaz M, O'Brien S, Rose E, et al. Phase 1 study of polyethylene glycol formulation of interferon alpha-2B (Schering 54031) in Philadelphia chromosome-positive chronic myelogenous leukemia. *Blood* 2001;98(6):1708–13.
 45. Sirohi B, Powles R, Lawrence D, et al. An open, randomized, controlled, phase II, single centre, two-period cross-over study to compare the quality of life and toxicity experienced on PEG interferon with interferon-alpha2b in patients with multiple myeloma maintained on a steady dose of interferon-alpha2b. *Ann Oncol* 2007;18(8):1388–94.
 46. Karp CL, Galor A, Lee Y, Yoo SH. Pegylated Interferon Alpha 2b for Treatment of Ocular Surface Squamous Neoplasia: A Pilot Study. *Ocular Immunology & Inflammation*, 2010;18(4):254–60.
 47. Vann RR, Karp CL. Perilesional and topical interferon alfa-2b for conjunctival and corneal neoplasia. *Ophthalmology* 1999;106(1):91–7.
 48. Mc Kelvie PA, Daniell M, Mc Nab A, Loughnan M, Santamaria JD. Squamous cell carcinoma of the conjunctiva: a series of 26 cases. *Br J Ophthalmol* 2002; 86(2):168-73.
 49. Ocular Surface Squamous Neoplasia, A Review. Surendra Basti, MD, and Marian S. Macsai, MD. *Cornea*; 2003;22(7):687-704.
 50. Stone DU, Butt AL, Chodosh J. Ocular Surface Squamous Neoplasia: A standard of care survey. *Cornea* 2005;24(3):297-300.