

# The Upper Eyelid Blepharoplasty: Perspective of an Ophthalmic Plastic Surgeon

Kasturi Bhattacharjee<sup>1,\*</sup>, Manpreet Singh<sup>2</sup>, Diva Kant Misra<sup>3</sup>

<sup>1</sup>Senior Consultant & HOD, Ophthalmic Plastic & Reconstructive Surgery, Sri Sankaradeva Nethralaya, Assam

**\*Corresponding Author:**

Email: kasturibhattacharjee44@hotmail.com

---

## Introduction

The human face is composed of small functional and cosmetic units of which eyes and periocular region constitutes the main point of focus in routine human face-to-face interactions. This dynamic region plays a pivotal role in the expression of human mood, emotion and character, thus providing it the critical importance. As the human face ages, first dynamic wrinkles start appearing in this region secondary to the thinner skin and negligible subcutaneous tissue followed by static wrinkles. This wrinkling along with herniation of orbital fat pad through the orbital septum leads to oculofacial imbalance and disharmony. Hence, the periocular region has got utmost cosmetic as well as functional value making both, the middle-aged and the elderly seek a consultation. Blepharoplasty is a surgical procedure performed over eyelids which provides satisfactory and relatively long-term results for these cosmetic and functional issues.

Way back in the 10<sup>th</sup> & 11<sup>th</sup> century, Arabian surgeons Ibn Rashid and Ibn Senna first described a condition of age related excessive skin folds in the upper lid and excised the skin to improve vision.<sup>[1]</sup> In 1818, Karl Ferdinand Von Graefe (father of Albrecht von Graefe, ophthalmologist) first coined the term blepharoplasty while reporting an eyelid reconstruction.<sup>[2]</sup> Since then, the blepharoplasty has evolved and has become the most commonly performed facial aesthetic surgery. Now-a-days, ophthalmic plastic surgeons or oculo-facial plastic surgeons are performing blepharoplasty in routine which earlier was mainly done by the general plastic surgeons. As the ophthalmologists are specifically trained surgeons for the periocular and orbital region, the depth of knowledge about anatomy and physiology (dynamicity) of surrounding tissues such as lacrimal pump and extraocular muscles, is advanced.

Descriptively, blepharoplasty is a surgical procedure in which the eyelid skin, orbicularis oculi

muscle and orbital fat are excised, redraped or sculpted for better cosmetic and functional results.<sup>[3,4]</sup> Generally, the upper eyelid blepharoplasty (UEB) is done for both cosmetic and functional indications while the lower eyelid blepharoplasty (LEB) is commonly performed for cosmetic purposes. In this article we are going to provide an overview of UEB for a general ophthalmologist and other specialists.

Why does a patient or an individual need UEB? A young or middle-aged patient mostly has a cosmetic reason (absent/ single eyelid crease). The elders specifically have more functional issues due to the loose and extra skin of upper eyelid, leading to loss of visual field and decrease in the quality of vision. The applied anatomy, indications of UEB, preoperative workup, procedure, postoperative care and complications would be briefly discussed in the following article.

## Applied Anatomy<sup>[3,4,6]</sup>

A thorough knowledge of eyelid, eyebrow and facial anatomy is a definite prerequisite for getting best possible surgical outcomes in UEB. The thickness of eyelid skin varies (0.3-1mm) with age, gender and race. It is thickest at just below the eyebrow and thinnest over pre-tarsal region.<sup>[5]</sup> After excision of the redundant eyelid skin, these thinnest and thickest cutaneous regions are approximated. The orbicularis oculi muscle is a vascular and dynamic structure which is attached firmly at arcus marginalis along with its ligamentary support at temporal and malar regions. A good familiarity with facial planes helps in proper identification of orbital fat pads, blood vessels, nerves and superficial musculo-aponeurotic system (SMAS). This helps in preventing a hematoma formation while injecting local anaesthetic agent and accurate tissue identification, intraoperatively.

With age, the epidermis thickens; the collagen and elastin of dermis disintegrate leading to the wrinkled and loose appearance of skin. Moreover,

the muscle and fat also undergoes age related hypotony and atrophy, respectively. Hence, the atrophy of orbital septum causes prolapse or herniation of orbital fat and the lacrimal gland through it. This accentuates the overall drop of facial soft tissues which happens under the effect of gravity. Intraoperatively, the retro-orbicularis oculi fat (ROOF) should be differentiated from pre-aponeurotic orbital fat pads for correctly repositing the former and resecting the latter.

The position of lateral canthus (1-2 mm superior to medial canthus), position of upper eyelid crease (6-7mm males, 7-8mm females), symmetry of tarsal show, eyelid fold (single or double) and relation between eyebrow & eyelid crease position in various gazes (most important in downgaze) should be addressed with full attention during a UEB. For this, a distance between inferior margin of eyebrow and the eyelid crease should be minimum 20mm or 2/3<sup>rd</sup> of its total distance between eyebrow and eyelid margin. This reduces the chances of postoperative lagophthalmos and inferior brow pull/ ptosis.

The prolapsed lacrimal gland which is a firm, pink-grey and a glandular structure should be aptly differentiated from the orbital fat for preventing a dry eye syndrome in recovery period. The pre-aponeurotic orbital fat pads should be removed or sculpted cautiously to prevent a deep superior sulcus deformity which gives a cadaveric look to the patient. Hence, in younger individuals, the fat excision could be planned but is better avoided in elderly. The levator aponeurosis, Whitnall's ligament and peripheral vascular arcade should be properly identified and intraoperative trauma is avoided which might lead to the untoward effects like blepharoptosis and hematoma formation.

### Indications of UEB<sup>[6,7]</sup>

The younger patients opt for UEB mainly for cosmetic reasons while the middle-aged and elderly have both cosmetic as well as functional concerns. Young individuals, especially the Asian and North-East Indians with oriental features, commonly demands for creating an eyelid crease, modifying the eyelid crease or achieving symmetrical or higher creases. A specific complaint of female patients could be 'not able to apply eyelid makeup', demanding UEB. The elderly patients often have chief complaints of hooding of extra eyelid skin, restriction of visual field, decrease in the quality of vision, excessive skin wrinkling and folds, excessive strain and headaches due to prolonged

voluntary lifting of upper eyelids. Moreover, these aging changes give a 'tired look' to the patient. Few patients might have irritation and watering (rubbing of misdirected eyelashes). Rarely, UEB is performed for excising large xanthelasma, removing a tumor or mass, correcting a traumatic or developmental eyelid anomaly.

### Pre-operative Workup

A proper history of any trauma or previous surgery should be recorded. The goals of surgery, expectations of the patient and possible complications should be discussed in detail in preoperative period. Patients with history of dry eye, thyroid orbitopathy, facial nerve palsy and contact lens wearers might develop xerotic keratopathy in postoperative period. History of bleeding disorder, use of Aspirin or NSAID's, vitamin E supplements and excessive use of ginger and garlic should be specifically noted and adequately avoided.

Meticulous clinical examination of best corrected visual acuity, palpaebal fissure height and contour, upper eyelid position, eyelid crease and eyelid fold distance, eyebrow position (very critical), frontalis action and tear film health (Tear Meniscus Height, Tear break up time, Schirmer's test) should be meticulously performed to circumvent postoperative surprises. The eyebrow and eyelid margin distance should be measured in lateral, middle and medial portions. Any asymmetry should be reported to the patient and is taken care during surgery. Preoperative high resolution photographs are must in primary and oblique gazes. The photography is ideally performed by the same person in pre and postoperative period in similar settings. The use of flash is generally avoided while a light diffuser is handy. Elaborated written and informed consent of the patient should be obtained before the surgery day to avoid any kind of preoperative dilemmas and anxiety. The usage of Botulinum toxin in perioperative period is not encouraged as the postoperative edema and inflammation may lead to the diffusion of drug, hence reducing its desired effects. If botulinum toxin is a necessity, it should be administered at least 2-3weeks prior to the surgery.

### Surgical Technique<sup>[8,9,10,11]</sup>

The foremost important thing in an UEB is to mark the patient's eyelids in sitting position (straight gaze & down gaze) before injecting the

local anaesthesia which balloons the loose eyelid skin. For eyelid marking, the patient should be asked for the desired position of eyelid crease. Most of these surgeries are performed under local anaesthesia for better intraoperative assessment and achieving symmetry. The levator muscle infiltration by local anaesthetic agent is avoided as its action is required intraoperatively. The hematoma is avoided with careful injection technique (30 gauge needle) avoiding prominent vascular arcades. Preoperative application of ice packs can be handy to reduce local vascularity.

There have been many reported techniques of skin marking (shapes/ extent), skin excision (blade/ radiofrequency (RF), orbicularis oculi muscle (preservation/ excision), orbital fat (excision/ sculpting/ repositioning) and wound closure (suture types).

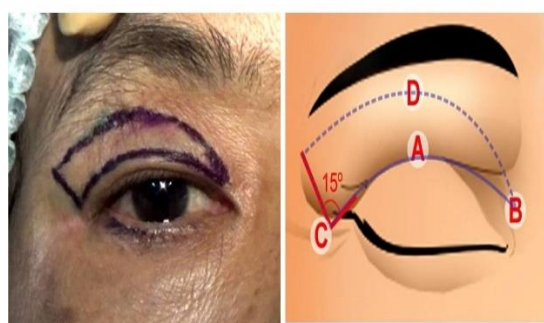
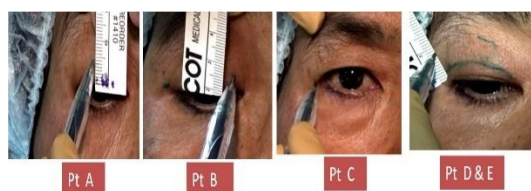The authors prefer their own style of skin marking to encounter the lateral hooding aggravating the dermatochalasis. Preoperative marking is done under adequate lighting conditions while the patient is seated in a comfortable position looking in the primary gaze. Point A is marked 10 mm above the central lid margin. Point B is marked at 6mm above the medial canthus. Point C is marked at the lowest point of the lateral hooding. Then pinch test is done and point D is marked. Point E is marked 8 mm above and at an angle of 15 degrees from point C. All the points are joined in an ellipsoid fashion to complete the lid marking.(Fig. 1) Other classical lid marking techniques are shown in Fig. 2.

The coexisting conditions like eyebrow ptosis, fat herniation, blepharoptosis and epicanthus can be taken care during UEB. Most commonly north-east Indian patients present to our clinic to get an eyelid crease (cosmetic), getting rid of single-eyelid crease, for encountering generalised eyelash ptosis and for dermatochalasis with or without lateral hooding.


After fashioning the skin incisions(Fig. 3a), one edge of the wound is lifted and skin is excised with RF cautery (author preference) using a fine angled empire tip(Fig. 3b). A strip of preseptal orbicularis is excised(Fig. 3c) and small incisions over septum provide direct access to pre-aponeurotic fat pads(Fig. 3d). The medial (whitish) and central (yellow) fat pads can be differentiated by the colour (embryonic origin, medial- neural crest derived) and are teased out gently through the small openings of orbital septum(Fig. 3e-g). The authors prefer securing the removable fat pads with a

hemostatic clamp before excising those using a RF cautery. The remaining stump in the hemostatic clamp is cauterised before aiding its retraction back into the orbit. These conservative steps are observed to prevent an orbital hemorrhage. The authors do not prefer to close the orbital septum openings.

In same sitting, the ROOF is repositioned back for restoring the eyebrow volume along with its internal fixation at desired position i.e. 2-3 mm above the supraorbital rim, with two non-absorbable sutures. The orbicularis muscle is closed with interrupted 6-0 absorbable sutures. A trademark suture 'K-suture' (5-7, interrupted, horizontal mattress) is applied taking the pretarsal skin, orbicularis oculi muscle, LPS fibres and skin, to create a prominent and desired eyelid crease(Fig. 3h). The skin is then approximated with continuous or interrupted, preferably non-absorbable sutures(8-0 prolene)(Fig. 3i). One may encounter 'dog ears' at the temporal ends and the Burrow's triangle can be a good option for closing keeping the curve superiorly concave. The scar should not extend beyond the line joining lateral canthus and temporal end of eyebrow to avoid its visibility in primary gaze. Antibiotic ointment is applied with sterile dressing. The authors strongly recommend the use of small ice packs (preferably sterile) over the dressing to reduce the edema, enhance patient comfort and providing tamponade. The head end of the patient is raised and bilateral eye patching is recommended for 4-6 hours followed by patients' choice for its removal.

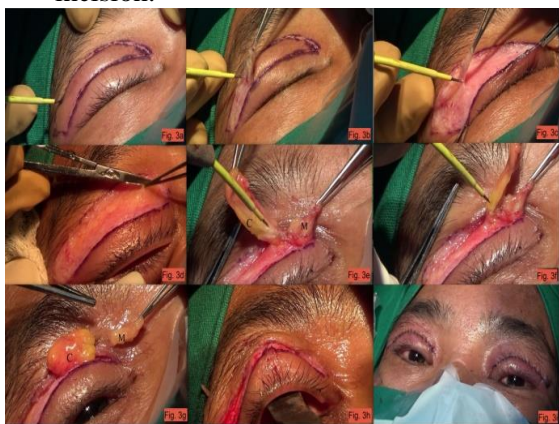

**Fig. 1: Authors technique of eyelid markings for UEB**



**Fig. 2: Schematic diagram showing different upper eyelid markings for UEB**

- (i) (Yellow) Classic Rees incision (more chances of temporal brow droop)
  - (ii) (Red) Scalpel shaped incision (negates the extra brow droop)
  - (iii) (Blue) Bellinvia's incision (beyond temporal brow margin) for counteracting lateral hooding
- The distance between eyelid margin and lower border of incision (A) allows more upper eyelid skin excision in classic Rees incision. Hence, some additional thinner eyelid skin (B) is preserved in scalpel shaped incision.



**Fig. 3: Surgical Steps**

#### Postoperative advice

1. Do not lift heavy weights (1-2 weeks)
2. Avoid blood thinners and anti-coagulants for 1 week
3. Avoid direct sunlight exposure and use sunscreens to avoid scar pigmentation and scar irregularities

4. Intermittent use of ice packs (3-4 times/day) and head end elevation while sleeping (to reduce/ minimise the edema)
5. Generous use of ocular lubricating drops for preventing exposure related corneal dryness
6. Avoid applying eye make-up for minimum of 10-14 days

#### Complications<sup>[12,13]</sup>

1. **Superficial hematoma/ ecchymosis:** Subcutaneous or intramuscular hematoma can occur preoperatively while injecting local anaesthesia, intraoperatively from bleeding orbicularis oculi muscle and in early postoperative period from fragile blood vessels. This can be minimised by accurate injection techniques (try to be just underneath the skin with 30 gauge needle), adequate control of hypertension and avoiding the blood thinners. Use of RF cautery has reduced the intraoperative muscular/ fat bleeding episodes. The preseptal hematomas do not have any effect on visual acuity but cause an unpleasant 'panda eye appearance' and delay the overall recovery. Though, the latest randomised controlled trial concluded no role of eyelid cooling in reducing pain, edema, erythema and hematoma, we still believe that it might have some beneficial effect in few patients.<sup>[14]</sup>
2. **Asymmetry:** One aim of UEB is to achieve symmetry between two eyelids. A fine asymmetric scar especially in medial and lateral region may occur while encountering a dog-ear. Hence, an appropriate symmetry should be maintained right from fashioning the skin incisions upto wound closure. The medial webbing of scar could be managed with V-Y plasty while the lateral scar asymmetry is mainly preventable. Directional digital massage and vitamin creams may help a few in early postoperative period.
3. **Lagophthalmos:** In early postoperative period, the lagophthalmos can occur due to longer anaesthetic affect or hematoma/ trauma to orbicularis oculi muscle. In late stages, the excessive excision of skin + muscle may shorten the anterior lamella causing a cicatricial type of lagophthalmos. A severe tethered variety of lagophthalmos can result, if the muscle accidentally gets sutured to the immobile orbital septum. This is easily

recognised clinically by mechanically pulling the eyelid downward, a firm resistance is felt. In this case, the release of muscle from the orbital septum is essential.

4. **Blepharoptosis:** Generally, this situation arises as a surprise due to inappropriate preoperative eyelid examination in which a coexisting blepharoptosis was missed. The blepharoptosis becomes prominent once the dermatochalasis resolves after UEB. Rarely, an intraoperative injury to the levator aponeurosis might lead to the eyelid droop. In both situations, a levator surgery is required which can be performed via the same incision site.
5. **Scar related issues:** Scar hypertrophy, pigmentation and persistent scar erythema are few of the important problems of wound modulation and healing. Directional digital massage, local vitamin E cream, steroid creams and subcutaneous injections of anti-fibrotic agents are helpful in few situations. Silicone based gels are safe and effective scar management option. Occasionally, few epithelial inclusion cysts are encountered which require excision or marsupialisation. Use of larger sunglasses and sunscreens is advised for protecting the surgical area from direct sunlight exposure. Any wound gape or infection is attended on urgent basis. For two weeks, local antibiotic skin ointment is advised to all patients.
6. **Dry eye syndrome:** This is a common entity in early postoperative period of UEB. The corneal dryness should be carefully managed with the help of sufficient lubricating eyedrops (daytime) and gels (at bedtime). This prevents the dry eye caused by relative lagophthalmos (evaporative dryness). Any specific complaint of pain, foreign-body sensation, redness and excessive watering warrants a careful corneal and tear film evaluation. Ointments, gels and night patches relieve the symptoms and signs in most of these patients.
7. **Orbital hematoma/ compartment syndrome:** This is a postoperative emergency in all UEB patients. This mainly happens in the immediate post-operative period as the patient complains of a sudden-onset, severe pain along with profound vision loss. Due to the retraction of a bleeding blood vessel back into the orbit (mostly orbital fat vessels), the active hemorrhage is not recognised on-table and the surgeon closes the wound routinely. In postoperative period, the hematoma grows in size and cause raised intraorbital pressure hence causing ischemic damage to the optic nerve. A congested and proptosed globe with reduced ocular movements along with a dilated pupil gives us the clinical clues for this situation. It is essential to manage it in emergency, the wound is opened up, the bleeder is located and a hemostasis is achieved. Immediate lateral canthotomy and cantholysis is performed if the pupil is dilated. Systemic steroids and osmotic agents are used as adjunctive therapies. To avoid this emergency situation, the authors prefer using hemostatic clamps to hold orbital fat, excision with RF cautery and bipolar cautery for stump ablation before releasing the orbital fat stump.
8. **Lymphedema:** A chronic variety of upper eyelid edema may ensue in the postoperative period which is more in the morning and reduces as the day progresses. This happens as many of the lymphatics get severed while giving incision over the eyelid, similarly as happens in levator aponeurosis surgeries. This edema resolves as these lymphatics gets their function back slowly. These unavoidable situations should be explained to the patient clearly in preoperative period.
9. **Ocular motility disorders:** Though a rare complication of UEB, the deeper diffusion or extravasation of the anaesthetic agent can lead to this transient effect. This might be a commoner problem in lower eyelid blepharoplasty in which the inferior oblique muscle might be injured during fat handling.

In conclusion, the UEB which is the most common aesthetic surgery performed in the USA, is a challenging procedure both in terms of surgery and patient satisfaction. The importance of 'first listening and understanding the patient's expectations' is more significant in the context of blepharoplasty than the other surgeries. Careful examination for the coexisting eyelid and ocular surface abnormalities should be conducted. The position, symmetry and contour of the eyebrow play a considerable role in the final appearance of periorbital region. Overall, the patient must be informed about our final goal of achieving a balance of the facial appearance with the age of an

individual. The more time spent in preoperative period with the patient, reduces our postoperative time spent in explaining the untold.

## References

1. Dupuis C, Rees TD. Historical notes on blepharoplasty. *Plast Reconstr Surg* 1971;47(3):246– 51.
2. Von Graefe CF. *De Rhinoplastice*. Berlin: Dietrich Reimer, 1818;13.
3. McCord CD. Upper blepharoplasty and eyebrow surgery. In: Chen WP, ed. *Oculoplastic Surgery*. New York, NY: Thieme; 2001:125-45.
4. Rees TD. Blepharoplasty. In: Rees TD, Wood smith D, eds. *Cosmetic Facial Surgery*. Philadelphia, PA: Saunders; 1973:44-133.
5. Hwang K, Kim DJ, Kim SK. Does the upper eyelid skin become thinner with age? *J Craniofac Surg* 2006;17:474-6.
6. Leather barrow B. Blepharoplasty. In: Leather barrow B, ed. *Oculoplastic Surgery*. London, UK: Informa Healthcare 2011;310-45.
7. Pepper JP, Moyer JS. Upper blepharoplasty: the aesthetic ideal. *Clin Plast Surg* 2013;40:133-8.
8. Hsu AK, Jen A. Estimation of skin removal in aging Asian blepharoplasty. *Laryngoscope* 2012;122:762-6.
9. Lee JW, Baker SR. Esthetic enhancements in upper blepharoplasty. *Clin Plast Surg* 2013;40:139-46.
10. Har-Shai Y, Hirshowitz B. Extended upper blepharoplasty for lateral hooding of the upper eyelid using a scalpel blade excision: a 13-year experience. *Plast Reconstr Surg*. 2004;113:1028-35.
11. Bellinvia G, Klinger F, Maione L, Bellinvia P. Upper lid blepharoplasty, eyebrow ptosis, and lateral hooding. *Aesthet Surg J*. 2013;33:24-30.
12. Whipple KM, Lim LH, Korn BS, et al. Blepharoplasty complications: prevention and management. *Clin Plast Surg* 2013;40:213-24.
13. Morax S, Touitou V. Complications of blepharoplasty. *Orbit* 2006;25:303-18.
14. Pool SM, van Exsel DC, Melenhorst WB, Cromheecke M, van der Lei B. The effect of eyelid cooling on pain, edema, erythema, and hematoma after upper blepharoplasty: a randomized, controlled, observer-blinded evaluation study. *Plast Reconstr Surg*. 2015;135:277-81.