

Content available at: <https://www.ipinnovative.com/open-access-journals>

IP International Journal of Ocular Oncology and Oculoplasty

Journal homepage: <https://ijooo.org/>

Guest Editorial

Contracted socket and lower fornix reconstruction: An oculoplastic challenge

Syed Mehubub Ul Kadir ^{1,2,*}

¹Dept. of Orbit, Ophthalmic Oncology and Ophthalmic Plastic Services, Bangladesh Eye Hospital and Institute, Dhaka, Bangladesh

²Dept. of Orbit, Ophthalmic Oncology and Ophthalmic Plastic Services, Sheikh Fazilatunnesa Mujib Eye Hospital and Institute (SFMEHTI), Gopalganj, Bangladesh



ARTICLE INFO

Article history:

Received 15-06-2022

Accepted 28-06-2022

Available online 27-07-2022

This is an Open Access (OA) journal, and articles are distributed under the terms of the [Creative Commons Attribution-NonCommercial-ShareAlike 4.0 License](https://creativecommons.org/licenses/by-nc-sa/4.0/), which allows others to remix, tweak, and build upon the work non-commercially, as long as appropriate credit is given and the new creations are licensed under the identical terms.

For reprints contact: reprint@ipinnovative.com

A contracted socket is a clinical condition of an anophthalmic socket that cannot retain an ocular prosthesis. It causes significant aesthetic problems for the patient and causes a profound physical, social, and psychological impact on a patient. It is always challenging to make the fornices for an ophthalmic plastic surgeon. The contracted socket may occur after a year of enucleation or evisceration. Post Enucleation Socket Syndrome (PESS) is characterized by a deep upper eyelid sulcus, lower eyelid laxity, eyelid deformity without shrinkage or shortening of the soft tissues, and the clinical manifestations scenarios is different from the contracted socket.^{1,2}

The goal of the correction of the contracted socket is to make a space to provide an appropriate size of ocular prosthesis that would simulate the normal fellow eye of the patient in all respects. The two most important aspects are always considered for making a sufficient fornix to support the ocular prosthesis and make the adequate orbital volume.³

There are multiple risk factors for developing a contracted socket, including failure to wear a prosthetic for a long time, infection in the ocular surface or orbital infection, post-radiation, excessive tissue damage due to trauma, extreme tissue manipulation or excessive excision

of conjunctiva during enucleation or evisceration, and autoimmune diseases like mucous membrane pemphigoid, Stevens-Johnson-Syndrome.⁴⁻⁶

There are various classifications for the contracted socket. The soft tissue sockets have recently been divided into five grades to adopt an appropriate surgical plan.⁷

Grade 0	A healthy socket is lined with conjunctiva and has deep and well-formed fornices.
Grade 1	Shallowing or shelving of the lower fornix.
Grade 2	Loss of both upper and lower fornices
Grade 3	Loss of all fornices
Grade 4	Loss of all the fornices with a vertically and horizontally narrow palpebral aperture
Grade 5	Recurrence of the contracted socket

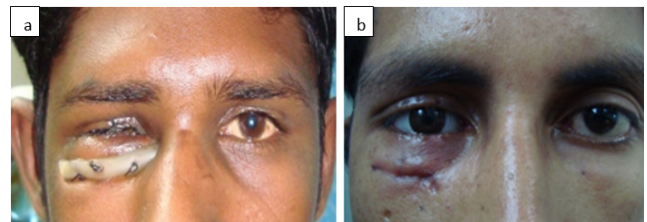


Fig. 1: a: Reconstructed right lower fornix with external fixation (bolster), **b:** Ugly skin scar after removing the external bolster.

* Corresponding author.

E-mail address: mehbubkadir@gmail.com (S. M. U. Kadir).

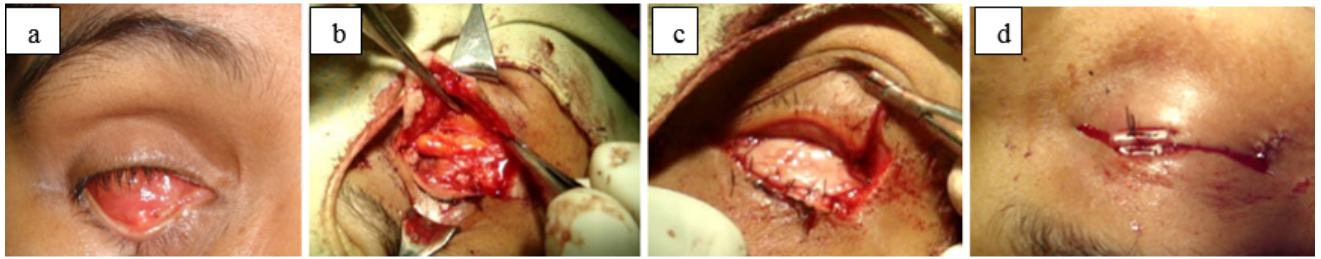


Fig. 2: a-d: Grade II Contracted Socket, deepening of lower fornix with internal fixation to the periosteum, MMG with fornix retraction, more insufficient lid recognition with tarsorrhaphy.

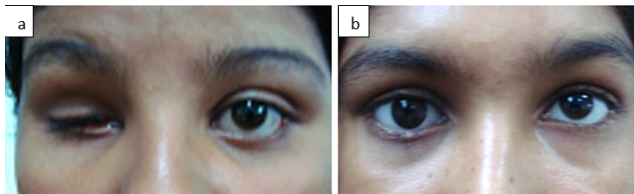


Fig. 3: a,b: Grade III Contracted Socket (Right), Ocular prosthesis after Fornix reconstruction with Internal fixation (Right)

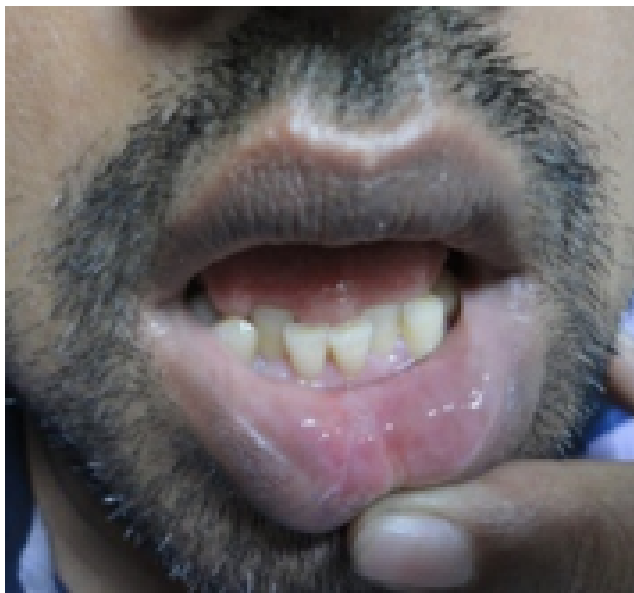

Fig. 4: Epithelization after three weeks of harvesting mucous membrane from the lower lip.

Contracted sockets are always challenging to manage, and different surgeons adopt different techniques. The reconstruction of the socket depends on various conditions of the socket. There are multiple procedures available for socket reconstruction. The surgical decision is based on the grade of socket contraction and other associated ophthalmic conditions. The surgery may be single, combined, and multiple staged surgeries. The available surgical options are lateral tarsal strip (LTS) for eyelid laxity, Dermis fat graft (DFG) or secondary orbital implant for orbital

volume augmentation; Mucous membrane graft (MMG) or Amniotic membrane graft (AMG) is used to enlarge the surface area, fornix deepening sutures for the reconstruction of fornix and fat graft in the sup. Sulcus to reform the upper fornix.⁸⁻¹⁰ Forniciometre is helpful to measure the contralateral depths of fornices before fornix reconstruction. The depth of the inferior fornix is of greater importance because it bears most of the weight and must be deep enough to give firm anchorage for the prosthesis. The usual depths of fornices, superior fornix is approximately 14 mm, inferior fornix is 9-10 mm, lateral fornix is 5 mm. The medial fornix is three mm.¹¹ A few general rules apply for the socket reconstruction like as preserve presenting conjunctiva and adding a conjunctival lining by MMG or AMG, if necessary.

Remember, the mucosal grafts need to be 25% more to shrinkage. Avoid 'mixed' sockets consisting of mucous membrane and skin because they will develop into 'smelly sockets'; always put optimum size and shape of conformer/prosthesis in the socket at the end of the surgery. Full-thickness MMG is preferred because it allows the grafted tissue to match conjunctiva histologically. The donor sites are the lower lip, upper lip, and buccal mucosa. The lower lip is preferred because the access is easier, and suturing is not required as the vascular mucosa heals fast, which epithelializes spontaneously over 2 to 3 weeks. The buccal mucosa yields more graft material while normally must be sutured. It is important to avoid damage to the parotid duct, whose opening is opposite the upper second molar tooth. Lower fornix can be reconstructed by fornix deepening sutures with/without MMG or AMG.^{2,5,6,12-14} The popular technique of Lower fornix reconstruction by fornix deepening sutures with external bolster. The advantage of fornix deepening sutures with external bolster is an easy procedure and less learning curve but disadvantages like Blind procedure, the Recurrence rate is high, and causes ugly scar mark on the skin, and skin infection. New Approaches to lower fornix reconstruction are fornix deepening sutures without external bolster or internal fixation to the periosteum, and another technique is fornix reconstruction with harvesting fascia lata strip.^{3-5,15}

In our case series, the recurrence was 8% in the 351 cases of lower fornix reconstruction with external bolster.

The reproduction was only 3% in the 119 instances lower fornix reconstruction with internal fixation. The fornix reconstruction with internal fixation is the preferred option in the South Asia region. Triamcinolone acetonide can be injected into the socket to prevent fibrosis and recurrence. The surgical outcome depends on the grade of the contracted socket and associated ocular conditions. The higher degree of the contracted socket is associated with a poorer prognosis.¹⁶ The management of a contracted socket is an arduous task. Cosmetic outcome is often unsatisfactory. Recurrence is common in young individuals and has a higher degree of contraction.

Acknowledgment

None.

Source of Funding

None.

Conflict of Interest

None.

References

1. Tadros MA. Surgical psycho-ophthalmology and contracted sockets. *Adv Ophthalmic Plast Reconstr Surg*. 1990;8:274–9.
2. Tyers AG, Collin JR. Orbital implants and post enucleation socket syndrome. *Trans Ophthalmol Soc U K (1962)*. 1982;102(1):90–2.
3. Grover AK, Sawhney A, Bageja S. Surgical Management of the Contracted Socket. In: Cohen A, Burkat C, editors. *Oculofacial, Orbital, and Lacrimal Surgery*. Springer, Cham; 2019. doi:10.1007/978-3-030-14092-2_63.
4. Vistnes LM, Iverson RE. Surgical treatment of the contracted socket. *Plast Reconstr Surg*. 1974;53(3):563–7. doi:10.1097/00006534-197405000-00013.
5. Ragge NK, Subak-Sharpe ID, Collin J. A practical guide to the management of anophthalmia and microphthalmia. *Eye (Lond)*. 2007;21(10):1290–300. doi:10.1038/sj.eye.6702858.
6. Tawfik HA, Raslan AO, Talib N. Surgical management of acquired socket contracture. *Curr Opin Ophthalmol*. 2009;20(5):406–11. doi:10.1097/ICU.0b013e32832ed85b.
7. Krishna G. Contracted sockets (aetiology and types). *Indian J Ophthalmol*. 1980;28(3):117–20.
8. Bhattacharjee K, Bhattacharjee H, Kuri G, Das JK, Dey D. Comparative analysis of use of porous orbital implant with mucus membrane graft and dermis fat graft as a primary procedure in reconstruction of severely contracted socket. *Indian J Ophthalmol*. 2014;62(2):145–53.
9. Choi CJ, Tran AQ, Tse DT. Hard palate-dermis fat composite graft for reconstruction of contracted anophthalmic socket. *Orbit*. 2019;38(3):199–204. doi:10.1080/01676830.2018.1505920.
10. Starks V, Freitag SK. Postoperative Complications of Dermis-Fat Autografts in the Anophthalmic Socket. *Semin Ophthalmol*. 2018;33(1):112–5.
11. Kawakita T, Kawashima M, Murat D, Tsubota K, Shimazaki J. Measurement of fornix depth and area: a novel method of determining the severity of fornix shortening. *Eye (Lond)*. 2009;23(5):1115–9. doi:10.1038/eye.2008.205.
12. Kumar S, Sugandhi P, Arora R, Pandey PK. Amniotic membrane transplantation versus mucous membrane grafting in anophthalmic contracted socket. *Orbit*. 2006;25(3):195–203.
13. Bajaj MS, Pushker N, Singh KK, Chandra M, Chose S. Evaluation of amniotic membrane grafting in the reconstruction of contracted socket. *Ophthalmic Plast Reconstr Surg*. 2006;22(2):116–20.
14. Pooyathalang A, Preechawat P, Pomsathit J, Mahaisaviriya P. Reconstruction of contracted eye socket with amniotic membrane graft. *Ophthalmic Plast Reconstr Surg*. 2005;21(5):359–62.
15. Ibrahim MFK, Abdelaziz S. Shallow Inferior Conjunctival Fornix in Contracted Socket and Anophthalmic Socket Syndrome: A novel technique to Deepen the Fornix using Fascia Lata Strips. *J Ophthalmol*. 2016;doi:10.1155/2016/3857579.
16. Soares IP, França VP. Evisceration and enucleation. *Semin Ophthalmol*. 2010;25(3):94–7.

Author biography



Syeed Mehub Ul Kadir, Assistant Professor & Consultant  <https://orcid.org/0000-0002-2077-6784>

Cite this article: Kadir SMU. Contracted socket and lower fornix reconstruction: An oculoplastic challenge. *IP Int J Ocul Oncol Oculoplasty* 2022;8(2):88–90.