

Fish Bones in the Orbit: A Case Report

Puneet Johri^{1,*}, Aparna Johri²

¹Consultant Paediatric Ophthalmology and Strabismus, Sankara Eye Foundation, Sankara Eye Hospital, Kanpur,

²Sr. Medical Superintendent, HAL –TAD, Kanpur

***Corresponding Author:**

Email: puneetjohri@yahoo.com

Abstract

It is rare to find fish bones retained in the orbital region. We report here an interesting case of an ocular fish bite injury in a sea diver. We also discuss few peculiar characteristics of a fish species responsible for the same and its probable mechanism of injury.

Keywords: *Fish bones, Half-beak fishes, Coral reef, Sea-diving.*

Introduction

Several authors have reported different kinds of foreign bodies in the orbit. There have been reports of wooden pieces^{1,3}, a pencil stub⁴, a glass piece² and even a metallic object⁷ in the orbital region. The foreign bodies may be retained in the orbit for a variable period and manifest itself later in several ways. They may be overlooked, if the penetrating wound is small and accompanied by minimal or no signs of inflammation⁷. We report here a case of an ocular fish bite injury in a 44 yr old sea diver, where the superficial lid injury was too small and simple to be suspected of harboring the ‘fish bones’, which later manifested as a peanut sized nodule at the same site.

Case Report

A 44yr old male, was seen in the eye out patient department of our hospital, 4 days following a fish bite injury on his right eye, while diving near a shallow reef. He experienced a burning sensation soon after this episode. He also noted a cut wound on the lower lid of the right eye. There was no history of any sight problem or any history suggestive of diplopia. He consulted a local general practitioner, who referred him here for further eye checkup.

On examination, the unaided vision was 6/12 in right eye and 6/6p in left eye. The best corrected vision was 6/6 in both eyes. A 2mm x 3mm skin laceration was noted lying 4 mm below the lid margin at the junction of lateral 1/3rd and medial 2/3rd of right lower lid. The rest of the lid margin and lashes were intact. There was no evidence of any perforating wound in the eyeball. The anterior

and the posterior segments of both the eyes were normal. The eyes were symmetrically aligned and had no limitations of ocular movements.

The patient was treated conservatively, with a course of oral broad spectrum antibiotic along with anti-inflammatory tablets.

The patient presented to us again, 4 months later, on noticing a small peanut nodule at the same injured site on the right lower lid. It was a well defined, firm to hard, non tender, pea-sized nodule at the site of previous laceration. The overlying skin had no scars of previous injury. It could well be pinched off the underlying nodule. It had a restricted mobility and appeared arising from the deeper structures of posterior lamella. It was provisionally diagnosed as a case of calcified foreign body granuloma. But, the PNS x ray did not reveal any corresponding radiopaque shadow (Fig. c).

With the strong suspicion of a radiolucent foreign body impacted at the same site, arising from the structures of posterior lamella, an exploration and excision of the nodule was planned under local infiltration.

The surgical incision was made as seen in the Fig. a. The nodule was carefully dissected from its surrounding structures taking care not to distort the anatomy. The detailed exploration of the site revealed it to be a ‘foreign body structure’ projecting in front of the tarsus and not lying or arising from the posterior lamella, as thought earlier. Further dissection revealed it to be a ‘collective bunch of fish bones’, as shown in the Fig. b, stacked together, found lying antero-posteriorly in the inferior orbital space. There were five such bones measuring 2-3 mm in thickness

and 10-15 mm in length. They were firmly bound together and each had to be pulled out with a mosquito artery forcep. The area was washed with copious saline water and sutured in layers after attaining hemostasis. The wound healed well with minimal scarring.

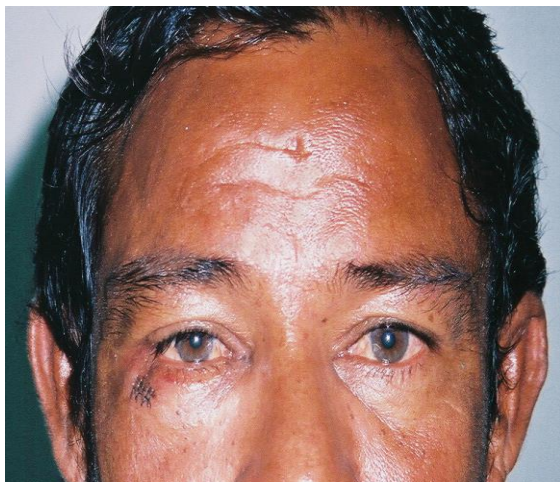

Fig. a



Fig. b

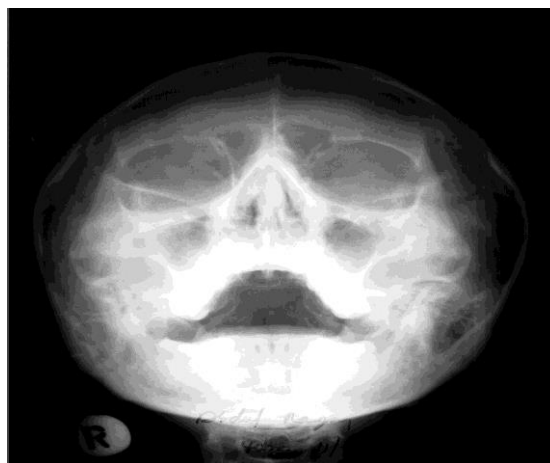


Fig. c




Fig. d

Discussion

The mechanism of orbital injuries, the retention of several kinds of foreign bodies,^{1,2,3,4} their complications, investigations and the modalities of treatments have all been reported in several literatures^{5,6}. To the best of our knowledge, this article is the first of its kind reporting “fish bones” in the orbit.

The patient diving near a shallow coral reef was not wearing any diving suit or aquatic eye glasses when this incident occurred. Being well aware about the marine life, he informed us that he was bitten by a small and a common fish, nicknamed “half beak” (Family-Hemiramphidae⁸). These are usually found swimming just under the sea surface, above the reef edge and off the reef slope. They are easily identifiable and usually harmless. They measure 26-30 cms in length and have a characteristic long, pointed beak like, upper and lower jaw as shown in the fig. d. They usually

feed upon smaller fishes, sea grass, algae and diatoms.⁸

The patient might have been inadvertently struck by the pointed, needle like jaw of this fish, causing a minimal penetrating entry wound. The bony tip broke and was thereby retained in the orbit. The entry wound being trivial and there being no evidence of any globe perforation, the possibility of a retained foreign body was clearly overlooked. The strong suspicion of a foreign body granuloma was once again assigned an incorrect location in the lid margin. The foreign body was assumed to be radiolucent when x ray PNS was reported normal. This warranted an orbital CT/ MRI scan for the exact localization of the impacted foreign body.

Hence, we conclude, howsoever trivial may the orbital wound entry be, the possibility of a retained orbital foreign body must always be excluded by asking for an appropriate scan before any surgical procedure. Nevertheless, we were able to achieve good cosmetic results with minimal scarring.

References

1. Betharia SM, Kumar H, Orbital wooden foreign bodies- a case report, IJO1989 jul-sep,37(3):146-7.
2. Adamiak G, Groghulska E. Rare case of a large foreign body in the orbital region, Otolaryngol Pol. 2002;56(5):617-20.
3. Agarwal PK, Kumar H, Srivastava PK. Unusual orbital foreign bodies, IJO 1993 Oct;41(3):125-7.
4. Korynta J, Kozak J, Ramba J. A huge foreign body in the orbit, Cesk Slov Oftalmol.2001 Jan;57(1):47-50.
5. Michon J, Liu D. Intraorbital foreign bodies, Semin Ophthalmol. 1994Sep;9(3):193-9.
6. Bullock JD, WarwarRE, Bartley GB, WallerRR, Henderson JW. Unusual orbital foreign bodies, Ophthal Plast Reconstr Surg 1999 Jan;15(1):44-51.
7. Anavi Y, Calderon S. Metallic foreign body in the orbit. Ann Ophthalmol. 1994Jan-Feb;26(1):17-9.
8. Charles Anderson, Ahmed Hafiz, in Common Reef fishes of the Maldives Part 3 (1996) Novelty printers & publishers, p11.