

Content available at: <https://www.ipinnovative.com/open-access-journals>

IP International Journal of Ocular Oncology and Oculoplasty

Journal homepage: <https://ijooo.org/>

Case Report

Neglected preseptal wooden foreign body: A rare presentation

Rajendra Prakash Maurya^{1,*}, Manisha¹, Anurag Kashyap¹, Manish Karn¹, V P Singh¹

¹Regional Institute of Ophthalmology, IMS, Banaras Hindu University, Varanasi, Uttar Pradesh, India



ARTICLE INFO

Article history:

Received 20-04-2022

Accepted 03-05-2022

Available online 09-05-2022

Keywords:

Intraorbital foreign bodies

ABSTRACT

Intraorbital foreign bodies can be metallic, non metallic and organic in their composition. Organic foreign bodies especially wooden, can act as a nidus of infection if left in situ. The diagnosis of a wooden foreign body is quite difficult radiologically because of their radiolucent nature so, they require high degree of suspicion. We report this case of a patient who presented with non healing persistent discharging sinus from left eye lateral part of the upper lid just above the eye lid margin following trivial trauma 6 months back. Based on the clinical evaluation and radiological evidence we made a diagnosis of retained wooden intraorbital foreign body. LE orbit surgical exploration and removal of wooden foreign body was done and the patient responded well postoperatively.

This is an Open Access (OA) journal, and articles are distributed under the terms of the [Creative Commons Attribution-NonCommercial-ShareAlike 4.0 License](#), which allows others to remix, tweak, and build upon the work non-commercially, as long as appropriate credit is given and the new creations are licensed under the identical terms.

For reprints contact: reprint@ipinnovative.com

1. Introduction

Intraorbital foreign bodies are quite rare findings to come across in practice especially post trauma. The clinical presentation, investigation, treatment and their outcome depend upon the type, location, size and extension of the intraocular foreign bodies.¹ They can be divided into metallic, non metallic and organic based on their composition. While metallic foreign bodies are considered to be inert in nature; organic foreign bodies especially wooden, can act as a nidus of infection and hence can lead to abscess formation, orbital cellulitis, persistent discharging sinus, exophthalmos and are also known to cause extraocular muscle damage.² The diagnosis of a wooden foreign body is quite difficult as they are often missed on X-ray, USG, CT scan and even MRI especially the smaller ones because of their radiolucent nature. All of the above listed factors contribute to the poor prognosis of wooden intraorbital foreign bodies. So, they require high

degree of suspicion even after mild ocular trauma and their timely management.

2. Case Report

A 18 years old female patient had a very trivial history of trauma by palm tree leaf 6 months ago in left eye upper lid (it was insignificant to her). For the initial 3 months post trauma she did not have any symptom. After 3 months, she developed pain which was mild in nature, gradually progressive swelling with present size of around 2cm in length and 1 cm in width located in left eye upper lid involving lateral part of the lid just above the eye lid margin and persistent pus discharge from the swelling. For this complaint she went to some local practitioner where she was given treatment in form of oral antibiotics and pain killers. When she did not get relieved, she presented to our OPD with complaint of non resolving pus discharge from the swelling. The patient was examined thoroughly in our hospital. There was a swelling of approximately 1.5cm × 0.5cm located in lateral aspect of the left eye upper lid

* Corresponding author.

E-mail address: mauryarp_bh@yahoo.com (R. P. Maurya).

located around 1cm above the upper lid margin and lateral canthus. Bilateral eye brows and eyelids were at normal levels. On palpation, a hard tender mass was palpated. The overlying skin was adhered to the mass (Figure 1). CT scan was advised to rule out osteomyelitis and retained intraorbital foreign body.

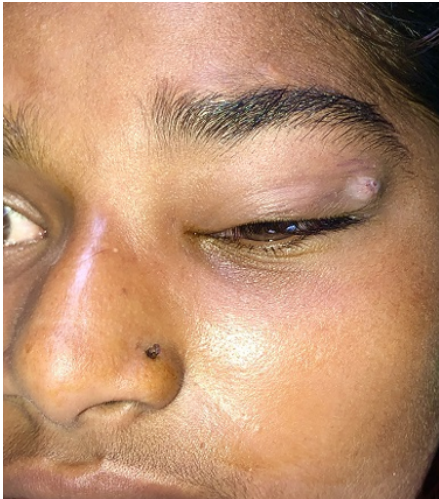

Fig. 1: Swelling in left eye lateral part of the upper lid just above the eye lid margin with non healing persistent discharging sinus

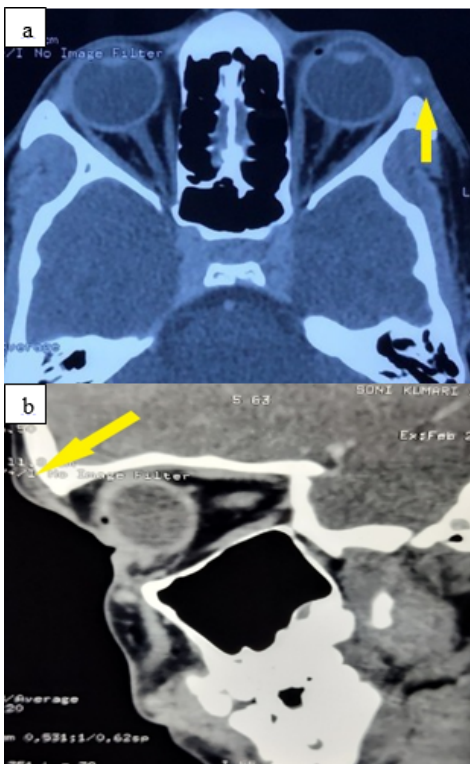


Fig. 2: a & b: CT scan image showing an isointense lesion with illdefined margin in anterior part of LE lateral orbital wall

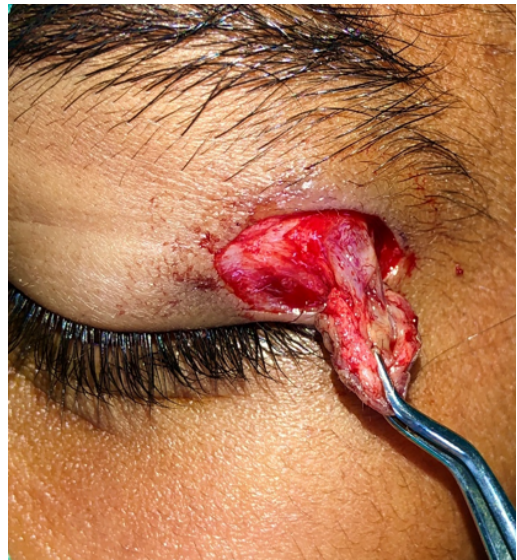

Fig. 3: A horizontal superficial incision given and the orbicularis oculi muscle being dissected.

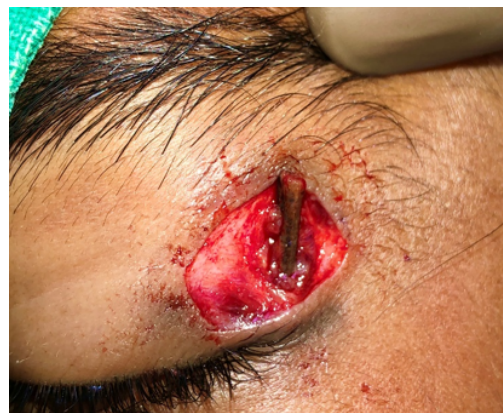

Fig. 4: After removal of necrotic tissue a retained preseptal wooden foreign was identified and then removed.

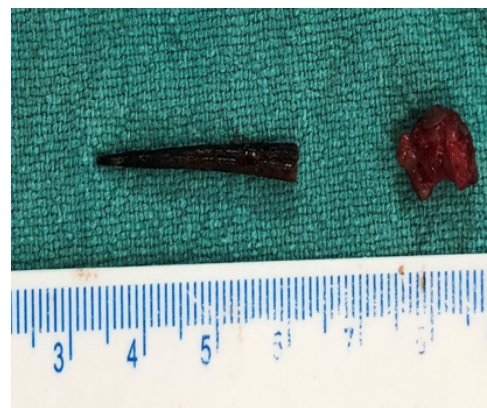


Fig. 5: Showing wooden foreign body (piece of palm leaf) about 2.5 cm size.

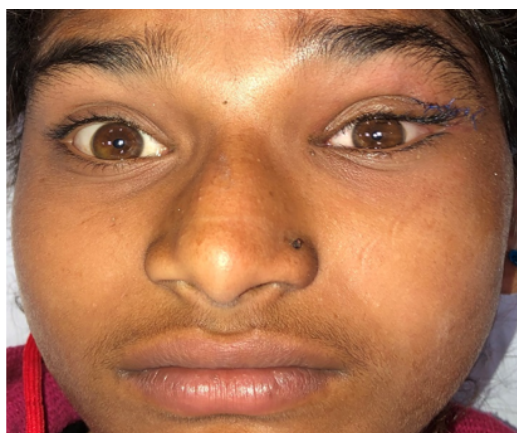

Fig. 6: The wound was closed by 5'0 prolene and the postop day 1 appearance.

CT scan showed an isointense circular lesion with well defined margin in anterior aspect of lateral orbital wall (\$). It was not associated with either intracranial extension or any orbital wall damage.

On examination, visual acuity of both eyes was 6/6. There was no restriction of extraocular movement. After detailed clinical and radiological evaluation, surgical exploration of LE orbit was planned. A horizontal superficial incision was given in superotemporal part of the orbit around 1cm above the lateral 1/5th of lid margin. After removal of necrotic tissue and dissecting the orbicularis oculi muscle superficially, a retained preseptal intraorbital wooden foreign body of around 2.5cm×0.5cm was removed very gently with forceps (Figures 3 and 4). The wound was later closed by 5'0 prolene. The patient was given broad spectrum antibiotic coverage post operatively. There was no restriction of extraocular muscles, visual acuity was 6/6 in both eyes and there was no associated ptosis (Figure 5).

3. Discussion

Bartkowski et al in a study found that out of 677 cases of orbital trauma, the incidence of intraorbital trauma was 2.9% i.e. 20 in total.³ As it has been said earlier the intraorbital foreign bodies can be metallic, non metallic and organic. Among the above classification, wooden foreign bodies are not only difficult to be diagnosed by various imaging modalities, they also impose several complications if left in situ. Wooden foreign bodies especially, can lead to secondary infections or they can undergo decay leading to severe inflammation.⁴ Their porous consistency and organic nature acts as ideal environment for micro-organism growth.^{4,5}

Even minor trauma which patient considers insignificant at times, can be overlooked. Thus delaying the management and hence can cause further deterioration and its sequelae can occur which are even more difficult to manage.

There are both advantages and disadvantages of all available imaging techniques for finding intraorbital foreign bodies especially wooden ones. On X rays, wooden foreign bodies appear radiolucent making it almost impossible to be detected, the detection rate being 0-15%.⁶ CT scan is considered to be the gold standard for intraorbital foreign body detection but CT picture in case of wooden foreign body changes over time and composition of celluloid matrix. In CT scan they are often misdiagnosed as emphysema in acute stages as wood resembles air at this stage. It resembles fat in subacute stage. In chronic cases it becomes hyperintense than extraocular muscles, which increases chances of detection on CT. MRI on the other hand can detect both dry and fresh wood but it cannot be used when there is slightest possibility of presence of metallic foreign body. Both dry and fresh wood appear hypointense relative to the intraorbital fat in T1 as well as T2 weighted MRI both with and without gadolinium.^{7,8} Higher cost and more scan time makes MRI more unfavourable for its use in detecting intraorbital foreign bodies.^{9,10} USG like MRI requires expertise, while less effective in detecting wooden foreign bodies. So, basically no single imaging is best for detection of intraorbital foreign bodies.

Surgical removal of foreign bodies should be done with caution. It is due to the fact that fragmentation while removal may lead to retained pieces which can cause further damage.

We hereby report this case of intraorbital foreign body which went unnoticed. It was post insignificant and trivial history of trauma where patient presented with non healing persistent discharging sinus with no improvement with the antibiotic treatment. The patient did not even experience any sort of symptom for initial 3 months of trauma. This case required high degree of suspicion, and was managed surgically and responded well to the treatment given.

4. Conflict of Interest

The authors declare that there are no conflicts of interest in this paper.

5. Source of Funding

None.

References

1. Santos TDS, Melo AR, Moraes HHA, Junior PA, Dourado ED. Impacted foreign bodies in orbital region: review of nine cases. *Arq Bras optalmol.* 2010;73(5):438–42.
2. Kim YH, Kim H, Yoon ES. Unrecognized intraorbital wooden foreign body. *Arch Craniofac Surg.* 2018;19(4):300–3.
3. Bartkowski SB, Kurek M, Stypulkowska J, Krzystkowska KM, Zapala J. Foreign bodies in the orbit: review of 20 cases. *J Maxillofac Surg.* 1984;12(3):97–102. doi:10.1016/s0301-0503(84)80221-0.
4. Sitaula S, Gautam V. Intraorbital wooden foreign body: a case report. *J Kathmandu Med Coll.* 2014;3(3):119–21.
5. Potapov AA, Eropkin SV, Kornienko VN, Arutyunaw NV, Yelochiyana SA, Serova NK, et al. Late diagnosis and removal of a large

- wooden foreign body in cranio-orbital region. *J Craniofac Surg.* 1996;7(4):311–4. doi:10.1097/00001665-199607000-00012.
6. Bray LC, Griffiths PG. The value of plain radiography in suspected intraocular foreign body. *Eye (Lond).* 1991;5(6):751–4. doi:10.1038/eye.1991.138.
 7. Dunn IF, Kim DH, Rubin PA, Blinder R, Gates J, Golby AJ, et al. Orbitocranial wooden foreign body: a pre-, intra-, and postoperative chronicle :case report. *Neurosurgery.* 2009;65(2):383–4. doi:10.1227/01.NEU.0000347474.69080.A1.
 8. Nagae LM, Katowitz WR, Bilaniuk LT, Anninger WV, Pollock AN. Radiological detection of intraorbital wooden foreign bodies. *Pediatr Emerg Care.* 2011;27(9):895–6. doi:10.1097/PEC.0b013e31822d3df2.
 9. Kumar GA, Dhupar V, Akkara F, Kumar P. Foreign body in the orbital floor: a case report. *J Maxillofac Oral Surg.* 2015;14(3):832–5. doi:10.1007/s12663-014-0708-7.
 10. Lee JA, Lee HY. A case of retained wooden foreign body in orbit. *Korean J Ophthalmol.* 2002;16(2):114–8. doi:10.3341/kjo.2002.16.2.114.

Author biography

Rajendra Prakash Maurya, Associate Professor

Manisha, Junior Resident

Anurag Kashyap, Senior Resident

Manish Karn, Junior Resident

V P Singh, Professor

Cite this article: Maurya RP, Manisha, Kashyap A, Karn M, Singh VP. Neglected preseptal wooden foreign body: A rare presentation. *IP Int J Ocul Oncol Oculoplasty* 2022;8(1):64-67.