

Content available at: <https://www.ipinnovative.com/open-access-journals>

IP International Journal of Ocular Oncology and Oculoplasty

Journal homepage: <https://ijooo.org/>

Case Report

Series of cases of congenital cataract in the family

Jyotsana Soni^{1,*}, H Mohan Kumar¹, Sana Rasheed¹

¹Dept. of Ophthalmology, Saphthagiri Institute of Medical Science and Research Centre, Bengaluru, Karnataka, India



ARTICLE INFO

Article history:

Received 28-12-2021

Accepted 31-12-2021

Available online 07-02-2022

Keywords:

Lamellar cataract

ABSTRACT

Cataract is one of the main causes of preventable childhood blindness. It can be either hereditary or non-hereditary. Paediatric cataracts are idiopathic in majority of cases. Major challenge in pediatric cataract is to overcome amblyopia. Early diagnosis and prompt treatment can result in good visual prognosis.

In this case series, we present three siblings having congenital cataract. They presented to our hospital in their mid and late twenties for the cataract surgeries. Detailed examination of these cases were done and many other systemic abnormalities were detected along with ocular findings. Small incision cataract surgery under GVP under GA was done for all three cases.

There was no history of congenital cataract in the family. one of the sibling younger brother did not have congenital cataract and other abnormalities. Early diagnosis and treatment avoids long-term adverse sequelae like strabismus and amblyopia. Late presentation, cataract surgery can be done and we can accept visual outcome as shown in these cases. Visual rehabilitation with adequate compliance can have a benefit in improving visual acuity and binocularity.

Even though early surgical intervention is mandatory to have adequate visual outcome, nevertheless visual rehabilitation can also be expected in congenital cataracts with late presentation as seen in these cases.

This is an Open Access (OA) journal, and articles are distributed under the terms of the [Creative Commons Attribution-NonCommercial-ShareAlike 4.0 License](https://creativecommons.org/licenses/by-nc-sa/4.0/), which allows others to remix, tweak, and build upon the work non-commercially, as long as appropriate credit is given and the new creations are licensed under the identical terms.

For reprints contact: reprint@ipinnovative.com

1. Introduction

Cataracts have been considered as one of the main causes of avoidable childhood blindness and affecting approximately 200,000 children worldwide.^{1,2} Genetic factors, metabolic diseases and intrauterine infections are among the leading causes of cataracts in children, apart from those secondary to injury or iatrogenic (drugs, radiation therapy, laser therapy, etc.).³ Paediatric cataracts are mostly idiopathic in developed countries.

The first years of life are crucial for the development of a child's vision and therefore irreversible amblyopia can be induced by blurred and distorted retinal image over that period.⁴ Vision impairment may still be reverted as long as an adequate therapy is carried out over the period of sensory

plasticity. Timely diagnosis and treatment are crucial for the prevention of any major complication. Knowledge regarding epidemiological and clinical characteristics of paediatric cataracts has a positive impact in management and improvement, particularly in favour of an early diagnosis and improved outcome.⁵

2. Case History

Three patients were brought by their father to our hospital for evaluation of defective vision since birth.

2.1. Case 1

The first child of the family, 30 years old male with visual acuity of CF2m in both eye was diagnosed with both eye lamellar cataract.

* Corresponding author.

E-mail address: jyotsanasoni21@gmail.com (J. Soni).

Table 1: Other findings

	Case 1	Case 2	Case 3
ENT	B/L TypeA tympanogram s/o middle ear pathology	B/L TypeA tympanogram s/o middle ear pathology R and L mixed hearing loss	B/LTypeC tympanogram s/o eustacian tube dysfunction
Psychiatry	Moderate mental retardation	Moderate mental retardation	Moderate to severe mental retardation
Orthopedics	-	B/L Flat Foot	Scoliosis
Dermatology	Sebaceous hyperplasia on nose	-	-
2D Echo	EF 60%	EF 60%	EF 60% Trivial MR Trivial MVP Trivial TR
Gynaecology	-	-	Irregular menses

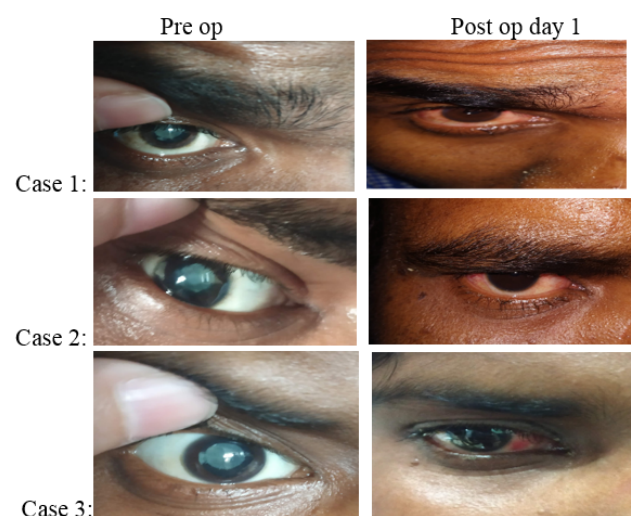
2.2. Case 2

The second child of the family, 27years old male with visual acuity of CF3m in both eye was diagnosed with both eye lamellar cataract.

2.3. Case 3

The third child of the family, 25 years old female with visual acuity of CF1m in both eye was diagnosed with both eye lamellar cataract and LE dermoid cyst with regressed pannus @4:00 position at limbus.

All three underwent RE SICS with pciol implantation under guarded visual prognosis under general anaesthesia. The lens implanted were of 28.0D in case 1, 16.5D in case 2, and 18D in case 3. The post operative vision in case 1 was CF5m, in case 2 was CF6m, in case 3 was CF5m.

**Fig. 1:**

3. Discussion

Blindness caused by childhood cataract in developing countries is primarily a result of inadequate or timely use of surgical services.⁶ The shorter the duration between

onset of visually impairing cataract and surgery, the greater the likelihood that surgical intervention will lead to a good visual outcome. Children with congenital cataract are more likely to have total cataracts leading to severe visual deprivation compared to children with developmental cataract in whom the cataract may develop more gradually. Regardless of the type of cataract, early presentation is important for visual outcome. The excessive delay in presentation in these cases, suggests that there are barriers to presentation to surgery, including awareness of the problem, access to surgical services, or acceptance of surgical services. The major delay occurred between recognition by the patient and late presentation to the hospital rather than between the presentation to treatment delay. This suggests that the primary barriers exist at the community level rather than the provider level. There is ignorance and lack of proper education in the family about vision in the growing child.^{7–10}

In this series, the siblings had defective vision since birth which was neglected due to lack of knowledge and awareness among the family members. There was no history of consanguineous marriage. No history of congenital cataract in forefathers or in the next sibling after them. The youngest brother of these siblings was normal with no vision defect. After explaining the prognosis to the parents about dense amblyopia. High risk consent was taken and they were operated under GA. Though late presentation (late-twenties) for surgery, surprisingly all three showed improvement in vision post operatively.

Hence, Newborn eye examination is required for early diagnosis. Early diagnosis and treatment avoids long-term adverse sequelae like strabismus and amblyopia. Visual rehabilitation with adequate compliance can have a benefit in improving visual acuity and binocularity.

4. Conclusion

Delay in presentation remains a significant problem for children with congenital or developmental cataract and is a great challenge for the surgeon. Even though early surgical intervention is mandatory to have adequate visual outcome, nevertheless visual rehabilitation can also be expected in

congenital cataracts with late presentation as seen in these cases. Patient awareness is the need of the hour for early intervention and good visual outcome in congenital cataract.

5. Conflicts of Interest

The authors declare that there are no conflicts of interest regarding the publication of this paper.

6. Source of Funding


None.


References

1. Foster A, Gilbert C, Rahi J. Epidemiology of cataract in childhood: a global perspective. *J Cataract Refract Surg.* 1997;23(1):601–4. doi:10.1016/s0886-3350(97)80040-5.
2. Maurya RP. Burden of cataract in developing countries. *Ind J Clin Exp Ophthalmol.* 2018;4(1):1.
3. Lim Z, Rubab S, Chan YH, Levin AV. Pediatric cataract: the Toronto experience- etiology. *Am J Ophthalmol.* 2010;149(6):887–92. doi:10.1016/j.ajo.2010.01.012.
4. Elston JS, Timms C. Clinical evidence for the onset of the sensitive period in infancy. *Br J Ophthalmol.* 1992;76(6):327–8. doi:10.1136/bjo.76.6.327.
5. Moreira J, Ribeiro I, Mota A, Gonçalves R, Coelho P, Maio T, et al. Cataratas em Idade Pediátrica: Estudo Retrospectivo de 12 Anos (2004 - 2016). *Acta Medica Portuguesa.* 2004;30(3):169–74.
6. Khokhar SK, Pillay G, Dhull C. Pediatric cataract. *Ind J Ophth.* 2017;65(12):1340–9.
7. Waddel KM. Childhood blindness and low vision in Uganda. *Eye.* 1998;12(Pt 2):184–92. doi:10.1038/eye.1998.4.
8. Vasavada AR, Shah SK, Vasavada V. Management Options in Pediatric Cataract. *US Ophth Rev.* 2012;5(1):44–7.
9. Aryee S, Jones RD. The paediatric cataract: an overview of the diagnosis and management. *Tainee.* 2020;27(2).
10. American Academy of Ophthalmology. Childhood cataracts and other pediatric lens disorders. In: Basic and clinical science course, section 6. San Francisco: Pediatric Ophthalmology and Strabismus; 2014-15.

Author biography

Jyotsana Soni, Junior Resident  <https://orcid.org/0000-0002-0852-9342>

H Mohan Kumar, Professor and HOD  <https://orcid.org/0000-0002-7252-5776>

Sana Rasheed, Junior Resident  <https://orcid.org/0000-0002-4593-9690>

Cite this article: Soni J, Kumar HM, Rasheed S. Series of cases of congenital cataract in the family. *IP Int J Ocul Oncol Oculoplasty* 2021;7(4):418-420.