

Content available at: <https://www.ipinnovative.com/open-access-journals>

IP International Journal of Ocular Oncology and Oculoplasty

Journal homepage: <https://ijooo.org/>

## Original Research Article

## A comparative study of endothelial cell loss in small incision cataract surgery versus phacoemulsification cataract surgery by using specular microscope at tertiary care ophthalmic centre in Bengaluru, Karnataka

Radhika Srinivasagupta Mohan<sup>1</sup>, Sanjana Marijogaiah Singasandra<sup>1,\*</sup>,  
Dakshayini Mallaiiah<sup>1</sup>, Shwetha Bennavara Venkataswamy<sup>1</sup>

<sup>1</sup>Dept. of Ophthalmology, Bangalore Medical college and Research Institute, Bangalore, Karnataka, India



## ARTICLE INFO

## Article history:

Received 03-01-2022

Accepted 13-01-2022

Available online 07-02-2022

## Keywords:

MSICS

Phacoemulsification

Specular microscopy

endothelial cell loss

## ABSTRACT

**Background:** Most commonly performed surgical procedure in Ophthalmology is cataract extraction by MSICS and Phacoemulsification. It has always been associated with damage to endothelium of cornea, a layer which is vital for maintaining corneal transparency. The corneal endothelium regulates stromal hydration and maintains the transparency of the cornea by constantly removing the fluid out of the corneal stroma. The density of corneal endothelial cells and its integrity is an important determinant for corneal transparency. Post-operative corneal decompensation leading to reduced visual acuity can occur as a result of this surgical trauma. Hence it is necessary to determine the surgical technique safest to corneal endothelium. Specular microscopy helps to determine this corneal endothelial cell density.

**Materials and Methods:** A hospital based longitudinal study was done from November 2017 to May 2019 in 124 patients at Minto Ophthalmic Hospital. 62 patients underwent MSICS and 62 phacoemulsification. After a written informed consent patients were evaluated with detailed history, slit lamp examination, direct and indirect ophthalmoscopy, biometry, lacrimal syringing, IOP measurement with tonometry and endothelial cell count was evaluated using non contact specular microscopy preoperatively and postoperative 1 week and 6 weeks. Statistical data analysed by unpaired – t test.

**Results:** The mean ECC (cells/mm<sup>2</sup>) in MSICS and phacoemulsification group preoperatively was 2486.82 + 152.730 and 2433.71 + 192.692 respectively. The mean endothelial cell loss (cells/mm<sup>2</sup>) was 314.61 + 64.428 and 324.31 + 30.67 at 1 week and 345.71 + 66.68 and 354.95 + 53.885 at 6 weeks postoperatively between the two groups. The endothelial cell loss was not statistically significant at 1 week (p -0.28) and 6 weeks (p-0.39) postoperatively between the two groups.

**Conclusion:** There was no clinically or statistically significant difference in the endothelial cell loss between MSICS and Phacoemulsification. As MSICS is economical and less dependent on technology, it can be a safe option in developing world.

This is an Open Access (OA) journal, and articles are distributed under the terms of the [Creative Commons Attribution-NonCommercial-ShareAlike 4.0 License](https://creativecommons.org/licenses/by-nc-sa/4.0/), which allows others to remix, tweak, and build upon the work non-commercially, as long as appropriate credit is given and the new creations are licensed under the identical terms.

For reprints contact: [reprint@ipinnovative.com](mailto:reprint@ipinnovative.com)

### 1. Background

The endothelial cell layer of cornea is made up of a monolayer of polygonal cells that help in maintaining corneal deturgescence. The average endothelial cell count

is about 3000 cells/ sq.mm.<sup>1</sup> Under normal circumstances, the corneal endothelial cells do not proliferate because they are arrested in the G1 phase of cell cycle. The rate of decrease in the cell count is 0.6% every year in normal corneas throughout the adult life with gradual increase in the polymegathism and pleomorphism.<sup>1</sup> The corneal endothelium regulates stromal hydration and maintains the

\* Corresponding author.

E-mail address: [sanjanasm07@gmail.com](mailto:sanjanasm07@gmail.com) (S. M. Singasandra).

transparency of the cornea by constantly removing the fluid out of the corneal stroma. This function is done by active metabolic pumps in the corneal endothelium. Normal corneal hydration represents a balance between the leak across the endothelium and the movement of water by the metabolic pump ( $\text{Na}^+ \text{K}^+ \text{ATPase}$  pump). Thus endothelial cell density and integrity of endothelial cells determines the corneal transparency. Reduction in the endothelial cell count to 400-700 cells/ $\text{mm}^2$  results in corneal endothelial decompensation and edema.<sup>2</sup> This leads to loss of corneal transparency affecting the visual acuity. After the loss of endothelial cells, adjacent cells enlarge and slide over to maintain the endothelial cell continuity, which can be seen as a change in endothelial cell density and morphology. Thus endothelial cell density (ECD) is an important parameter clinically.<sup>3</sup> Thus the structure and function of endothelium of cornea can be best assessed using a non invasive technique- Specular Microscopy.

The most commonly performed surgery in Ophthalmology is cataract extraction by MSICS and Phacoemulsification. The reduction in the endothelial cell count is common after any cataract surgery. Post-operative corneal decompensation can occur as a result of this surgical trauma. Endothelial cell loss during cataract surgery depends on the technique used, instrumentation, use of protective viscoelastic material and the irrigating solution used.<sup>4</sup>

There is concern that manual small incision cataract surgery (MSICS) may be more harmful to the endothelium than phacoemulsification because most of the manipulation is performed in the anterior chamber, but in phacoemulsification maneuvering is mechanical and performed in the capsular bag relatively away from the endothelium.<sup>5</sup> Significant loss of corneal endothelial cells results in corneal decompensation and loss of corneal clarity.

Manual SICS with Intraocular lens (IOL) implantation could be a viable cost-effective alternative to Phacoemulsification in developing countries like India, where there is a cataract backlog. Therefore it is important to determine the surgical technique that is safest to the corneal endothelium.

## 2. Aims and Objectives

To compare the corneal endothelial cell loss between Manual small incision cataract surgery (MSICS) and Phacoemulsification by using non contact specular microscope.

## 3. Materials and Methods

A hospital based longitudinal study was conducted among patients with senile cataract undergoing manual small incision cataract surgery and phacoemulsification at Minto

Ophthalmic Hospital, Regional Institute of Ophthalmology attached to Bangalore Medical College and Research Institute from November 2017 to May 2019. Patients were randomly allocated into two groups, one undergoing MSICS and other phacoemulsification cataract surgery.

### 3.1. Sample size

1. Patients were included in the study
2. Group A: 62 patients undergoing MSICS.
3. Group B: 62 patients undergoing Phacoemulsification.

### 3.2. Inclusion criteria

1. Patients willing to give written informed consent.
2. Patients 50 -90 years with cataract.

### 3.3. Exclusion criteria

1. Endothelial cell count <2000cells/ $\text{mm}^2$
2. Nuclear sclerosis grade 4, senile mature and hypermature cataract
3. Uveitis
4. Traumatic cataract
5. Glaucoma
6. Corneal pathologies
7. Ocular surgeries or ocular trauma in the past
8. Diabetes
9. Pseudoexfoliation
10. Complicated cataract

Preoperative evaluation of all patients was carried out in which a detailed history was taken followed by systemic and ocular examination.

1. Demographic data (patient's name, age, sex, address and occupation) was noted.
2. A detailed medical and ophthalmic history was taken.
3. Snellen's chart was used to record the best corrected visual acuity.
4. Slit lamp biomicroscopy was done for anterior segment evaluation and also to evaluate and grade the type of cataract.
5. IOP was recorded using Perkin's tonometer.
6. Lacrimal syringing was done.
7. Keratometry and A-scan biometry was done for intra ocular lens(IOL) power calculation.
8. Endothelial cell count was obtained using non contact specular microscope [Tomey EM-3000].
9. Fundus examination was done after full dilatation of pupil.

Group A underwent MSICS and Group B underwent phacoemulsification.

One day before surgery patients were instructed to use topical antibiotic ofloxacin (0.3%) eye drops hourly. On the day of surgery the operating eye was dilated using

tropicamide (0.8%) and phenylephrine (5%) eye drops every 10-15 min starting one hour prior to surgery. After full dilatation of pupil flurbiprofen (0.03%) eye drops was instilled to prevent intraoperative miosis.

Anaesthesia: All patients undergoing surgery were given 5ml peribulbar block with 2% lignocaine and 1:1000 adrenaline along with hyaluronidase.

### 3.4. Surgical procedure

#### 3.4.1. MSICS

After taking all aseptic precautions, eye was painted with 10% povidone iodine (for skin), drape was applied, universal wire speculum was placed and one drop of 5% povidone iodine was instilled into conjunctival sac and then the superior rectus bridle suture was passed and clamped to towel. A fornix based conjunctival flap was made from 10 to 2 o'clock position. Sclera was exposed and haemostasis achieved using wet field cautery. Scleral incision of around 5.5-7.5mm, about one third thickness of sclera was made 1.5-2mm away from limbus. Sclerocorneal tunnel was made using 2.8mm crescent knife and scleral pockets were dissected on either sides. Side port made at 9 o'clock and after staining the capsule with trypan blue dye, Ocular Viscoelastic Device (OVD)[Hydroxy propyl methyl cellulose 2%] was injected into anterior chamber. Continuous curvilinear capsulorhexis was done using a 26G cystitome. Then entry into AC was made using 3.2mm keratome. Hydrodissection and hydrodelineation was done and the nucleus was prolapsed into AC. OVD was injected into AC and nucleus was delivered out by using a wire vectis method. Irrigation and aspiration of cortex was done. OVD was again injected into AC and a rigid PMMA IOL was inserted into capsular bag. Removal of OVD is done with help of two way irrigation and aspiration cannula. AC formed with saline. Side port was sealed by hydrating it with BSS. Conjunctival flap repositioned back and then subconjunctival injection of antibiotic and steroid was given.

#### 3.4.2. Phacoemulsification

After taking all aseptic precautions, eye was painted with 10% povidone iodine (for skin), drape was applied, universal wire speculum was placed and one drop of 5% povidone iodine was instilled into conjunctival sac. A 2.8 mm sized incision in the clear cornea was created for the phaco probe, and two side ports were created of 0.8mm each. HPMC 2% was inserted in the anterior chamber and then a continuous curvilinear capsulorhexis was performed with a cystitome after staining the anterior capsule with trypan blue. Hydrodissection and hydrodelineation was done adequately. Then phacoemulsification of nucleus was done using Divide and Conquer method. Aspiration of residual cortical lens matter was performed using bimanual irrigation and aspiration technique. Viscoelastic substance was injected into anterior chamber and then foldable IOL

was inserted into capsular bag with the help of injector system. Removal of OVD is done with help of two way irrigation and aspiration cannula. AC formed with saline. All the wounds were sealed by hydrating them with BSS. Finally a subconjunctival injection of antibiotic and steroid was given.

Phaco	Power	Vacuum	Flow Rate
Trenching	60%	10-15mmHg	10-20 cc/min
Quadrant emulsification	50-60%	200-220mmHg	25-30 cc/min

Post operatively the following examination was done:  
Post-operative day 1

1. Visual acuity using Snellen's chart
2. Anterior segment slit lamp examination
3. Fundus examination

Post-operative day 7 and then at post-operative 6 weeks

1. Visual acuity using Snellen's chart.
2. Anterior segment slit lamp examination.
3. Fundus examination.
4. Endothelial cell count by non contact specular microscope.

All the surgeries were performed by the same surgeon and none of these cases had vitreous loss.

Data analysis was done using IBM. SPSS statistics software 20.0 version. Descriptive statistics of the explanatory and outcome variables was calculated by mean, standard deviation for quantitative variables, frequency and proportions for qualitative variables. Unpaired t test was applied to check the statistical difference between quantitative variables. The level of significance is set at 5%.

## 4. Results

In this study a total of 124 eyes of 124 patients who underwent cataract surgery were included. They were divided into two groups:-

Group A: 62 patients who underwent MSICS.

Group B: 62 patients who underwent Phacoemulsification.

The results were as follows:

### 4.1. Sex distribution

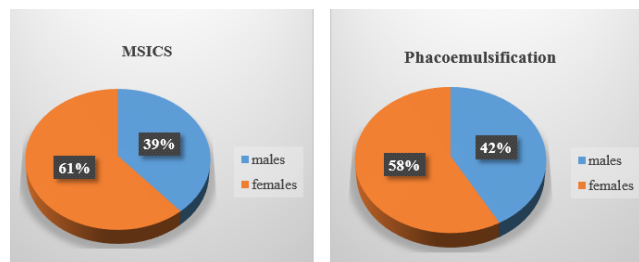
In the present study females outnumbered the males in both the groups i.e., 61.3% in SICS group and 58.1% in phacoemulsification group.

### 4.2. Age distribution

The mean age of the study subjects in group A and group B was 59.68 + 7.05 years and 62.65 + 5.97 years respectively.

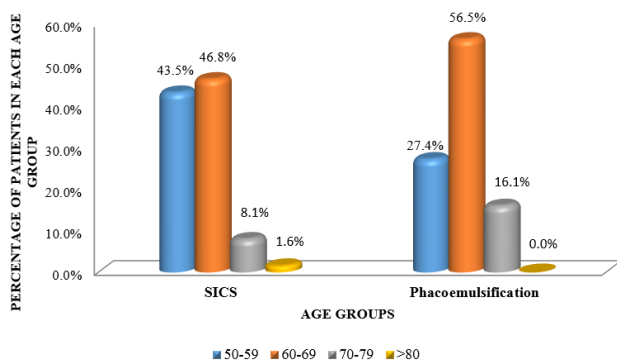
**Table 1:** Sex distribution between two groups

Sex	SICS	Phacoemulsification
Female	38 61.3%	36 58.1%
Male	24 38.7%	26 41.9%
Total	62 100.0%	62 100.0%



**Fig. 1:** Pie chart showing sex distribution between two groups

The minimum age in both the groups was 50 years and the maximum age was 80 years and 75 years in MSICS and Phacoemulsification groups respectively.



**Fig. 2:** Showing distribution of the study subjects according to age group

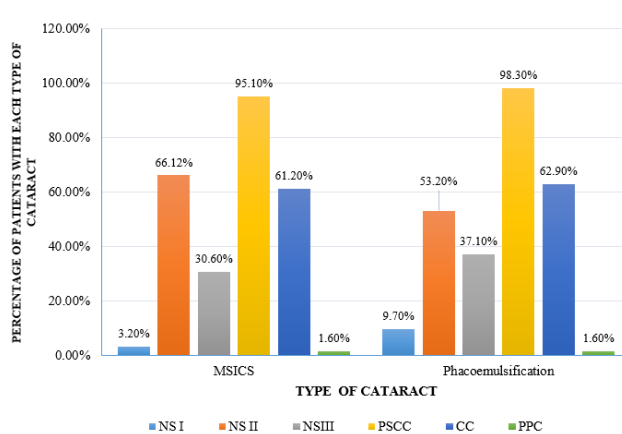
### 4.3. Type of cataract

In this study all the patients had nuclear sclerosis and grade II nuclear sclerosis was found to be a majority in both the groups followed by was posterior sub capsular cataract and then cortical cataract and posterior polar cataract.

The mean ECC (cells/mm<sup>2</sup>) in group A (MSICS) and group B (phacoemulsification) pre operatively was 2486.82 + 152.730 and 2433.71 + 192.692 respectively.

At 1 week postoperative, the mean ECC (cells/mm<sup>2</sup>) was 2172.21 + 188.649 and 2109.40 + 186.396 in group A and group B respectively.

There was a mean cell loss of 314.61 + 64.428 cells/mm<sup>2</sup> and 324.31 + 30.670 ells/mm<sup>2</sup> in group A and group B



**Fig. 3:** Bar graph showing the distribution of type of cataract

respectively at 1 week postoperatively.

Unpaired t test showed that there was no statistically significant difference in the endothelial cell loss at postoperative 1 week between the groups (p – 0.287).

The mean ECC (cells/mm<sup>2</sup>) in group A (MSICS) and group B (phacoemulsification) preoperatively was 2486.82 + 152.730 and 2433.71 + 192.692 respectively.

At 6 weeks postoperatively, the mean ECC (cells/mm<sup>2</sup>) was 2141.11 + 191.37 and 2078.76 + 191.592 in group A and group B respectively.

There was a mean cell loss of 345.71 + 66.68 cells/mm<sup>2</sup> and 354.95 + 53.885 cells/mm<sup>2</sup> in MSICS and phacoemulsification group respectively at 6 weeks postoperatively.

Unpaired t test showed that there was no statistically significant difference in cell loss at postoperative 6 weeks (p – 0.39).

### 5. Discussion

There is always a reduction in the endothelial cell density due to cell loss following cataract surgery. After cataract surgery, endothelial cell density decreases at a greater rate than in healthy, unoperated corneas. With the help of specular microscopy the response and effect of stress of surgical trauma to endothelium could be documented well.

MSICS is inexpensive compared to phacoemulsification and hence is popular in developing countries. However there are studies which have shown phacoemulsification also to be safe for corneal endothelium.<sup>6,7</sup> The result of our study shows that both the surgical techniques are safe for corneal endothelium.

Any change in the corneal endothelium is an important parameter of surgical trauma and thereby essential for estimating the safety of a surgical technique. The endothelial cell loss is different among various studies even though the mode of surgery is the same. This could be because of different inclusion and exclusion criteria,

**Table 2:** Endothelial Cell Count

Groups	ECC cells/mm <sup>2</sup>		
	Preoperative	Postoperative week 1	Postoperative week 6
Group A	2486.82±152.73	2172.21±188.65	2141.11±191.37
Group B	2433.71±192.69	2109.40±186.39	2078.76±191.592
t-test (P-value)	1.7 (0.09)	1.86 (0.06)	1.81 (0.07)

**Table 3:** Comparison of mean ECC at pre-operative, Postoperative 1<sup>st</sup> and 6<sup>th</sup> week between the groups

Groups	ECC cells/mm <sup>2</sup>		
	Preoperative	Postoperative week 1	Postoperative week 6
Group A	2486.82±152.73	2172.21±188.65	2141.11±191.37
Group B	2433.71±192.69	2109.40±186.39	2078.76±191.592
t-test (P-value)	1.7 (0.09)	1.86 (0.06)	1.81 (0.07)

**Table 4:** Comparison of mean endothelial cell loss at postoperative 1<sup>st</sup> and 6<sup>th</sup> week between the groups

Groups	Cell loss ( cells / mm <sup>2</sup> )	
	Postoperative week 1	Postoperative week 6
Group A	314.61±64.43	345.71±66.68
Group B	324.31±30.67	354.95±53.88
t-test (P-value)	-1.07 (0.29)	-0.85 (0.39)

difference in grades of cataract, the method of nucleus delivery and also on the irrigating solutions and Ocular Viscoelastic Devices (OVD) used. Also contact of corneal endothelium with instruments, lens fragments, IOL, the amount of energy released during phacoemulsification and the duration are also some of the factors for endothelial cell loss after cataract surgery as suggested by Elvira et al.<sup>8</sup> Several studies have reported that some preoperative and intraoperative parameters influence the risk of endothelial cell loss after phacoemulsification. Specifically, advanced age, hard nucleus density, high ultrasound energy, long phacoemulsification time, the phacoemulsification technique, and large infusion volumes can increase the risk of endothelial cell loss after phacoemulsification.

The mean preoperative endothelial cell count in the study population between the two groups was within the normal range of 2000- 3000 cells /sq.mm.<sup>3</sup> In the present study the cell loss was 314.61cells/sq.mm (12.7%) and 345.71cells/sq.mm (13.9%) in MSICS group at 1 week and 6 weeks postoperatively. The cell loss in phacoemulsification was 324.31cells/sq.mm (13.3%) and 354.95cells/sq.mm(14.6%) at 1 week and 6 weeks postoperatively. There was no statistically significant difference in endothelial cell loss between the two groups.

A study by Rupert et al. which compared the cell loss in phacoemulsification and ECCE showed a 10% reduction in endothelial cells in both groups.<sup>9</sup> Study by George et al showed 4.72%, 4.21% and 5.41% of endothelial cell loss after conventional ECCE, MSICS and phacoemulsification respectively.<sup>10</sup> There was no statistically significant difference in cell loss between the groups.

The results of the present study are similar to a study by Jagani et al which showed cell loss of 270.86cells/mm<sup>2</sup>(10.63%) and 385.22cells/mm<sup>2</sup>(15.12%) at 1 week and 6 weeks postoperative among MSICS group. After phacoemulsification cell loss was 307.80cells/mm<sup>2</sup>(12.33%) and 397.79cells/mm<sup>2</sup>(15.93%) at 1 week and 6 weeks postoperative respectively.<sup>11</sup>

In the present study we observed that female patients were more compared to male patients who underwent cataract surgery, 61.3% and 58.1% in MSICS and Phacoemulsification group respectively. Also the endothelial cell loss among males and females in both the groups was not statistically significant. This observation correlates with the study by Reshma Balan KT in which there were 54.54% and 57.89% of female patients in SICS and phacoemulsification group.<sup>12</sup>

Further in this study all the patients had nuclear sclerosis and grade II nuclear sclerosis was found to be a majority in both the groups. The least common type of cataract was posterior polar cataract.

A study conducted in Italy compared endothelial cell loss between scleral tunnel incision and clear corneal incision. According to this study from Italy, endothelial cell loss was less in scleral tunnel incision than clear corneal incision. This might be because the scleral tunnel incision is placed more posteriorly and thus induces less direct and indirect endothelial trauma.<sup>13</sup> However in the present study all patients underwent phacoemulsification with clear corneal incision.

A study by Tao Jiang et al showed endothelial cell loss of 259 cells/mm<sup>2</sup>(19%) and 289 cells/mm<sup>2</sup>(18.5%)

in SICS and phacoemulsification group at 4 weeks postoperatively.<sup>14</sup> Both in MSICS group and in phacoemulsification group, the postoperative BCVA got improved significantly. The results of our study is also similar to the above study with regard to endothelial cell loss and visual acuity postoperatively. In the present study also there was significant association between visual acuity pre operatively and post operatively in both the groups.

The results of the present study is similar to a meta-analysis by Gogate P et al comparing the efficacy and safety of MSICS and phacoemulsification which showed no significant endothelial cell loss between the two groups. A meta-analysis by Zang JY et al in 2013 also showed no statistically significant difference in endothelial cell loss between phacoemulsification and SICS.<sup>15</sup>

The limitations of the study was that only one technique of phacoemulsification (divide and conquer) was compared, results may differ with other techniques. Another limitation was that only cell density was taken for the present study and the endothelial cell morphology was not analysed. Also the follow up was short term. In the present study the OVD that was used was only Hydroxy Propyl Methyl Cellulose 2% and Sodium hyaluronate 1.4% also known as Healon GV was not used to protect the corneal endothelium.

## 6. Conclusion

The greatest challenge in our field is a large backlog of cataract blindness in developing countries. MSICS and phacoemulsification are the two commonly performed cataract surgeries. Significant endothelial cell loss following cataract surgery can lead to corneal decompensation and loss of corneal transparency and hence affect the vision. Thus protection of corneal endothelium is very much necessary for achieving good visual outcome after a cataract surgery.

In the present study majority of the patients undergoing cataract surgery were in the age group of 60-69 years. The endothelial cell loss was comparable among males and females in both the groups. There was no statistically significant endothelial cell loss between the two groups (MSICS and phacoemulsification). Thus both the surgical techniques were safe to corneal endothelium.

Since MSICS is less dependent on technology, economical and has easy learning curve, it could be a cost effective alternative to phacoemulsification in developing countries.

## 7. Conflict of Interest

The authors have stated explicitly that there are no conflicts of interest in connection with this article.

## 8. Source of Funding

None

## References

1. Cornea BB. Kanski'S Clinical Ophthalmology- A Systematic Approach. 8th Edn. Elsevier. 2016;168.
2. Edelhauser HF, The. Balance between Corneal Transparency and Edema The Proctor Lecture. *Invest Ophthalmol Vis Sci.* 2006;47(5):1755–67.
3. Benetz BA, Yee R, Bidros M. *Mannis, Holland Cornea.* 2011;180.
4. Ganekal S, Nagarajappa A. Comparison of morphological and functional endothelial cell changes after cataract surgery: phacoemulsification versus manual small-incision cataract surgery. *Middle East Afr J Ophthalmol.* 2014;21(1):56–60.
5. Kraff MC, Sanders DR, Lieberman HL. Specular microscopy in cataract and intraocular lens patients. A report of 564 patients. *Arch Ophthalmol.* 1980;98(10):1782–4. doi:10.1001/archoph.1980.01020040634009.
6. Bourne RR. Effect of cataract surgery on the corneal endothelium; modern phacoemulsification compared with extracapsular cataract surgery. *Ophthalmology.* 2004;111(4):679–85. doi:10.1016/j.ophtha.2003.07.015.
7. George R, Rupauliha P, Sripriya AV, Rajesh PS, Vahan PV, Praveen S, et al. Comparison of endothelial cell loss and surgically induced astigmatism following conventional extracapsular cataract surgery, manual small-incision surgery and phacoemulsification. *Ophthalmic Epidemiol.* 2005;12(5):293–7. doi:10.1080/09286580591005778.
8. Elvira JC, Hueso JR, Martínez-Toldos J, Mengual E, Artola A. Induced endothelial cell loss in phacoemulsification using topical anaesthesia plus intracameral lidocaine. *J Cataract Refract Surg.* 1999;25(5):640–2. doi:10.1016/s0886-3350(99)00008-5.
9. Bourne RR, Minassian DC, Dart JK, Rosen P, Kaushal S, Wingate N, et al. Effect of cataract surgery on the corneal endothelium: Modern phacoemulsification compared with extracapsular cataract surgery. *Ophthalmology.* 2004;111(4):679–85. doi:10.1016/j.ophtha.2003.07.015.
10. George R, Rupauliha P, Sripriya AV, Rajesh PS, Vahan PV, Praveen S, et al. Comparison of endothelial cell loss and surgically induced astigmatism following conventional extracapsular cataract surgery, manual small-incision surgery and phacoemulsification. *Ophthalmic Epidemiol.* 2005;12(5):293–7. doi:10.1080/09286580591005778.
11. Jagani SN, Lune AA, Magdum RM, Shah AP, Singh M, Datta D, et al. Comparison of endothelial cell loss by specular microscopy between phacoemulsification and manual small-incision cataract surgery. *Niger J Ophthalmol.* 2015;23(2):54–9. doi:10.4103/0189-9171.170991.
12. Balan R. A comparative study of endothelial cell loss in small-incision cataract surgery and phacoemulsification. *Kerala J Ophthalmol.* 2012;24:63–5.
13. Beltrame G, Salvetat ML, Driussi G, Chizzolini M. Effect of incision size and site on corneal endothelial changes in cataract surgery. *J Cataract Refract Surg.* 2002;28(1):118–25. doi:10.1016/s0886-3350(01)00983-x.
14. Jiang T, Jiang J, Zhou Y, Zhao GQ, Li H, Zhao SY, et al. Cataract surgery in aged patients: phacoemulsification or small-incision extracapsular cataract surgery. *Int J Ophthalmol.* 2011;4(5):513–8.
15. Zang JY, Feng YF, Cai JQ. Phacoemulsification versus manual small-incision cataract surgery for age related cataract: meta-analysis of randomized controlled trials. *Clin Experiment Ophthalmol.* 2013;41(4):379–86.

## Author biography

**Radhika Srinivasagupta Mohan**, Senior Resident

**Sanjana Marijogaiah Singasandra**, Assistant Professor

**Dakshayini Mallaiah**, Professor

**Shwetha Bennavara Venkataswamy**, Assistant Professor

**Cite this article:** Mohan RS, Singasandra SM, Mallaiah D, Venkataswamy SB. A comparative study of endothelial cell loss in small incision cataract surgery versus phacoemulsification cataract surgery by using specular microscope at tertiary care ophthalmic centre in Bengaluru, Karnataka. *IP Int J Ocul Oncol Oculoplasty* 20121;7(4):399-405.