

Content available at: <https://www.ipinnovative.com/open-access-journals>

IP International Journal of Ocular Oncology and Oculoplasty

Journal homepage: <https://ijooo.org/>

Original Research Article

Etiology, management of ptosis in working age group and its surgical outcome – A prospective study

R Malarvizhi¹, Anuradha A^{2,*}, Nikkitha K¹, Niranjan Karthik¹¹Dept. of Squint, Neuro-ophthalmology and Pediatric Ophthalmology, RIO GOH, Chennai, Tamil Nadu, India²Dept. of Ophthalmology, Madurai Medical College, Madurai, Tamil Nadu, India

ARTICLE INFO

Article history:

Received 31-07-2021

Accepted 25-08-2021

Available online 25-10-2021

Keywords:

Ptosis

Surgical Outcomes

Congenital Ptosis

Ptosis etiology

Management modalities

ABSTRACT

Aim: To study the etiology of ptosis among 20 - 50 years of age and analyse the management and surgical outcomes of various types of ptosis using different surgical modalities.

Materials and Methods: This prospective study was conducted at Tertiary Eye Care centre in Chennai from July 2018 - June 2019. It included all patients with ptosis between the age of 20 - 50 years after excluding vascular malformations and malignant tumours of the lid. Here all variables are described with frequency distribution and displayed using percentage.

Results: Incidence of congenital ptosis was 11 cases (37%), aponeurotic ptosis 8 cases (26%), myogenic ptosis 4 cases (13%), neurogenic ptosis 3 cases (10%), mechanical ptosis. 2 cases (7%), post traumatic ptosis 2 cases (7%). 70% were males and the remaining 30% were females. Among 30 cases, 23 patients had unilateral and 7 patients had bilateral ptosis. Moderate ptosis (3-4mm) (46.7%) formed a major composition of our study shortly followed by severe ptosis (43.3%). Out of 30 cases, 9 cases were managed medically (30%) and surgical intervention was required in 21 cases (70%). Out of 7 bilateral ptosis, 2 cases were managed medically and 5 cases needed surgical intervention. Complications following frontalis sling were under correction (27.3%) in 3 cases followed by mild corneal exposure keratitis (9.1%) in one patient. Complications following levator advancement were under correction in one case (12.5%) and mild lid peaking in one case (12.5%). Among 2 cases of mechanical ptosis, one was squamous papilloma and other was a large chalazion. Out of 4 myogenic cases 3 cases were due to myasthenia and the other diagnosed to have CPEO. 2 cases of traumatic ptosis were due to traumatic 3rd nerve palsy and traumatic levator dehiscence.

Conclusion: The most common acquired ptosis was aponeurotic followed by myogenic, neurogenic, traumatic and mechanical ptosis. Frontalis sling surgery is the most common surgery done for congenital ptosis. Use of polypropylene as a suspensory material gives a good functional outcome. Aponeurotic advancement surgery is the most common surgery performed for acquired ptosis.

This is an Open Access (OA) journal, and articles are distributed under the terms of the [Creative Commons Attribution-NonCommercial-ShareAlike 4.0 License](https://creativecommons.org/licenses/by-nc-sa/4.0/), which allows others to remix, tweak, and build upon the work non-commercially, as long as appropriate credit is given and the new creations are licensed under the identical terms.

For reprints contact: reprint@ipinnovative.com

1. Introduction:

Ptosis surgery is one of the challenging surgeries for oculoplastic surgeons. Its primary goal is to recreate the nearly perfect position of eyelids and create lid crease. Special attention is also given to the symmetry and contour

of eyelids. The consequences of ptosis surgery should be explained in detail to the patients. The lid level can be changed but dynamic limitations of the affected muscle persist post operatively and can result in lid lag or lagophthalmos. The timing of surgery is a crucial factor. In case of congenital ptosis, most surgeons agree that it should be corrected prior to age of 5. If there is risk of amblyopia then it should be treated urgently with surgical

* Corresponding author.

E-mail address: dranusunder@yahoo.com (Anuradha A).

correction of ptosis and management of amblyopia. In case of acquired ptosis, surgery is often recommended when the patients' daily activities are compromised due to occlusion of visual axis or superior field is completely lost or there is extreme fatigability while reading. Mild congenital ptosis can be observed with periodic follow up if there are no signs of strabismus, amblyopia and abnormal head posture is present. In myasthenia gravis the first line of management is with cholinesterase inhibitors, immunosuppressive agents and steroids. Crutch glasses can be used for ptosis. In refractory cases under correction of ptosis can be done.

The choice of surgery depends on the severity of ptosis and the levator muscle function (Figure 1).

Complications of ptosis surgery include infection, bleeding, over or under correction, lid lag or lagophthalmos, exposure keratitis, ectropion, entropion, loss of eyelid lashes, lid crease abnormalities and conjunctival prolapse. Although improvement in lid height is usually achieved, the eyelids may not be perfectly symmetrical. In some cases, like congenital ptosis with jaw winking phenomenon, levator disinsertion with frontalis suspension may be required. In this study, patients belonging to a particular age group (20-50 years) were taken and analysed its most common etiology and management, whether medical or surgical. If surgical then its outcome and complications were analysed.

2. Materials and Methods

Ethical clearance was obtained from the Institutional Ethical Committee for conducting the study. 30 patients who presented to Orbit and Oculoplasty services in a tertiary eye hospital with ptosis between 20 - 50 years of age, after excluding those with vascular malformations and tumors of the eyelids, were registered, evaluated and followed up.

Patients were evaluated after a detailed history taking and complete general and ocular examination. Ocular examination included visual acuity testing, anterior segment evaluation, ptosis evaluation and posterior segment evaluation. Ptosis evaluation includes examination of Head Posture, Vertical Palpebral Height, Margin Reflex Distance, Lid Crease Level, Levator Palpebrae Superioris Action, Bell's Phenomenon, Marcus Gunn Jaw Winking Phenomenon, Ice Pack Test, Fatiguability Test, Strabismus Evaluation and Extra Ocular Movements.

Based on clinical examination a probable diagnosis was arrived at and further investigations were done. Patients were referred to other departments like neurology department whenever indicated. Patients were treated accordingly and if managed surgically, the outcome of the surgery was also assessed. Pre- and post-operative photographs were taken and documented for comparing the outcome of surgery. Surgery was decided depending on the type of ptosis, amount of levator function, margin limbal distance and degree of ptosis. In our study out of

30 cases, simple congenital ptosis comprised of 11 cases with poor levator function ($< 4\text{mm}$). All 8 aponeurotic ptosis had good levator function with intact Bells phenomenon hence they underwent levator advancement surgery through transcutaneous (external) approach. Two cases of mechanical ptosis, one case excision biopsy was done and sent for histopathological examination. One case suspected to be a papilloma, excision biopsy was done and sent for histopathological examination which confirmed the same and in the other case of chalazion, incision and curettage was done.

In four cases of myogenic ptosis, 3 had Myasthenia Gravis with positive icepack, fatiguability test and anti Ach receptor antibodies tests and they were managed medically by acetylcholine-esterase inhibitors. One patient with CPEO was managed with crutch glasses. In three cases of neurogenic ptosis due to 3rd nerve palsy one was due to leptomeningeal carcinomatosis and was on chemotherapy, another was due to posterior communicating artery aneurysm which was managed by aneurysmal clipping in neurosurgery department, third case was due to Horner's syndrome and was evaluated for underlying cause. In two cases of traumatic ptosis, one case was due to traumatic 3rd nerve palsy with traumatic optic neuropathy and other was due to traumatic levator dehiscence with mild ptosis and both were managed conservatively.

Post-operative evaluation was done for all surgically operated cases on first and fifth post-operative day and monthly follow up for 2nd and 6th month. The need for follow up is to look for incidence of complications like under correction, failure and success of surgeries.

3. Results

Total number of ptosis cases reported at tertiary eye care centre during the study period July 2018 - June 2019 were 90 which included all age groups. The incidence of ptosis was the most in age group less than 20 years followed by 20-50 years and then above 50 years. Among 90 cases, 33% of cases were between 20 - 50 years and were included in the study.²³⁾

These 20-29 year group of young patients had congenital ptosis and approached the hospital for cosmetic reason and aponeurotic ptosis incidence was more after 30 years. Of the reported ptosis cases between 20 - 50 years of age in this study, 70% were males and the remaining 30% were female. In this study there was a male predominance.

Among 30 cases, 23 patients had unilateral ptosis while 7 patients had bilateral ptosis. Right eye was involved in 13 cases, left eye in 10 cases and both eyes in 7 cases. Unilateral ptosis was more common than bilateral ptosis and predominance of right eye was seen in this study. Mild degree of ptosis (1-2mm) was found in 3 cases (10%), whereas moderate ptosis (3mm) in 14 cases (46.7%) and severe ptosis ($>4\text{mm}$) in 13 cases (43.3%). Hence moderate

ptosis (46.7%) formed a major composition of our study, shortly followed by severe ptosis (43.3%) followed by mild ptosis (10%). (Figure 4)

Out of 30 cases in our study group, 9 cases were managed medically (30%) and surgical intervention was required in 21 cases (70%). In case of 7 bilateral ptosis cases were managed medically and 5 cases needed surgical intervention. Among those operated, 1 case had been operated on both eyes while remaining 4 cases had only one eye operated (as patients preferred one eye followed by the other). Among 30 patients, 21 patients underwent surgery for ptosis correction. All surgeries were done under local anaesthesia.

Congenital, aponeurotic and mechanical ptosis were treated surgically while myogenic, neurogenic and post-traumatic ptosis were managed medically. Frontalis sling was done for 11 patients of congenital ptosis with poor levator function. Frontalis sling was done with Fasanella Servat technique and it gave good results (Figure 5). In our study we used 4'0 prolene as suspensory material. Evmercilene mesh and silicon slings can also be used. Even though bilateral frontalis sling is preferred since it has more symmetrical results on down gaze, only the affected eye was operated in this study.

The major complications that were encountered during follow up were under correction (27.3%) in 3 cases followed by mild corneal exposure keratitis (9.1%) in one patient which was managed medically by lubricants. Levator Aponeurotic advancement surgery was done for 8 patients with aponeurotic ptosis with good levator function of which 5 were male and 3 were female. The technique that was used was transcutaneous approach. Careful attention was given to eyelid crease and intraoperative adjustment was made by comparing with the other eye lid position. 3 suture technique was used in all cases. Complication encountered during the procedure is under-correction in one case (12.5%) and mild lid peaking in one case (12.5%) (Figure 6).

There were 2 cases of which excision biopsy was done for one patient which on histopathological examination confirmed to be squamous papilloma and other was chalazion induced mechanical ptosis for which chalazial incision and curettage was done.

In our study we had 3 cases of neurogenic ptosis, first case was due to leptomeningeal carcinomatosis infiltrating the 3rd nerve and the patient is on chemotherapy and other case was due to posterior communicating artery aneurysm for which aneurysmal clipping was done in neurosurgery department. Last case was due to Horner's syndrome and the patient was evaluated to rule out the underlying etiology.

Out of 4 myogenic cases 3 cases turned out to be myasthenia with positive ice pack and fatigability test and anti-acetylcholine receptor antibody positivity and was managed medically by acetylcholinesterase inhibitors. Other case was diagnosed to have CPEO and was prescribed

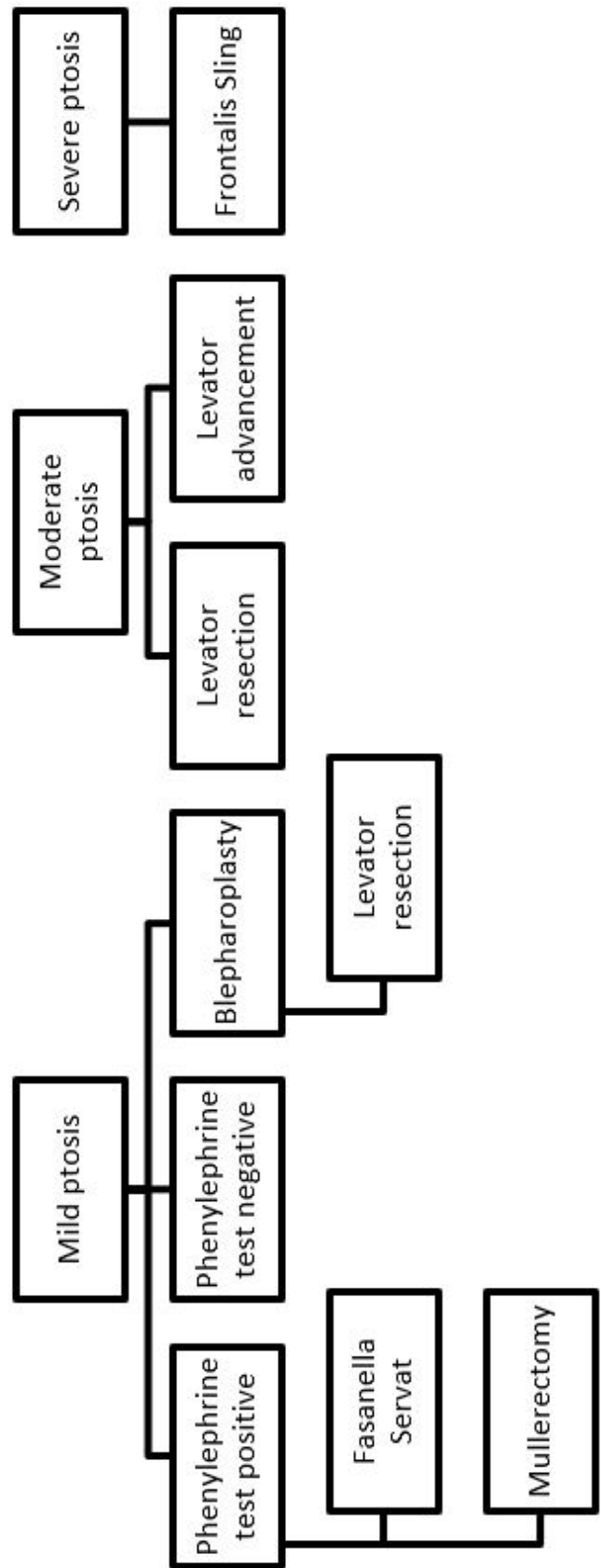


Fig. 1:

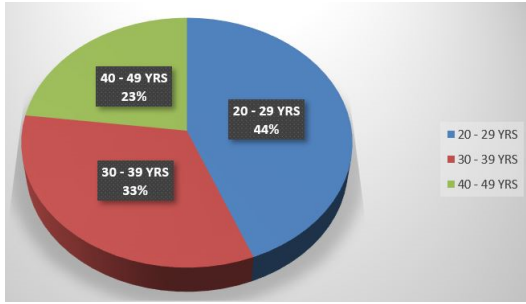


Fig. 2:

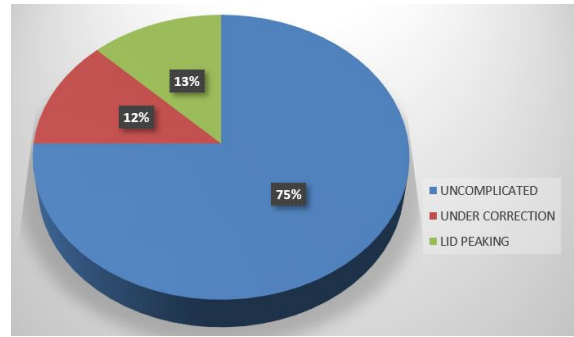


Fig. 6:

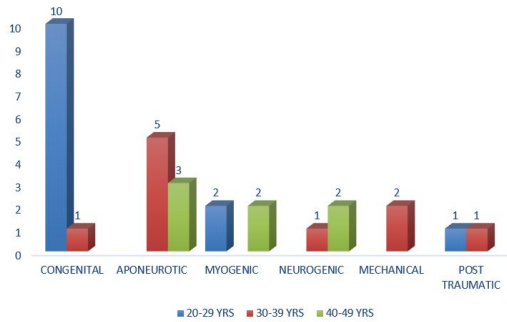


Fig. 3:

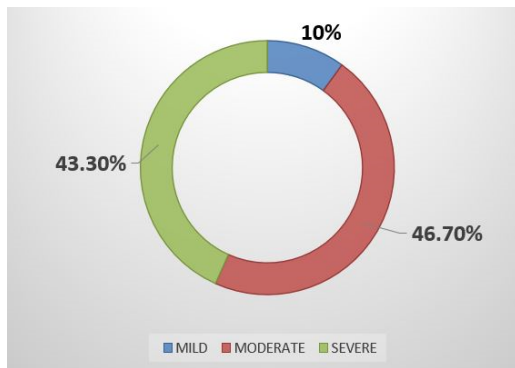


Fig. 4:

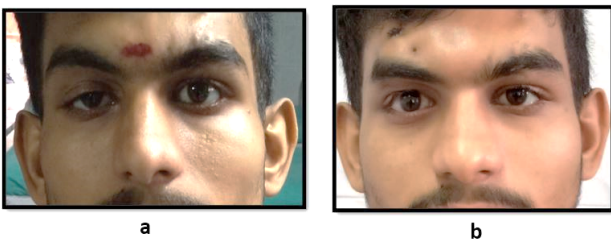

Fig. 5:

crutch glasses.

There were 2 cases of traumatic ptosis, one was due to traumatic 3rd nerve palsy with traumatic optic neuropathy and the patient was started on IV methylprednisolone 500mg BD for 3 days followed by oral prednisolone 1mg/kg body weight. Other patient had mild traumatic ptosis due to levator dehiscence which was managed conservatively improved by 6 months.

4. Discussion

Kersten et al¹ in 1995 did a study on 91 patients of 15-50 years of age regarding causes of acquired ptosis and found that rigid contact lens wear was the most common cause due to levator aponeurosis dehiscence followed by trauma. Rasiah et al² did a retrospective cohort study on 266 young adults with acquired ptosis and found that the most common cause were trauma related followed by enophthalmic blepharoptosis. Jeffrey et al³ in 2013 conducted a study on congenital ptosis and found its syndromic associations, genetic factors and surgical procedure. The choice of procedure depends on patient specific factors like degree of ptosis, levator function, surgeon preference and resource availability. Simon et al⁴ did a study on different surgical designs and suture materials used in frontalis sling surgery and found that single loop and double pentagon design had same success. Nylon suture had better cosmetic outcome and poly-tetra-fluoro-ethylene had lowest recurrence rate. Benia et al⁵ did a retrospective study on 1500 cases of ptosis and found that simple congenital ptosis as the most common cause and the most common surgery was levator resection. McCulley et al⁶ in an article did a retrospective case cohort study on results of aponeurotic advancement surgery in aponeurotic ptosis with transcutaneous approach and found that 77% cases had ideal results and remaining 23% had under correction. Baroody et al⁷ in 2004 studied advances in evaluation and treatment of ptosis and found that frontalis suspension surgery is the most commonly performed surgery and frontalis advancement flap can also be used in congenital ptosis. Advancement of levator aponeurosis can be performed by

minimally invasive small incision approach. Wong et al⁸ in 2000 did a retrospective non comparative interventional case series in 28 patients with myogenic ptosis and found that the most common cause was chronic progressive external ophthalmoplegia and most common ocular finding other than ptosis was pigmentary retinopathy. The most common systemic finding was dysphagia. About 20% of patient were treated surgically by frontalis suspension only after visual axis got obscured. Satchi et al⁹ in 2014 did a study on isolated neurogenic ptosis due to neuropraxic injury to nerve supplying levator palpebrae superioris and found that all cases recovered in less than 6 months duration. Hence in case of isolated neurogenic ptosis it was found to observe up to 6 months for spontaneous recovery and if unsuccessful then surgical intervention can be advised. Ahn et al¹⁰ did a prospective study on clinical observation and surgical results of 67 cases of blepharoptosis and found that majority of patients (70%) were operated in second and third decade which was in correlation with our study and the most common ptosis was simple congenital ptosis and most common surgery was levator resection through transcutaneous approach. Lee et al¹¹ studied demographic patterns of blepharoptosis and found that in 2328 patients, 1815 (78%) had simple congenital ptosis and 512 (22%) had acquired ptosis. Of congenital ptosis most had poor levator function (60.1%). Frontalis suspension was the most common surgery done which had results similar to our study. Lim et al¹² did a retrospective study in 251 patients and found that aponeurotic ptosis (60.2%) was the most common type followed by traumatic ptosis (11.2%). Of neurogenic and myogenic ptosis 3rd nerve palsy was most common followed by myasthenia and chronic progressive external ophthalmoplegia whose results were similar to our study. Thapa et al¹³ did a descriptive cross-sectional study in 125 patients and found that congenital ptosis was more common than acquired ptosis whose results were similar to our study. But in acquired ptosis trauma (32%) was the most common cause followed by neurogenic (25.5%) ptosis but in our study aponeurotic was the most common cause followed by myogenic ptosis. Gautam et al¹⁴ did a retrospective study in 326 patients and found that congenital ptosis was present with early mean age being 23(SD+/- 9.9) and acquired ptosis with late mean age 35 (SD +/- 14). Unilateral ptosis (87%) was most common which was in correlation with our study. Among those acquired, myogenic ptosis was the most common cause. Clauser et al¹⁵ did a study on 42 patients of which 12 were congenital and 30 were acquired. The most common procedure performed was levator resection and frontalis suspension surgery. Moderate (49.2%) and severe (43.6%) ptosis were the most common type followed by mild (7%) ptosis whose results were similar to our study where moderate ptosis was the most common type followed by severe and then mild ptosis. Kim et al¹⁶ found that congenital ptosis (86%) was most common followed

by acquired ptosis (14%) and the results were similar to our study. Of acquired ptosis mechanical (35.9%) was most common followed by traumatic ptosis (23.1%) in comparison to our study which had aponeurotic ptosis as the most common cause. Severe ptosis (72%) was most common whereas in our study moderate ptosis was most common.

5. Conclusion

Among the middle age group, incidence of ptosis was found to be more common in the age group of 20 - 29 indicating the patients need for cosmetic surgical correction in this group. Congenital ptosis and aponeurotic ptosis account for the majority of ptosis between 20 - 50 years of age. The incidence of congenital ptosis was more in age group 20s while aponeurotic was above 35 years of age indicating etiopathological significance. The most common acquired ptosis was aponeurotic followed by myogenic, neurogenic, traumatic and mechanical ptosis. Surgery forms the main treatment of choice. Frontalis suspension is the most common surgery done for congenital ptosis. Use of polypropylene as a suspensory material gives a good functional outcome. Other materials like fascia lata, silicon and mercilene mesh can also be considered. Aponeurotic advancement is the most common procedure done for acquired ptosis.

6. Conflict of Interest

The authors declare that there are no conflicts of interest in this paper.

7. Source of Funding

None.

References

1. Kersten RC, Conciliis CD, Kulwin DR. Acquired Ptosis in the Young and Middle-aged Adult Population. *Ophthalmology*. 1995;102(6):924–8.
2. Rasiah S, Hardy TG, Elder JE, Ng CY, Lenake M, McNab AA, et al. Aetiology of acquired blepharoptosis in young adults. *Orbit*. 2018;37(1):59–64.
3. Soohoo JR, Davies BW, Allard FD, Durairaj VD. Congenital ptosis. *Survey Ophthalmol*. 2014;59(5):483–92.
4. Simon GJB, Macedo AA, Schwarcz RM, Wang DY, Mccann JD, Goldberg RA, et al. Frontalis Suspension for Upper Eyelid Ptosis: Evaluation of Different Surgical Designs and Suture Material. *Am J Ophthalmol*. 2005;140(5):877–85.
5. Benia L. A retrospective study of 1,500 personal cases of ptosis. *J Fr Ophthalmol*. 1999;22(5):541–4.
6. Mcculley TJ, Kersten RC, Kulwin DR, Feuer WJ. Outcome and influencing factors of external levator palpebrae superioris aponeurosis advancement for blepharoptosis. *Ophthalmic Plast Reconstr Surg*. 2003;19(5):388–93.
7. Baroody M, Holds JB, Vick VL. Advances in the diagnosis and treatment of ptosis. *Curr Opin Ophthalmol*. 2005;16(6):351–5.
8. Wong VA, Beckingsale PS, Oley CA, Sullivan TJ. Management of myogenic ptosis. *Ophthalmology*. 2002;109(5):1023–31.

9. Satchi K, Kumar A, Mcnab AA. Isolated traumatic neurogenic ptosis with delayed recovery. *Ophthalmic Plast Reconstr Surg*. 2014;30(1):57–66. doi:10.1097/IOP.000000000000010.
10. Ahn YS, Lee TS. Clinical Observation and Their Surgical Results of 67 Cases of Blepharoptosis. *J Korean Ophthalmol Soc*. 1979;20(3):283–90.
11. Lee YG, Son BJ, Lee KH, Lee SY, Kim CY. Clinical and Demographic Characteristics of Blepharoptosis in Korea: A 24-year Experience including 2,328 Patients. *Korean J Ophthalmol*. 2018;32(4):249–56. doi:10.3341/kjo.2017.0118.
12. Lim JM, Hou JH, Singa RM, Aakalu VK, Setabutr P. Relative Incidence of Blepharoptosis Subtypes in an Oculoplastics Practice at a Tertiary Care Center. *Orbit*. 2013;32(4):231–4.
13. Thapa R, Karmacharya PC, Nepal BP. Etiological pattern of blepharoptosis among patients presenting in teaching hospital. *JNMA J Nepal Med Assoc*. 2006;45(162):218–22.
14. Gautam P, Adhikari R, Sharma BR. Etiopathogenetic patterns of blepharoptosis in Western Nepal : an Overview. *Nep J Oph*. 2016;8(1):36–40.
15. Clauser L, Tieghi R, Galiè M. Palpebral ptosis: clinical classification, differential diagnosis, and surgical guidelines: an overview. *J Craniofac Surg*. 2006;17(2):246–54.
16. Kim SY, Chung WS. Analysis of the Causes of Ptosis. *J Korean Ophthalmol Soc*. 1995;36(10):1649–54.

Author biography

R Malarvizhi, Professor

Anuradha A, Associate Professor

Nikkitha K, Former Post Graduate

Niranjan Karthik, Junior Resident

Cite this article: Malarvizhi R, Anuradha A, Nikkitha K, Karthik N. Etiology, management of ptosis in working age group and its surgical outcome – A prospective study. *IP Int J Ocul Oncol Oculoplasty* 2021;7(3):273-278.