



Content available at: <https://www.ipinnovative.com/open-access-journals>

IP International Journal of Ocular Oncology and  
Oculoplasty

Journal homepage: <https://ijooo.org/>



## Original Research Article

# Treatment of cystoid macular edema in a patient with primary open angle glaucoma and diabetic retinopathy by withdrawal of travoprost

BN Kalpana<sup>1</sup>, Shiv Sagar N<sup>1,\*</sup>, Shilpa YD<sup>1</sup>

<sup>1</sup>Dept. of Ophthalmology, PES Medical College, Bengaluru, Karnataka, India



### ARTICLE INFO

#### Article history:

Received 05-02-2021

Accepted 10-02-2021

Available online 24-07-2021

#### Keywords:

CME

Diabetic Retinopathy

Travoprost

### ABSTRACT

**Purpose:** To study the association of cystoid macular edema (CME) and Travoprost eye drops in a patient with diabetic retinopathy (DR).

**Materials and Methods:** The study was carried out on a 65yr old patient on a regular follow up from 2009-2018.

**Results:** A 65yr old patient of a DR of both eyes who had received 3 sittings of pan retinal photocoagulation (PRP) laser in both eyes and grid laser to his right eye. He was on regular follow up since 2009 with a stable proliferative diabetic retinopathy (PDR). Patient was also on topical antiglaucoma medication and had prophylactic YAG-PI done both eyes. He was on regular follow up since 2009 with a stable proliferative diabetic retinopathy (PDR). Right eye showed macular edema (ME) in 2014 and underwent OCT and FFA. Patient refused for intravitreal injection and preferred laser treatment, so patient underwent micropulse laser treatment in 2014. His edema persisted even after micropulse treatment. His systemic control was good and patient continued to use Travoprost eye drops. So in 2017 suspected CME secondary to topical prostaglandin (PG) analogue as he had strict glycemic control and was no fluctuation in ME. Hence topical PG analogue was withdrawn and stopped. On subsequent follow up after 2 months CME had completely disappeared and the foveal contour returned to normal on OCT. LE was status quo. Patient was followed up for more than 1 year and continuously followed up, 15 days back in June 2018 had no evidence of CME and vision was 6/9 in both eyes.

**Conclusions:** Differentiation of DME and CME secondary to PG analogue should be made at the earliest.

© This is an open access article distributed under the terms of the Creative Commons Attribution License (<https://creativecommons.org/licenses/by/4.0/>) which permits unrestricted use, distribution, and reproduction in any medium, provided the original author and source are credited.

## 1. Introduction

Cystoid macular edema (CME) is a serious complication of intraocular surgery, which results in transient or even permanent vision loss. Despite advances in cataract surgery, such as microincision and new phacoemulsification techniques, CME may occur even in uncomplicated surgeries.<sup>1</sup> The incidence of acute, visually significant CME has been reported from 1% to 2% of patients following uncomplicated phacoemulsification.<sup>2,3</sup> In diabetic patients, macular edema is the main cause for low visual acuity.<sup>4</sup>

### 1.1. Pathogenesis and risk factors

CME is a painless condition in which swelling or thickening occurs of the central retina (macula) and is usually associated with blurred or distorted vision. The primary cause of CME depends on the underlying disease process, but most pathways eventually lead to vascular instability and breakdown of the blood-retinal barrier. The Muller cells in the retina become overwhelmed with fluid leading to their lysis. This results in an accumulation of fluid in the outer plexiform and inner nuclear layers of the retina.<sup>5</sup>

Endogenous prostaglandins (PGs) are known to modulate normal cell function as well as inflammatory response. The conventional route of aqueous humor flow is through the trabecular meshwork, Schlemm's canal and

\* Corresponding author.

E-mail address: [dr.ananthanag@gmail.com](mailto:dr.ananthanag@gmail.com) (S. Sagar N).

episcleral vessels. It is thought that PGs may regulate uveoscleral outflow by metalloproteinases- (MMP)-mediated alterations in the ciliary muscle in extracellular matrix metabolism.<sup>5</sup>

Incidence of CME increases with surgical complications. Prominent complications leading to CME are the posterior capsular rupture, vitreous loss, incarcerated vitreous in the incision, cortical remnants in the vitreous, trauma to the iris, intraocular lens dislocation, iris fixation or anterior layer intraocular lens and premature posterior capsulotomy.<sup>6,7</sup> Pre-existing retinal diseases such as retinal vein occlusion and vitreoretinal interface changes, such as the epiretinal membrane, pose a bigger risk of CME

### 1.2. Diagnosis

Clinical CME appears on average from 4 to 6 weeks after surgery. Most patients present with loss of visual acuity and macular thickening, which can be seen by posterior segment slit lamp examination.

Optical coherence tomography (OCT) use has been widespread and its sensitivity works well in detecting macular edema. This test can show hyporeflective lesions compatible with intraretinal fluid, loss of foveal depression and retinal thickening. OCT is also used to show other changes in the vitreoretinal interface, such as epiretinal membranes and lamellar holes, which may influence the prognosis.<sup>8,9</sup>

In particular, the prostaglandin analog class of medications, introduced in the mid 1990s with the advent of latanoprost (Xalatan), followed more recently by bimatoprost (Lumigan) and travoprost (Travatan and Travatan Z), have become ubiquitous in the management of glaucoma patients.<sup>10</sup>

Structurally, Latanoprost, Travoprost, and Bimatoprost are prostaglandin analogs (PGAs) or hypotensive lipids. Although the exact mechanism of action remains to be definitively elucidated, endogenous prostaglandins (PGs) are known to modulate normal cell function as well as inflammatory response. The conventional route of aqueous humor flow is through the trabecular meshwork, Schlemm's canal and episcleral vessels. It is thought that PGs may regulate uveoscleral outflow by metalloproteinases- (MMP)-mediated alterations in the ciliary muscle in extracellular matrix metabolism.<sup>10</sup> The possible adverse effects include cystoid macular edema (CME), exacerbations of anterior uveitis, and herpetic keratitis after cataract surgery as they act as inflammatory mediators.

Furthermore, many reports describe a rapid resolution of CME after cessation of prostaglandin analog therapy, especially with concomitant use of topical NSAIDs and steroids.<sup>11–13</sup>

## 2. Materials and Methods

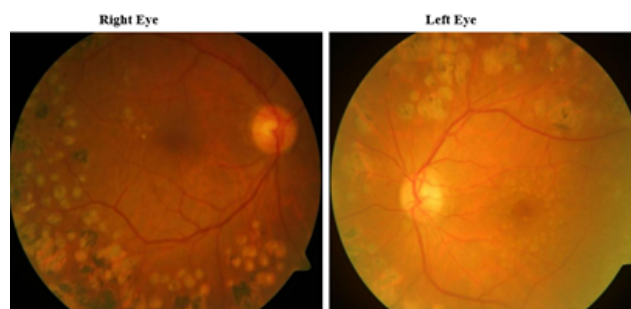
A retrospective study conducted on a known diabetic 65yr old male patient presented to us with diminution of vision in both eyes and was diagnosed as having Primary Open Angle Glaucoma (POAG) for which he was on topical 0.004% Travoprost eye drops. He also gave history of undergoing prophylactic ND-YAG iridotomy about 3 years ago.

On ocular examination he was found to be having proliferative diabetic retinopathy changes with macular edema in right eye for which he underwent treatment in the form of PRP and GRID laser in 2009. His systemic control was found to be good. Patient was followed up for next 8yrs which showed stable retina but persisting macular edema noticed, for which he underwent micropulsed laser treatment. Follow up of the patient showed minimal reduction of macular edema on OCT, and his systemic glycemetic control was good. He gave history of using Travoprost eye drops from past 5yrs for his PACG treatment.

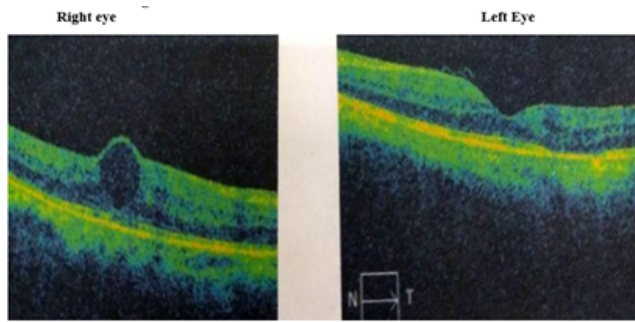
He was advised to discontinue the topical 0.004% travoprost eye drops in 2017 on consultation with glaucoma department, was replaced by 0.1% alphagan eye drops and followed up after 2 months, after doing OCT of the patient revealed no macular edema.

**Table 1:** Ocular examination

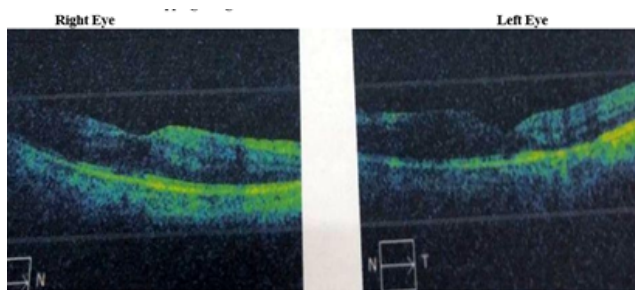
	Right eye	Left eye
<b>Eyelids</b>	Normal	Normal
<b>Conjunctiva</b>	Normal	Normal
<b>Cornea</b>	Clear	Clear
<b>Anterior chamber</b>	Shallow	Shallow
<b>Iris</b>	Normal colour pattern	Normal colour pattern
<b>Pupil</b>	RRR	RRR
<b>Lens</b>	Nuclear sclerosis-2	Nuclear sclerosis-2
<b>Vision</b>	6/12	6/12
<b>IOP</b>	20 mm Hg	20 mm Hg
<b>Gonioscopy</b>	Irido corneal contact	Irido corneal contact
<b>Fundus</b>	Disc appears normal, NVE noted, ME noted	Disc appears normal, NVD noted, ME noted



**Fig. 1:** Following PRP and Gridlaser



**Fig. 2:** OCT of RE and LE with anti-glaucoma medications



**Fig. 3:** OCT of RE and LE after stopping anti glaucoma medications

### 3. Discussion

CME is a painless condition in which swelling or thickening occurs of the central retina (macula) and is usually associated with blurred or distorted vision. The primary cause of CME depends on the underlying disease process, but most pathways eventually lead to vascular instability and breakdown of the blood-retinal barrier. The Muller cells in the retina "become overwhelmed with fluid leading to their lysis. This results in an accumulation of fluid in the outer plexiform and inner nuclear layers of the retina.

A 65yr old patient who presented to our department with diminished vision in both eyes. He was a known diabetic on treatment. On ophthalmological evaluation he was found to be having POAG was on treatment with Travoprost eye drops and bilateral PDR changes with macular edema noted. In our study, benzalkonium chloride-free travoprost appears to be the cause of the CME. No other eye drops were used during the treatment, and the patient had diabetic retinopathy that could have caused CME. His BCVA was 6/36 in both eyes. He underwent PRP, grid and micropulsed laser treatment for his diabetic retinopathy changes, but his macular edema persisted. Interestingly, our patient, who had been uneventfully treated with Travoprost, for about 3 years, developed cystoid macular edema that persisted over years.

Following withdrawal of the Travoprost eye drops, resolution of macular edema was noted in OCT and is

maintaining a vision of 6/9 in both eyes.

Watanabe et al reported CME cases that developed when latanoprost treatment was initiated after 3 years of treatment with preservative-containing unoprostone.<sup>14</sup> CME has similarly been reported when latanoprost was added to a drug regimen that already included several types of eye drops containing preservatives.<sup>15–17</sup> While preservatives may promote latanoprost-induced CME, the preservatives alone do not provide a sufficient explanation for the development of this condition. Esquenazi studied a case of CME induced by benzalkonium chloride-free travoprost.<sup>18</sup> According to study by Ayyala RS et al,<sup>11</sup> Callanan D et al,<sup>16</sup> CME can even appear several years after the surgery. Ohrloff C et al<sup>19</sup> says that in cases without the known risk factors for CME, the condition may develop because of temporary damage to the blood–aqueous barrier immediately after surgery. In cases involving known risk factors, the damage to the blood–aqueous barrier is protracted, resulting in the continuance of conditions that lead to CME in the long term.

### 4. Conclusion

A 65-year-old patient with diabetic retinopathy with good systemic control and primary open angle glaucoma (POAG) on treatment with Travoprost eye drops post iridotomy showed signs of macular edema on OCT. It was found that on withdrawal of the travoprost eye drops, it resulted in reduction of Cystoid macular edema (CME).

Hence differentiation of diabetic macular edema and cystoid macular edema secondary to Prostaglandin analogue has to be made at the earliest.

Moreover, the current findings suggest that the prostaglandin eye drops that potentially led to the CME can be resumed under careful observation.

Despite our decision to stop prostaglandin in our patient, there is no gold standard among clinicians on this issue, reflecting the absence of definitive evidence that prostaglandins really do cause CME and the association between ocular hypotensive lipids and cystoid macula edema continues to be subject of debate.

Although multiple case reports of individual prostaglandin analogues being suggested as the cause of CME, there is currently no consensus or recommendation regarding the use of these medications, there is a need to conduct similar studies on a larger scale for better prevention and management of cystoid macular edema (CME) among patients with diabetic retinopathy.

### 5. Source of Funding

None.

### 6. Conflicts of Interest

All contributing authors declare no conflict of interest.

## References

- Carricondo P, Abalem M, Machado C, Kara-Junior N. Prophylaxis and treatment of cystoid macular edema after cataract surgery. *Revista Brasileira de Oftalmologia*. 2015;74(2):113–8. doi:10.5935/0034-7280.20150026.
- Ray S, and DJD. Pseudophakic cystoid macular edema. *Semin Ophthalmol*. 2002;17(3-4):167–80.
- Henderson BA, Kim JY, Ament CS. Clinical pseudophakic cystoid macular edema. Risk factors for development and duration after treatment. *J Cataract Refract Surg*. 2007;33(9):1550–8.
- Maurya RP. Diabetic macular edema: An overview. *Ind J Clin Exp Ophthalmol*. 2019;5(1):1–2. doi:10.18231/2395-1451.2019.0026.
- Wiley HE, Ferris III FL. Nonproliferative Diabetic Retinopathy and Diabetic Macular Edema. In: *Retina (Fifth Edition)*. vol. 2. Elsevier; 2013. p. 940–68.
- Yonekawa Y, Kim IK. Pseudophakic cystoid macular edema. *Curr Opin Ophthalmol*. 2012;23(1):26–32. doi:10.1097/ico.0b013e32834cd5f8.
- Cohen SM, Davis A, Cukrowski C. Cystoid macular edema after pars plana vitrectomy for retained lens fragments. *J Cataract Refract Surg*. 2006;32(9):1521–6. doi:10.1016/j.jcrs.2006.04.019.
- Bonanomi MT, Nicoletti AG, Carricondo PC, Buzalaf F, Jr NKJ, Gomes AM, et al. Retinal thickness assessed by optical coherence tomography (OCT) in pseudophakic macular edema. *Arq Bras Oftalmol*. 2006;69(4):539–44. doi:10.1590/s0004-27492006000400015.
- Brar M, Yuson R, Kozak I, Mojana F, Cheng L, Bartsch D, et al. Correlation between morphologic features on spectral-domain optical coherence tomography and angiographic leakage patterns in macular edema. *Retina*. 2010;30(3):383–9. doi:10.1097/iae.0b013e3181cd4803.
- Hylton C, Robin AL. Update on prostaglandin analogs. *Curr Opin Ophthalmol*. 2003;14(2):65–9. doi:10.1097/00055735-200304000-00001.
- Ayyala RS, Cruz DA, Margo CE, Harman LE, Pautler SE, Misch DM, et al. Cystoid macular edema associated with latanoprost in aphakic and pseudophakic eyes. *Am J Ophthalmol*. 1998;126(4):602–4. doi:10.1016/s0002-9394(98)00127-5.
- Yeh PC, Ramanathan S. Latanoprost and clinically significant cystoid macular edema after uneventful phacoemulsification with intraocular lens implantation. *J Cataract Refract Surg*. 2002;28(10):1814–8. doi:10.1016/s0886-3350(02)01334-2.
- Schumer RA, Camras CB, Mandahl AK. Latanoprost and cystoid macular edema: is there a causal relation? *Curr Opin Ophthalmol*. 2000;11(2):94–100. doi:10.1097/00055735-200004000-00005.
- Watanabe K, Hayasaka S, Hayasaka Y, Nagaki Y, Watanabe K. Cystoid macular edema associated with latanoprost use in a pseudophakic eye with a history of surgical complications. *Jpn J Ophthalmol*. 2003;47(1):110–2.
- Moroi SE, Gottfredsdottir MS, Schteingart MT. Cystoid macular edema associated with latanoprost therapy in a case of patients with glaucoma and ocular hypertension. *Ophthalmology*. 1999;106(5):1024–9.
- Callanan D, Fellman RL, Savage JA. Latanoprost-associated cystoid macular edema. *Am J Ophthalmol*. 1998;126(1):134–5. doi:10.1016/s0002-9394(98)00082-8.
- Wand M, Gaudio AR, Shields BM. Latanoprost and cystoid macular edema in high-risk aphakic or pseudophakic eyes. *J Cataract Refract Surg*. 2001;27(9):1397–401. doi:10.1016/s0886-3350(01)00770-2.
- Esquenazi S. Cystoid Macular Edema in a Pseudophakic Patient After Switching from Latanoprost to BAK-free Travoprost. *J Ocul Pharmacol Ther*. 2007;23(6):567–70. doi:10.1089/jop.2007.0060.
- Ohrloff C, Schalnus R, Rothe R, Spitznas M. Role of the posterior capsule in the aqueous-vitreous barrier in aphakic and pseudophakic eyes. *J Cataract Refract Surg*. 1990;16(2):198–201. doi:10.1016/s0886-3350(13)80730-4.

## Author biography

**BN Kalpana**, Professor and HOD, Medical Superintendent and Chief of Vitreo-Retina

**Shiv Sagar N**, Senior Resident

**Shilpa YD**, Associate Professor

**Cite this article:** Kalpana BN, Sagar N S, Shilpa YD. Treatment of cystoid macular edema in a patient with primary open angle glaucoma and diabetic retinopathy by withdrawal of travoprost. *IP Int J Ocul Oncol Oculoplasty* 2021;7(2):180-183.