

Content available at: <https://www.ipinnovative.com/open-access-journals>

IP International Journal of Ocular Oncology and Oculoplasty

Journal homepage: <https://ijooo.org/>

## Case Report

# Combined subconjunctival pegylated (Peg) interferon alpha 2a injection and amniotic membrane graft for management of extensive conjunctival papillomatous neoplasia- A case report

Murtuza Nuruddin<sup>1,\*</sup>, Soma Rani Roy<sup>2</sup>, Fahmida Hoque<sup>2</sup>

<sup>1</sup>Chevron Eye Hospital and Research Centre, Chittagong, Bangladesh

<sup>2</sup>Chittagong Eye Infirmary and Training Complex, Chittagong, Bangladesh



### ARTICLE INFO

#### Article history:

Received 20-03-2021

Accepted 31-03-2021

Available online 28-04-2021

#### Keywords:

Conjunctival papilloma

Peginterferon

Amniotic membrane graft

### ABSTRACT

**Purpose:** To report the management of a case presented with recurrent extensive conjunctival papillomatous neoplasia.

**Case Report:** A 2 year old girl presented with left recurrent extensive conjunctival squamous papilloma being treated surgically thrice along with adjunctive cryotherapy and topical Mitomycin C (MMC). We managed the case with surgical excision again with adjunctive subconjunctival or sublesional pegylated (peg) interferon alpha 2a injection along with the whole surface amniotic membrane graft. The patient had upper canalicular papillomatous lesion which was also managed by surgical excision and subcanalicular peg-interferon alpha 2a injection. There was no recurrence in subsequent 3 months follow up.

**Conclusion:** Subconjunctival pegylated interferon alpha 2a injection and amniotic membrane graft may be a novel combined modality to manage extensive conjunctival squamous papillomatous neoplasia that may yield successful outcome.

© This is an open access article distributed under the terms of the Creative Commons Attribution License (<https://creativecommons.org/licenses/by/4.0/>) which permits unrestricted use, distribution, and reproduction in any medium, provided the original author and source are credited.

## 1. Introduction

In 1883, Critchett and Juler first reported a case of conjunctival papilloma in a 14-year-old girl.<sup>1</sup> Since then the management of conjunctival papilloma has been evolved with various treatment modalities. Surgical excision is the mainstay of treatment. Adjunct therapy including cryotherapy, topical and subconjunctival or intralesional interferon alpha 2b, topical MMC or 5 Fluorouracil has been described in various literatures.<sup>2-5</sup> Here we are presenting the use of pegylated (peg) interferon alpha 2a and amniotic membrane graft as adjunctive to the management of a recurrent case of extensive conjunctival papilloma involving unilateral upper and lower tarsal conjunctiva, inner canthus and upper canaliculus.

## 2. Case Report

A 2-year-old girl presented to orbit and oculoplasty clinic of Chittagong Eye Infirmary and Training Complex with recurrent left upper and lower lid lesion for 1 year which was progressively enlarging (Figure 1). Histopathologically, the lesion was diagnosed as squamous cell papilloma. The lesion was surgically excised on three occasions with adjunctive cryotherapy elsewhere. She also received 2 cycles of topical Mitomycin C.

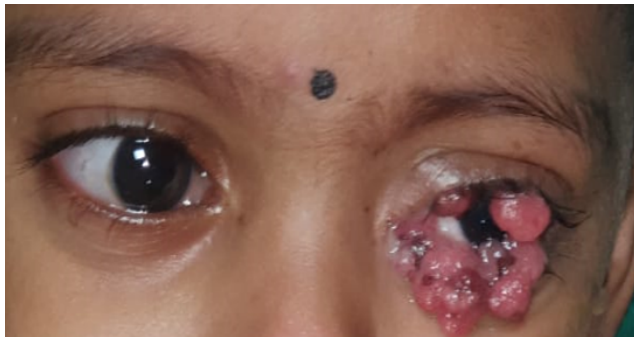On examination, there was extensive papillomatous lesion arising from left upper and lower palpebral conjunctiva as well as lesion at the caruncular region. Anterior and posterior segment findings were normal. No abnormal finding was detected in the other eye.

On 4<sup>th</sup> occasion, we excised the whole lesion again under general anesthesia with adjunctive use of sub-conjunctival peg Interferon alpha 2a injection (180mcg/0.5ml) along with ocular surface reconstruction

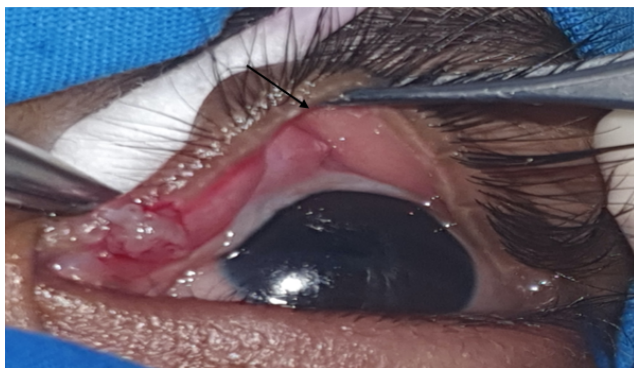
\* Corresponding author.

E-mail address: [murtuza.eyes@yahoo.com](mailto:murtuza.eyes@yahoo.com) (M. Nuruddin).

with amniotic membrane graft. The amniotic membrane covered the whole surface from upper eyelid margin to lower eyelid margin involving the fornices and sutured to medial and lateral canthus as well. There had been no recurrence for two months and then the patient presented with papillomatous growth projecting from the left upper canaliculi (Figure 2). No associated conjunctival lesion was noted. Lesion was explored and excised with curettage of canalicular wall. The canaliculi and nasolacrimal duct were probed and found patent to the nose. Sub-canalicular Injection of peg Interferon alpha 2a (0.2ml) was instilled and minimonka stent was inserted in the upper canaliculi and kept for 6 weeks. There had been no recurrence in subsequent three months follow up (Figure 3)



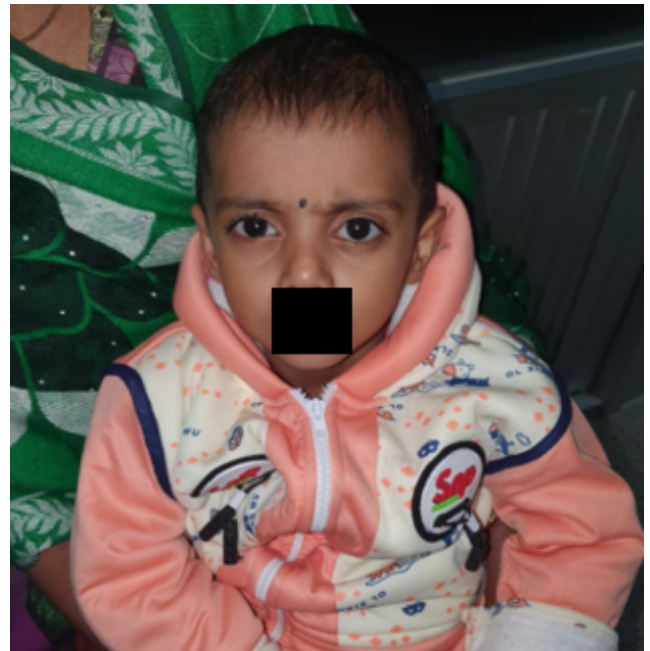**Fig. 1:** Extensive papillomatous lesion arising from left upper and lower palpebral conjunctiva and caruncle.



**Fig. 2:** Papillomatous lesion projecting through upper punctum

### 3. Discussion

Conjunctival papilloma is an acquired benign epithelial tumor of conjunctiva. There remains a strong association with human papilloma virus specially type 6, 11 and 16.<sup>6</sup> Depending on the size and site, the clinical presentation of conjunctival papilloma is variable. These lesions may be exophytic, endophytic or mixed. The exophytic variety is sessile or pedunculated, whereas the endophytic variety has the tendency to invade into the substantia propria of



**Fig. 3:** Post treatment photograph showing no recurrence of papillomatous lesion.

conjunctiva.<sup>7</sup> Our case was presented with an extensive exophytic variety having multiple pedunculated lesions arising from upper and lower tarsal conjunctiva and caruncle.

The mainstay of treatment for conjunctival papilloma is surgical excision, but surgical excision alone has higher recurrence.<sup>8</sup> Various adjunctive treatment modalities including double freeze-thaw cryotherapy, amniotic membrane graft, topical MMC, interferon alpha 2b, CO<sub>2</sub> laser, oral cimetidine etc have been reported with variable success rate.<sup>2-5,9-11</sup> Our case had undergone surgical excision along adjunctive cryotherapy and topical MMC, though this treatment regimen could not resist recurrence. The patient had undergone surgical excision thrice before presenting to us. We managed the patient with surgical excision along with subconjunctival peg interferon alpha 2a injection followed by ocular surface reconstruction (from upper lid margin to lower lid margin through fornices) with amniotic membrane graft.

The use of interferon alpha 2b for treatment of conjunctival papilloma has been described in various literature.<sup>3,4</sup> We have tried peg-interferon alpha 2a instead of interferon alpha 2b because of the ease of availability and cost. The only structural difference between interferon alpha 2a and interferon alpha 2b is in the amino acid sequences at position 23. (lysine in IFN $\alpha$ 2a, arginine in IFN $\alpha$ 2b).<sup>12</sup> The addition of “peg” (poly ethylene glycol) increases the half life. The another pharmacological difference between these two agents is that interferon alpha 2a is used at fixed dose whereas the dosage of interferon alpha 2b depends on

weight. However this difference in dosage is not practically applicable when the drug is used for management of Ocular surface neoplasia.

We have found only one article through medline search where interferon alpha 2a has been used for management of ocular surface squamous neoplasia (OSSN) whereas we have used pegylated interferon alpha 2a. Kim et al<sup>12</sup> have used interferon alpha 2a for management of one case of OSSN and two cases of conjunctival melanoma. They have used this agent for immunoreduction (reducing the size of lesion) followed by surgical excision. We have used pegylated interferon alpha 2a as immunopreventive (to prevent recurrence) along with surgical excision.

To the best of our knowledge, this is the first reported case where peg-interferon alpha 2a has been used for management of conjunctival squamous papilloma. The successful outcome in our case may be attributed to either subconjunctival peg interferon alpha 2a or ocular surface reconstruction by amniotic membrane graft or combined modality. A comparative study should be carried out to define the effectiveness of individual treatment modality. However, from our experience while managing this case, it can be emphasized that combined treatment modality including sublesional interferon injection and amniotic membrane graft can yield a successful outcome in such an extensive conjunctival papillomatous neoplasia.

#### 4. Source of Funding

No financial support was received for the work within this manuscript.

#### 5. Conflict of Interest

The authors declare they have no conflict of interest.

#### References

1. Ophthalmological Society. *Lancet*. 1883;122(3147):1090–3.
2. Omohundro JM, Elliott JH. Cryotherapy of Conjunctival Papilloma. *Arch Ophthalmol*. 1970;84(5):609–10. doi:10.1001/archophth.1970.00990040611009.

3. Morgenstern KE, Givan J, Wiley LA. Long-term administration of topical interferon alfa-2beta in the treatment of conjunctival squamous papilloma. *Arch Ophthalmol*. 2003;121:1052–3.
4. Falco LA, Gruosso PJ, Skolnick K, Bejar L. Topical interferon alpha 2 beta therapy in the management of conjunctival papilloma. *Optometry*. 2007;78(4):162–6. doi:10.1016/j.optm.2006.10.017.
5. Yuen HK, Yeung EF, Chan NR, Chi SC, Lam DS. The Use of Postoperative Topical Mitomycin C in the Treatment of Recurrent Conjunctival Papilloma. *Cornea*. 2002;21(8):838–9. doi:10.1097/00003226-200211000-00023.
6. Sjo NC, von Buchwald C, Cassonnet P, Norrild B, Prause JU, Vinding T, et al. Human papillomavirus in normal conjunctival tissue and in conjunctival papilloma: types and frequencies in a large series. *Br J Ophthalmol*. 2007;91(8):1014–5. doi:10.1136/bjo.2006.108811.
7. Sjö N, Heegaard S, Prause JU. Conjunctival papilloma. A histopathologically based retrospective study. *Acta Ophthalmol Scand*. 2000;78:663–6.
8. Huang YM, Huang YY, Yang HY, Tsai CC, Yu WK, Kao SC, et al. Conjunctival papilloma: Clinical features, outcome, and factors related to recurrence. *Taiwan J Ophthalmol*. 2018;8:15–23.
9. Schachat A, Iliff WJ, Kashima HK. Carbon Dioxide Laser Therapy of Recurrent Squamous Papilloma of the Conjunctiva. *Ophthalmic Surg*. 1982;13(11):916–8. doi:10.3928/1542-8877-19821101-05.
10. Jean B, Thiel HJ, Stumper K. CO2 laser vaporization of papilloma of the conjunctiva and eyelids. *Fortschr Ophthalmol*. 1989;86:672–5.
11. Chang SW, Huang ZL. Oral cimetidine adjuvant therapy for recalcitrant, diffuse conjunctival papillomatosis. *Cornea*. 2006;25:687–90.
12. Kim SE, Salvi SM. Immunoreduction of ocular surface tumours with intralesional interferon alpha-2a. *Eye*. 2018;32:460–2. doi:10.1038/eye.2017.196.

#### Author biography

**Murtuza Nuruddin**, Director Academics and Consultant Ophthalmologist

**Soma Rani Roy**, Associate Consultant

**Fahmida Hoque**, Assistant Surgeon

**Cite this article:** Nuruddin M, Roy SR, Hoque F. Combined subconjunctival pegylated (Peg) interferon alpha 2a injection and amniotic membrane graft for management of extensive conjunctival papillomatous neoplasia- A case report. *IP Int J Ocul Oncol Oculoplasty* 2021;7(1):94-96.