



Case Report

A deviant behaviour of squamous cell carcinoma of eyelid: Rare case report

Monalisa Deori^{1,*}, Arup Deuri¹

¹Dept. of Ophthalmology, Assam Medical College, Dibrugarh, Assam, India



ARTICLE INFO

Article history:

Received 10-01-2021

Accepted 18-01-2021

Available online 23-01-2021

Keywords:

Squamous Cell Carcinoma (SCC)

Blepharitis

Incisional biopsy

Cutlerbeard technique

ABSTRACT

Squamous cell carcinoma (SCC) is a malignant tumour of the squamous cell layer of the epidermis accounting for about 9.2% of all eyelid malignancies. We report a case of a 45 year old female patient presented with itching, sticky discharge and swelling over the right upper eyelid (RUL) for 20 days. Initially, it was diagnosed as a case of blepharitis of Right Eye and antibiotic eye ointment and lubricants were prescribed. And 2 months later she presented with a mass over the same site. Past history of trauma, burn and chronic exposure to sunlight was absent. Examination revealed a mass of 1.25cm -1.50cm width & 1cm - 1.25cm in height approximately, shape was irregular & firm in consistency. Eyelid margin contour was lost with loss of eyelashes. Other ocular structures were within normal limits. No associated lymphadenopathy was noted. Incisional biopsy of the mass was suggestive of moderately differentiated SCC.

Treatment: Wide excision of the mass was done. Full thickness defect of the upper eyelid was reconstructed with Cutler - Beard technique.

Conclusion: Wide variation at presentation, delay in diagnosis and high propensity to recur with risk of perineural spread leads to difficulty in management. Therefore, any suspicious lesion eyelid lesion should be excised and biopsied.

© This is an open access article distributed under the terms of the Creative Commons Attribution License (<https://creativecommons.org/licenses/by/4.0/>) which permits unrestricted use, distribution, and reproduction in any medium, provided the original author and source are credited.

1. Introduction

Squamous cell carcinoma (SCC) is a malignant tumour of the squamous layer of cells of the epidermis. Accounting for 9.2% of all eyelid malignancies.¹ The risk factors are environmental factors like chronic sun exposure, ionizing radiation, arsenic ingestion, psoralen plus ultraviolet A (PUVA) therapy. Intrinsic factors like xeroderma pigmentosa, chronic dermatoses, ulceration and scarring may contribute to the development of SCC.² Managing a case of malignant tumor can be challenging due to varied presentation and increased morbidity.³ We report a case of eyelid squamous tumor following blepharitis which is rare in a patient with previously normal skin. However, early diagnosis and management of the tumor and follow-up for a minimum five years can largely influence the survival rate of the patient.⁴

2. Case Scenario

A 45 year old female presented with itching, sticky discharge and swelling over the right upper eyelid (RUL) for 20 days [Figure 1].

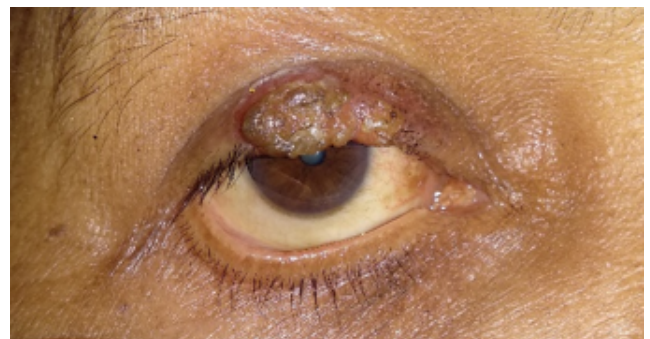


Fig. 1: Showing irregular lesion in right upper eyelid.

* Corresponding author.

E-mail address: babli.de.301990@gmail.com (M. Deori).

Initially, she was treated as a case of blepharitis. 2 months later she presented with a mass over the same site. There was no history of pain. Past history of trauma, burn and chronic exposure to sunlight was absent. No history of skin cancer amongst the other members of the family. On examination, the lesion was irregular, no hyperkeratotic changes seen. On palpation, the mass was non-tender, size was 1.25cm - 1.50cm wide & 1cm - 1.25cm in height approximately, measured at the base of the lesion. Shape was irregular & firm in consistency. The overlying skin was partly excoriated and partly nodular, extending up to the underlying conjunctiva. The contour of the lid margin was lost with loss of eyelashes. Other ocular structures were within normal limits. No associated lymphadenopathy (preauricular and submandibular lymph nodes) was noted on examination. General & systemic examination were within normal limits.

2.1. Investigation

An Incisional biopsy of the mass, [Figure 2] showed sheets of neoplastic cells, high nucleocytoplasmic ratio, hyperchromatic nuclei and few prominent nucleoli which is consistent with moderately differentiated squamous cell carcinoma (SCC). CT brain & orbit was done to rule out metastasis. All blood investigations were done in an order to perform the surgery.

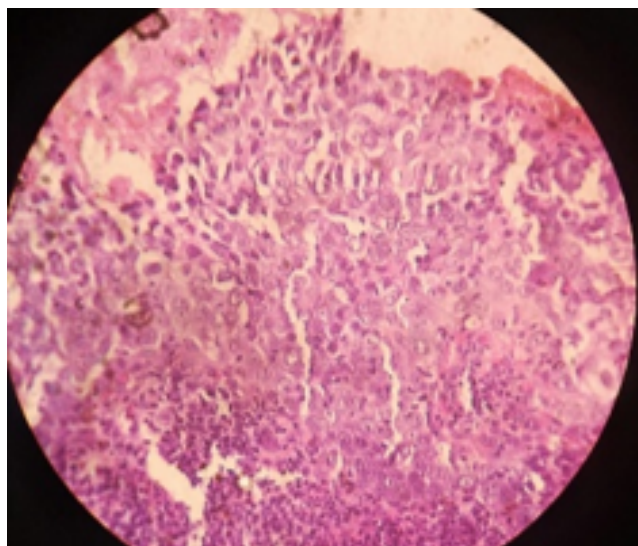


Fig. 2: High-power Photomicrograph, showing sheets of neoplastic cells which was suggestive of moderately differentiated squamous cell carcinoma.

2.2. Treatment

Patient's written consent was taken before the surgery. She underwent wide excision of the mass along with full thickness excision of upper eyelid under general anesthesia.

A frozen section was done to confirm a tumor free margins. The resected mass was sent for histopathological examination for confirmation of the type of tumor. The full thickness defect of the upper eyelid was reconstructed with Cutler - Beard technique after confirmation of the tumor free margins. At first, a full thickness lower eyelid flap was divided into anterior (skin & muscle) and posterior (conjunctiva) and sutured with upper eyelid defect [Figure 3].

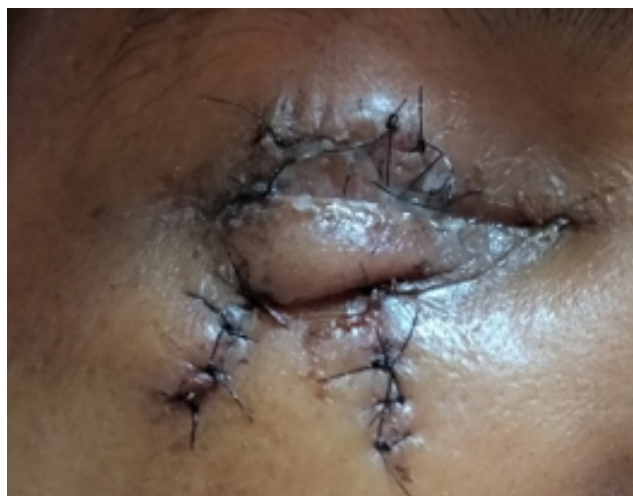

Fig. 3: Showing closure of the right upper eyelid defect.

After 6 weeks the eyelids were opened. On follow-up at 6 months and one year, no perineural spread and orbital invasion were noted. There was no perineural invasion of the tumor. No lymph node and distant metastasis were noted. The patient was doing well both functionally and cosmetically.

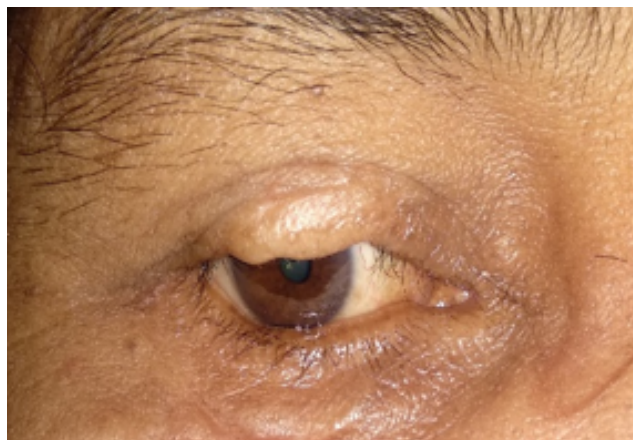


Fig. 4: Right eye showing normal upper eyelid, at 1 year follow-up period.

3. Discussion

As previously mentioned, SCC occurs most commonly in fair skinned, elderly individuals with history of chronic sun exposure and skin damage.¹ Donaldson MJ et al. in a retrospective review have found that lower eyelid is commonly affected than the upper lid.² In contrary, we report a middle aged female presenting with SCC in the upper eyelid. Soysal HG et al. in a retrospective study reported that tumors with well-differentiated and moderately differentiated histology were less likely to metastasize than those with poorly differentiated histology.⁵ The data suggests that the risk of recurrence of tumor was increased with delayed in diagnosis and excision of tumor without tumor free margins.⁶ Any eyelid lesion which is defiant to usual medical and surgical treatment should arouse suspicion, and examined clinically and histopathological to rule out carcinoma, as in our case. Vreck I et al. have also reported a similar case of cutaneous squamous cell carcinoma which initially presented as a chalazion, which did not respond to the conventional management.⁷

4. Conclusion

Wide variation at presentation, difficulty in histopathological diagnosis, delay in diagnosis and high propensity to recur, risk of perineural spread leads to difficulty in management. Therefore, any suspicious lesion of the eyelid should be examined thoroughly and biopsied for confirmation. The gold standard management is frozen controlled section excision of the tumor. Regardless, the type of management, all patients with eyelid SCC should be advised for life-long follow up.

5. Conflicts of Interest

All contributing authors declare no conflicts of interest.

6. Source of Funding

None.

References

1. Reiffer DM, Hornblase A. Squamous cell carcinoma of the eyelid. *Survey Ophthalmol.* 1986;30:349–65. doi:10.1016/0039-6257(86)90089-5.
2. Donaldson MJ. Squamous cell carcinoma of the eyelids. *Br J Ophthalmol.* 2002;86(10):1161–5. doi:10.1136/bjo.86.10.1161.
3. Arora RS, Bhattacharya A, Adwani D, Arora SS. Massive periocular squamous cell carcinoma engulfing the globe: a rare case report. *Case Rep Oncol Med.* 2014;.
4. Virk SK, Fisher AJ, Fisher BD, Rodriguez A. A Clinical Masquerader: Squamous Cell Carcinoma of the Eyelid Previously Diagnosed as an Eye Bump. *Canadian Journal of Optometry.* 2019;81(2):56–61. Available from: <https://dx.doi.org/10.15353/cjo.v81i2.436>. doi:10.15353/cjo.v81i2.436.
5. Soysal HG, Markoc F. Invasive squamous cell carcinoma of the eyelids and periorbital region. *Br J Ophthalmol.* 2007;91:325–9. doi:10.1136/bjo.2006.102673.
6. Dailey JR, Kennedy RH, Flaharty PM, Eagle RC, Flanagan JC. Squamous Cell Carcinoma of the Eyelid. *Ophthalmic Plast Reconstr Surg.* 1994;10(3):153–9. doi:10.1097/00002341-199409000-00002.
7. Vreck I, Hogan RN, Mancini R. Cutaneous squamous cell carcinoma of the eyelid masquerading as a chalazion. *Int Ophthalmol.* 2015;35(1):131–4. doi:10.1007/s10792-014-0025-7.

Author biography

Monalisa Deori, Senior Resident

Arup Deuri, Assistant Professor

Cite this article: Deori M, Deuri A. A deviant behaviour of squamous cell carcinoma of eyelid: Rare case report. *IP Int J Ocul Oncol Oculoplasty* 2020;6(4):269-271.