



Original Research Article

Role of tarsorrhaphy in healing of persistent epithelial defects in today's era

Dawar Shuja¹, Jagriti Rana¹, Kshama Dwivedi^{1,*}, Mahak Garg¹¹Dept. of Ophthalmology, MLN Medical College, Prayagraj, Uttar Pradesh, India

ARTICLE INFO

Article history:

Received 07-02-2020

Accepted 19-02-2020

Available online 03-09-2020

Keywords:

Tarsorrhaphy

Persistent epithelial defects (PED)

ABSTRACT

Introduction: Tarsorrhaphy has always been advised for management of persistent epithelial defects, but it is losing its importance in present era.

Materials and Methods: It was a prospective interventional study. Twenty-one patients of persistent epithelial defects presented over a period of two years at a tertiary hospital. They underwent tarsorrhaphy, along with medical management. All patients were followed up for a minimum period of two months.

Observation: Eighty-five percent of patients with PED resolved with tarsorrhaphy alone. Rest three patients which failed to heal, underwent amniotic membrane transplantation at 4th week as add-on procedure, following which they resolved.

Discussion: Tarsorrhaphy helps in healing of PED by decreasing the interpalpebral fissure and retaining the tears and medicines in cul-de-sac. It also decreases the windshield wiper effect of eyelid margins. Conclusion: Tarsorrhaphy should always be considered as first modality for treating the PED.

© 2020 Published by Innovative Publication. This is an open access article under the CC BY-NC license (<https://creativecommons.org/licenses/by-nc/4.0/>)

1. Introduction

Corneal epithelial defect which fails to heal within fourteen days of corneal injury, even with conservative medical management, is known as Persistent Epithelial Defect (PED).¹ It is a clinical condition which is infrequently encountered in ophthalmology. Usually it responds to conservative management, but sometimes it doesn't. Then the other modalities come into play. It has been observed that tarsorrhaphy is now being forgotten as compared to bandage contact lens, amniotic membrane transplantation and other emerging modalities. Tarsorrhaphy is the most economical procedure with easy surgical technique. In this study, we have tried to evaluate role of tarsorrhaphy in healing of PED as first line of modality.

2. Materials and Methods

It was a prospective interventional study conducted at Regional Institute of Ophthalmology, Prayagraj. Twenty one

patients were selected over a period of 24 months (January 2018 to December 2019) by convenient sampling method.

2.1. Inclusion criteria

Patients with PED, who failed to respond to conservative treatment in the study period were included in this study. The various etiologies of PED presenting to our hospital during this study period were - exposure keratopathy, post penetrating keratoplasty, neurotrophic ulcers, post-infection, surgeries other than penetrating keratoplasty, chemical injuries and trauma. All these patients were advised standard treatment in the form of lubricants and patching. Patients refractory to this standard therapy were taken up for tarsorrhaphy.

2.2. Exclusion criteria

Patients not fulfilling inclusion criteria were excluded from this study. Other causes of exclusion were – acute infections, adnexal pathology, raised digital IOP and patients on long term systemic medications except

* Corresponding author.

E-mail address: drdkshama@gmail.com (K. Dwivedi).

for diabetes. Permission was taken from Institutional ethical committee. Written informed consent was taken from patients. Demographic parameters were recorded. A detailed history of ocular symptoms and treatment received was taken. Pain, photophobia, lacrimation and foreign body sensation was asked.

Anterior segment was evaluated with slit lamp. Half of length and breadth of epithelial defect was multiplied to the area of defect. IOP was recorded with non-contact tonometer. It was within normal range in all patients.

Table 1:

S.No.	Symptoms	Number of patients	Percentage
1	Photophobia	18	85.71
2	Lacrimation	15	71.43
3	Pain	12	57.14
4	Foreign body sensation	10	47.62

Tarsorrhaphy was performed in eligible candidates. Type of tarsorrhaphy was permanent and lateral in all patients. For performing the procedure² – local anesthesia was injected in lateral 1/3rd of both eyelids. Two incisions were given on the lid margin – 1st on the gray line and 2nd incision was placed 0.5 mm behind the 1st incision and the part of post lamella was excised. Now the respective lamellas were sutured together, with 5-0 non-absorbable sutures using bolsters. Bolsters and sutures were kept in place for 10 to 15 days. Upon their removal all tarsorrhaphies were found to be successful. Conservative management in the form of drops were continued.

2.3. Observation

The present study included 21 eyes of 21 patients over the study period. In the present study, following causes were found to be responsible for PED –

Table 2:

Causes	No. of patients	Percentage
Neurotrophic Keratopathy	5	23.81%
Exposure Keratopathy	4	19.05%
Post penetrating Keratoplasty	4	19.05%
Surgeries other than Penetrating keratoplasty	2	9.52%
Chemical Injury	3	14.29%
Trauma	1	4.76%
Idiopathic	2	9.52%

Neurotrophic and exposure keratopathy were the commonest cause for PED. Four penetrating keratoplasty patients had PED in the graft area which failed to heal in two weeks' time. Two patients of PED had surgeries other than PK – i.e. one developed it 3 days after cataract surgery

whereas other patient developed it immediately after VR surgery. Chemical injuries were responsible for PED in two patients of chemical injuries. Both of them had grade III injuries, one due to acid injury and another due to alkali injury.

Table 3:

Mean age in years(±SD)	59.3±16.4
Gender M:F	9:12 (42.85:57.15%)
Residence Rural: Urban	15:6 (71.43:28.57%)
Diabetics	2 (9.52%)
Smoker	1 (4.76%)

Mean age of these patients were 59.3±16.4 years. Male: female ratio in the study group was 9:12. Seventy-one% of the patients were from the rural background. In our study population, two patients (9.52%) were diabetics and one patient (4.76%) patient was smoker. All these patients underwent permanent lateral tarsorrhaphy.

Epithelial defect was recorded preoperatively, at 1 week, 2 week and at 4 week. It was as follows:

Table 4:

Preoperative	28.99 ± 16.22 mm ²
1 week	19.62 ± 11.57 mm ²
2 week	7.85 ± 4.29 mm ²
4 week	3.41 ± 3.64 mm ²

Three patients failed to heal even at fourth week after tarsorrhaphy. Two of them had chemical injuries while the third patient had neurotrophic keratopathy. Add on treatment in the form of cryopreserved amniotic membrane was applied on the cornea following which all three PED resolved in 10.2 ± 4.9 days.

Time of removal of tarsorrhaphy was decided by the aetiology of PED. In four patients of exposure keratopathy, tarsorrhaphy was kept for >1 year; and in two patients of chemical injuries, it was removed after 6 months. In rest twelve patients, tarsorrhaphy was removed 4 weeks after healing of PED.

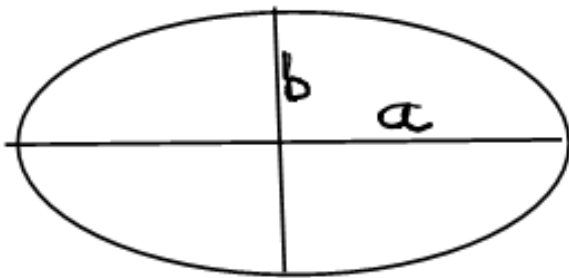
3. Discussion

PED is sometimes an innocuous entity, healing by medications but sometimes it fails to heal by medications alone, then other interventions come into play. Tarsorrhaphy has always been advised in such situations. But it is a common observation that tarsorrhaphy is now being forgotten. Hence the role of tarsorrhaphy alone in patients with PED in our cornea clinic was evaluated.

In our study, most common cause of PED was neurotrophic keratopathy in five patients (23.81%), followed by exposure keratopathy and Post penetrating keratoplasty patients of four each (19.05%). Chemical injuries causing PED was seen in three

patients (14.29%). Two eyes had PED due to surgeries other than PK – one had VR surgery, while other had cataract surgery in a controlled diabetic patient. Trauma was the etiology in only one patient (4.76%) while two patients (9.52%) cause could not be determined. Previous studies by Prabhasawat et al³ and Cosar et al⁴ have shown that the predominant etiology of PED was neurotrophic keratitis. Hamza⁵ et al reported ocular surface disorders as predominant cause. Blanco et al⁶ studied PED associated with stromal thinning or corneal ulcers. PED seen after penetrating keratoplasty is a specific entity, which was studied by Fu et al,⁷ Raj et al⁸ and Seitz et al.⁹

The mean area of epithelial defect preoperatively was $28.99 \pm 16.22 \text{ mm}^2$ in our study. Area of elliptical defect was calculated in the method as described below.



Largest dimension was measured and then dimension perpendicular to it was measured. They are known as major and minor axis. They were halved to obtain semi-major and semi-minor axis. Suppose they are a and b. Now the area of elliptical defect is calculated as πab in mm^2 . The mean area of epithelial defect was reduced to $19.62 \pm 11.57 \text{ mm}^2$ at week one, $7.85 \pm 4.29 \text{ mm}^2$ at week two. At fourth week, the mean area of defect was $3.41 \pm 1.64 \text{ mm}^2$, due to three patients of PED which failed to heal even at fourth week.

Mean area of epithelial defect was $30.74 \pm 27.34 \text{ mm}^2$ in study by Dhillon et al,¹⁰ which was almost similar to the mean area of PED in our study. Whereas mean area (\pm SD) of PED in a study by Seitz et al⁹ ranged from 13.86 ± 4.37 in erosions to $10.5 \pm 3.74 \text{ mm}^2$ in ulcers. It was quite smaller in comparison to our study. Prabhasawat et al³ measured the largest dimension and not the total area. It was 3.8 mm on average, hence quite smaller PED were studied. In our study, the area of PED gradually reduced from preoperative values to each postoperative visit, and finally healed in eighteen patients. In remaining three patients though the size gradually decreased in size but the PED still remained at 4 weeks. Hence an additional procedure, in the form of amniotic membrane transplantation was performed in all three cases. Following the procedure these PED's healed in 10.2 ± 4.9 days. Cryopreserved amniotic membrane not only acts as a scaffold but also provides various growth factors which contribute in healing of PED.⁸

Tarsorrhaphy partially closes the eyelids, so that interpalpebral area and hence the exposure of cornea to external environment decreases. It avoids drying of cornea. After tarsorrhaphy, the eye drops remain in cul-de-sac for longer time and their duration of contact with cornea increases, increasing the absorption of drugs. Most importantly, blinking is reduced in amplitude hence it's windshield wiper like effect on regenerating corneal epithelium is avoided. All these factors together lead to healing of PED.⁸

Other treatment modalities have some issues associated with them. Bandage contact lens is one of the treatment modalities, but it is well known fact that bandage contact lens per se predisposes to infection beside causing foreign body sensation. Added cost is another factor. Amniotic membrane is beneficial in the view that it provides a basement membrane where proliferating epithelial cells migrate and get firmly adhered. It also provides various growth factors which help in healing of PED. But this benefit is seen only with cryopreserved amniotic membrane, not with dried amniotic membrane which is commercially available. Cryopreserved amniotic membrane is limited in availability, reducing its practical usage.

4. Conclusion

Tarsorrhaphy is quite useful modality for healing of PED. Though many other methods have come in vogue, due to which tarsorrhaphy is quite forgotten nowadays. But still, it is superior to other modalities, in terms of ease of affordability and surgical technique. Eighty five percent of our patients responded to this therapy alone, hence it should be considered as the first intervention in patients with PED.

5. Source of Funding

None.

6. Conflict of Interest

None.

References

1. Vaidyanathan U, Hopping GC, Liu HY, Somani AN, Ronquillo YC, Hoopes PC, et al. Persistent corneal epithelial defects: A Review Article. *Med Hypothesis Discov Innov Ophthalmol*. 2019;8(3):163–76.
2. Rajak S, Rajak J, Selva D. Performing a tarsorrhaphy. *Community Eye Health J*. 2015;28(89):10–11.
3. Prabhasawat P, Tesavibul N, Komolsuradej W. Single layer and multilayer amniotic membrane transplantation for persistent corneal epithelial defect with and without stromal thinning and perforation. *Br J Ophthalmol*. 2001;85:1445–63.
4. Cosar BC, Cohen EJ, Repuano CJ, Laibson P. Tarsorrhaphy: clinical experience from a cornea clinic. *Cornea*. 2001;20(8):787–91.
5. Hamza MS, Ullah MR, Hashmi A, Sahaf IA. Amniotic membrane transplantation in ocular surface disorders. *Pak J Ophthalmol*. 2011;27:138–41.

6. Azuara-Blanco A, Pillai CT, Dua HS. Amniotic membrane transplantation for ocular surface reconstruction. *Br J Ophthalmol.* 1999;83(4):399–402.
7. Fu Y, Liu J, Tseng SCG. Ocular Surface Deficits Contributing to Persistent Epithelial Defect After Penetrating Keratoplasty. *Cornea.* 2012;31(7):723–9.
8. Raj A, Dhasmana R, Bahadur H, Nagpal RC. Persistent epithelial defect post penetrating keratoplasty: A challenge. *UJO.* 2015;10(1):30–4.
9. Seitz B, Das S, Sauer R, Mena D, Hofmann-Rummelt C. Amniotic membrane transplantation for persistent corneal epithelial defects in eyes after penetrating keratoplasty. *Eye.* 2009;23(4):840–8.
10. Raj A, Dhillon H, Bahadur H. A comparative study of tarsorrhaphy and amniotic membrane transplantation in the healing of persistent corneal epithelial defects. *Indian J Ophthalmol.* 2020;68(1):29–33.

Author biography

Dawar Shuja Junior Resident III

Jagriti Rana Associate Professor

Kshama Dwivedi Associate Professor

Mahak Garg Junior Resident Ist

Cite this article: Shuja D, Rana J, Dwivedi K, Garg M. Role of tarsorrhaphy in healing of persistent epithelial defects in today's era. *IP Int J Ocul Oncol Oculoplasty* 2020;6(3):192-195.