



## Review Article

## Study of transcanalicular endonasal laser DCR: Our experience

Ashish Bhojak<sup>1,\*</sup>, Ashok Thanth<sup>1</sup>, Nitin Trivedi<sup>1</sup><sup>1</sup>Dept. of Ophthalmology, Nagri Eve Hospital, Ahmedabad, Gujarat, India

## ARTICLE INFO

## Article history:

Received 13-08-2020

Accepted 23-08-2020

Available online 03-09-2020

## Keywords:

Surgical classical DCR

## ABSTRACT

Surgical classical DCR with external approach is considered as mainstay treatment with higher success rates for nasolacrimal duct obstructions. But In certain conditions, Transcanalicular endonasal laser DCR is proven more advantageous than classical DCR due to less complications like bleeding and low morbidity with acceptable success rate. The purpose of this study is to study the success rate and complications of Transcanalicular laser-assisted endoscopic dacryocystorhinostomy. We present our experience of transcanalicular endonasal laser DCR done in 50 patients with 6 month follow-up period. Diode laser was used to create ostium in all cases. Success rate of surgery is defined by patent sac syringing at each follow-up visit in most cases. Complications observed like bleeding, lid edema and pain are minor and easily manageable. At the end of our study, the final success rate is around 60% which is acceptable and comparable to other studies. Transcanalicular laser-assisted DCR, is a newer approach for nasolacrimal duct obstruction with good success rate and minimal complications with Shorter surgical time, faster recovery and better cosmesis than external classical DCR.

© 2020 Published by Innovative Publication. This is an open access article under the CC BY-NC license (<https://creativecommons.org/licenses/by-nc/4.0/>)

## 1. Introduction

Dacryocystorhinostomy (DCR) is the mainstay treatment for epiphora resulting from nasolacrimal duct obstruction.

Dacryocystorhinostomy (DCR) means creation of anastomosis for direct communication between the lacrimal sac and the nasal cavity through a bony ostium and thus to reestablish lacrimal outflow by creating a bypass into the nasal cavity. There are different surgical techniques available for DCR. These include external DCR, endomechanical laser DCR, endonasal laser DCR, and transcanalicular laser-assisted DCR. External surgical DCR has been a successful surgery in the treatment of nasolacrimal duct obstructions (NLDOs) since many years but with its limitation like prolonged surgical time, unpredictable bleeding, and external scar. recently, minimally invasive techniques like transcanalicular laser-assisted endoscopic DCR have gained popularity. The first endoscopic DCR was described by Caldwell<sup>1</sup> (1893).

However, the endoscopic technique was not successful because of difficulty in visualizing the endonasal anatomy, but in last two decades, the development and use of newer generation rigid nasal endoscope provides better view of nasal cavity, even allowing the visualization at angles from direct visual axis and thus gaining popularity. The last step in the development of less traumatic DCR is the endocanalicular/transcanalicular approach. In this approach, first described in 1963 by Jack,<sup>2</sup> a probe is inserted through the lower lacrimal punctum via the canaliculus into the lacrimal sac following the anatomical pathway of tear outflow. Osteotomy is performed either by a mechanical drill or laser energy through an optic fiber, which is inserted within the probe. The first laser Described for clinical use in DCR procedure was the KTP laser in 1993 by Reifler. then after Nd:YAG laser, Er:YAG laser and diode laser is used. among which diode laser is gaining popularity.<sup>3-5</sup> Currently, this procedure is performed with an incision-free technique that avoids visible scarring, requires shorter operating time, produces less bleeding—and is easier to learn—than other DCR

\* Corresponding author.

E-mail address: [drashishbhojak@yahoo.in](mailto:drashishbhojak@yahoo.in) (A. Bhojak).

methods. We opted for transcanalicular approach<sup>3,6</sup> because of its better success rate and it allows direct application of the laser to the obstructed site, in spite of smaller osteotomy compared to endonasal approach. In this study, We present our experience of transcanalicular laser-assisted-DCR without intubation in 50 patients.

## 2. Materials and Methods

This prospective study included 50 patients over two and half year period at oculoplasty department at tertiary eye care hospital and were treated with transcanalicular laser-assisted DCR without intubation for NLDO. The inclusion criteria included

Patients with h/o persistent watering with or without mucoid/mucopurulent discharge with NLDO. Patients in whom sac syringing revealed obstruction in the lower lacrimal passage with regurgitation from the opposite punctum suggestive of block distal to common canaliculi and few patients with mucocoele.

We excluded all patients with Punctal and canalicular abnormalities, eyelid disease or deformity, acute dacryocystitis, common canalicular obstruction, previous trauma with disfigurement, malignancy or h/o radiation therapy, nasal polyps, and gross nasal septal deviation, polyp or nasal pathology. Detailed examination was performed by otolaryngologist on all patients prior to surgery. All patients had preoperative sac syringing irrigation of the lacrimal pathways. A complete ophthalmic examination was performed to rule out other causes of watering like Blepharitis, ectropion, entropion, lagophthalmos, trichiasis, conjunctivitis, keratitis.

A thorough ENT examination of all cases of dacryocystitis is done to detect any nasal or paranasal pathology contributing to the disease or to detect any contraindication to the nasal drainage procedure.

Detailed history and screening was done for systemic disease like hypertension, diabetes and bleeding disorders and if found were controlled before the surgery. All preoperative routine blood investigation like complete blood count, esr, bleeding time, clotting time, hiv, hbsag were done. All procedure were done on an outpatient basis and all surgical procedure was performed under local anesthesia.

Patient's Periorbital area was properly draped after all aseptic precautions. Few drops of 2% Xylocaine or proparacaine were instilled topically in the operating Eye. Lignocaine 10% spray is used to anesthetize the nasal cavity starting before half hour. Local infiltration with 2% lignocaine is done. Upper Punctum was dilated With Netteleship's Punctum Dilator, Then probing was done and hard stop felt. Spinal needle with trocar is passed through canaliculus then needle is replaced with laser fiber optic. With video guided nasal endoscope, laser beam was identified in middle meatus. Endolaser fibre which is already connected with 810nm Diode Laser, with settings of

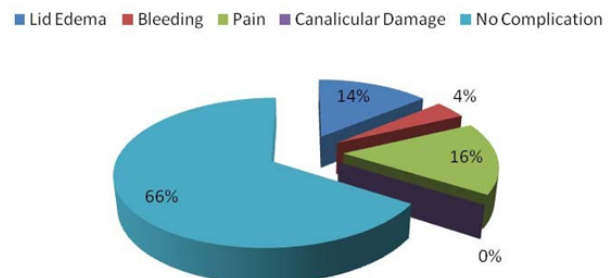
energy of 5 watts and pulse interval of 50-70ms according to the surgeon's convenience with interpulse pause of 50 ms, Laser is fired with a constant and firm force pressing the probe tip against the bone. The perforation of the sac wall and the lacrimal bone is felt as a sudden give way sensation. The procedure is repeated by repositioning the tip till sufficient size osteotomy of approx 3-5 mm have been achieved.. Result of the surgery is confirmed by performing sac syringing immediately following the laser procedure. No intubation with silicone stent was done. patients were discharged on same day..

Patients were advised steam inhalation, use of nasal decongestant drops and to avoid blowing of nose postoperatively for one week. post operative treatment regimen included oral analgesics and antibiotics with the use of steroid-antibiotic eye drops. Mitomycin –c nasal drop preparations q.i.d. for 2 weeks. Sac syringing was done on next day and at all follow up visits.

## 3. Results

Our study included 50 patients among which 29 were females and 21 males. We performed transcanalicular endonasal laser dcr surgically successfully in all 50 patients. In our study of 50 cases, 37 (74%) cases had epiphora only, 4 (8%) had epiphora with swelling, 2 (4%) had epiphora with ROPLAS, and 7 (14%) had epiphora, swelling and ROPLAS. Immediate Complications after laser assisted transcanalicular endoscopic DCR surgery are minor and rarely occurs. During procedure in 2 (4%) patients bleeding were observed and controlled. on next day, 8(16%) patients felt pain and 7(14%) patient was having lid odema which is taken care with oral anti inflammatory tablets. Canalicular damage is not observed in Diode laser because energy concentrate at the end of fiber optic.

### Complications



Objective patency considered as successful sac syringing and in 3 pediatric patients patency considered as absence of watering and discharge. We observed out of 50 patients, patency was 100% upto 2 months. In 3 pediatric cases, evidence of epiphora was not observed during study period. At 4 months objective patency was dropped to 69%, then at 6

**Table 1:** Success rate of laser assisted transcanalicular endoscopic DCR

follow up	No. of patency	Not Patent	Not Possible	lost follow up	Success rate
1 <sup>st</sup> postop.day	47	0	3	0	100%
1 <sup>st</sup> wk	47	0	3	0	100%
3 <sup>rd</sup> wk	47	0	3	0	100%
2 <sup>nd</sup> month	47	0	3	0	100%
4 <sup>th</sup> month	30	13	3	4	69.77%
6 <sup>th</sup> month	24	18	3	5	57.14%

months patency was dropped to 57%.at the end of 6 month, the final success rate of procedure was around 60%.

#### 4. Discussion

The Surgical classical DCR with external approach which creates direct communication between lacrimal sac and nasal cavity through bony ostium is gold standard treatment for management of nasolacrimal duct obstruction. Though it s higher success rate upto 90-95%, many surgeons tried for better minimally invasive options with better technology, techniques, instrumentation to overcome limitations like longer surgical time, longer recovery time, external scar and bleeding like complications.

With better available newer generation endoscopes and use of lasers, with better visibility and bloodless (minimal bleeding) cutting of bone helps for newer approaches and modifications in endonasal dcr which gives promising results. “Laser assisted transcanalicular endoscopic dacryocystorhinostomy” is More usefull surgical procedure<sup>6,7</sup> in elderly patients who are not eligible for long duration surgery. and in those patients who don’t want external approach, scar & demands cosmetically better choice. Also, it is useful in patient who are on long term anticoagulation treatments or hemorrhagic disease.

The success rate of laser assisted transcanalicular Endoscopic DCR in our study is around 60% at the end of six months. Success rate in our study is comparable to other study results which ranges between 55% to 85%.<sup>6</sup> We compared our results in literature and found our success rate of 60% is close to 60.8% by upender wali,buthaina et al , 70%–80% by Olver and Mandeville and Woog.<sup>8,9</sup> and by Maini et al., who in a randomized clinical trial found 68% success rate in endolaser DCR at 12-month follow-up.<sup>10</sup>

Exact Size of the ostium could not be measured is the limitation in our study. The size of 3.8–5 mm osteotomy size has also been found to be safe by upender wali, buthaina et al, Drnovsek and Beltram and Yazici and Yazici.<sup>7,9,11</sup> Higher cost of lasers and handling are concerns. In some studies, Canicular intubation/stenting done at the end of surgery, which is not done in our study. Even use of mitomycin C intraoperatively<sup>12</sup> in laser-DCR are likely to increase the success rate.

Long-term success rates of transcanalicular laser-assisted DCR may be low compared to external DCR,<sup>13</sup> but in certain condtions its advantages are proven.

So, Laser assisted transcanalicular Endoscopic DCR surgery has certain advantages like Shorter operation time, Under local anesthesia and Less intra operative hemorrhage so can be done on an outpatient basis with Lower morbidity and Faster patient recovery.<sup>3,4,10</sup> minimal or no post operative edema and ecchymosis is observed in our study. It also Can be done in narrow nasal fossae with better and direct visulisation. It is suitable for elderly patients with co morbidity. and cosmetically concerned patiens due to Absence of an external scar and no or minimal post-op edema, ecchymosis. Better results are also expected because of less surgical manipulation of medial canthal tissues which contribute for functioning of physiological palpebral-canalicular pump mechanism.

#### 5. Conclusion

Transcanalicular laser-assisted DCR, is a new promising treatment option for nasolacrimal duct obstruction with good success rate and minimal complications. Shorter surgical time, faster recovery and better cosmesis can be achieved than external classical DCR with this approach.

#### 6. Source of Funding

None.

#### 7. Conflict of Interest

None.

#### References

1. Caldwell GW. Two new operations for obstruction of the nasal duct with preservation of the canaliculi and an incidental description of a new lacrimal probe. *NY Med J.* 1893;57:581.
2. Jack MK, Dacryocystorhinostomy. Description Of A Transcanalicular Method. *Am J Ophthalmol.* 1963;56:974–7.
3. Fern andez FJA, Fern andez MAA, Fern andez AM, Lara MC. Transcanalicular dacryocystorhinostomy technique using diode laser . *Arch Soc Esp Oftalmol .* 2004;79:325–30.
4. Hong JE, Hatton MP, Leib ML, Fay AM. Endocanalicular Laser Dacryocystorhinostomy. Analysis of 118 Consecutive Surgeries. *Ophthalmol.* 2005;112:1629–33.
5. Piaton JM, Limon S, Ounnas N, Keller P. Transcanalicular endodacryocystorhinostomy using neodymium: YAG laser. *J Fr Ophthalmol.* 1994;17:555–67.
6. Eloy P, Bertrand B, Trussart C, Jouzdani E, Collet S, Rombaux P, et al. Transcanalicular diode laser assisted dacryocystorhinostomy. *Acta Otorhinolaryngol Belg.* 2000;54:157–63.

7. Beltram M, Drnovsek-Olup B. Transcanalicular diode laser-assisted dacryocystorhinostomy. *Indian J Ophthalmol*. 2010;58:213-7.
8. Mandeville JT, Woog JJ. Obstruction of the lacrimal drainage system. *Curr Opin Ophthalmol*. 2002;13:303-9.
9. Wali U, Sabt B, Badaai YA, Al-Mujain A. Transcanalicular laser-assisted dacryocystorhinostomy: First report from Oman. *Indian J Ophthalmol*. 2018;66(1):170-2.
10. Maini S, Raghava N, Youngs R, Evans K, Trivedi S, Foy C, et al. Endoscopic endonasal laser versus endonasal surgical dacryocystorhinostomy for epiphora due to nasolacrimal duct obstruction: prospective, randomised, controlled trial. *J Laryngology Otol*. 2007;121(12):1170-6.
11. Yazici B, Yazici Z. Final nasolacrimal ostium after external dacryocystorhinostomy. *Arch Ophthalmol*. 2003;121(1):76-80.
12. Henson RD, Henson RG, Cruz HL, Camara JG. Use of the Diode Laser With Intraoperative Mitomycin C in Endocanalicular Laser Dacryocystorhinostomy; 2007. Available from: <https://dx.doi.org/10.1097/iop.0b013e31802f208d>.
13. Plaza G, Beteré F, Nogueira A. Transcanalicular Dacryocystorhinostomy With Diode Laser: Long-term Results. *Ophthalmic Plast Reconstr Surg*. 2007;23(3):179-82.

### Author biography

**Ashish Bhojak** Ex. Resident

**Ashok Thanth** Ex. Resident

**Nitin Trivedi** Ex. Professor

**Cite this article:** Bhojak A, Thanth A, Trivedi N. **Study of transcanalicular endonasal laser DCR: Our experience.** *IP Int J Ocul Oncol Oculoplasty* 2020;6(3):167-170.