



Case Report

A rare case report of conjunctival fibrolipoma in an adolescent

Mir Alam Siddique¹, Ashu Pilania², Sandip Sarkar^{3,*}, Amit Kumar Deb³

¹Dept. of Ophthalmology, Gauhati Medical College, Guwahati, Assam, India

²Aravind Eye Hospitals, Chennai, Tamil Nadu, India

³Jawaharlal Institute of Postgraduate Medical Education and Research, India605006, Puducherry, India



ARTICLE INFO

Article history:

Received 01-03-2020

Accepted 26-05-2020

Available online 30-06-2020

Keywords:

Fibrolipoma

Lipoma

Benign tumour

Adipose tissue

ABSTRACT

Fibrolipomas are a fat-containing lesions that are characterised by the presence of adipose tissue and rich amounts of fibrous tissues. We present a case of a 18-year-old female presented with complaints of swelling over outer part of left eye for 2 years. Magnetic resonance imaging (MRI) revealed T1 and T2 hyper-intense lesion in temporal aspect of left eyeball without any involvement of optic nerve or any hypertrophy of extra-ocular muscles. A careful dissection was done because of proximity of the lesion with lateral rectus and optic nerve, followed by excision. The diagnosis of fibrolipoma was made on histopathological examination. Fibrolipoma is a rare variant of the lipoma and only few cases have been reported in the orbit till date. The case we have reported is first of its kind in India.

© 2020 Published by Innovative Publication. This is an open access article under the CC BY-NC license (<https://creativecommons.org/licenses/by-nc/4.0/>)

1. Introduction

Lipomas are a benign variety of soft tissue neoplasms of mature adipose tissue.^{1,2} A fibrolipoma is an uncommon subtype of lipomas, which are comprised of mature adipocytes. They are usually benign and nonthreatening.³ Fibrolipomas are a member of family of fat-containing lesions that are characterised by the presence of adipose tissue and rich amounts of fibrous tissues.^{4,5} They are well distinguished from the neighbouring tissues. They mostly occur in adults and only few cases have been documented worldwide. We report a case of conjunctival fibrolipoma in an 18-year-old girl, first of its kind in India.

2. Case Report

An 18 year old female patient presented with a swelling over outer part of left eye for 2 years (Figure 1). Swelling became significantly prominent, with a gradual and progressive enlargement over last 6 months. It was associated with watering and foreign body sensations. There was no

significant history of trauma or family history. On physical examination patient was found to have a very large tumor, approximately 2×2.3 cm in the left eye extending from upper to lower fornix with posterior border being extending about 2 cm from the anterior globe wall. It was a firm and non-tender mass, smooth and faintly lobulated, pinkish yellow in color, and soft elastic in consistency. There were no accompanying active signs of inflammation and otherwise the remaining ocular and systemic examinations were absolutely normal. Orbital MRI revealed T1 and T2 hyper-intense lesion in temporal aspect of left eyeball without any involvement of optic nerve or any hypertrophy of extra-ocular muscles (Figure 2). A careful dissection was done because of close vicinity of lesion to optic nerve, followed by excision following which the mass was sent for histopathological examination which revealed that the lesion is composed of fibrinous collagenous tissue and sheets of mature adipose tissue without any evidence of malignancy, suggestive of fibrolipoma (Figure 3). The cosmetic appearance of the eyelid was very satisfactory after a follow-up period of 1 year and no recurrence of tumor was observed (Figure 4).

* Corresponding author.

E-mail address: drsandip19@gmail.com (S. Sarkar).

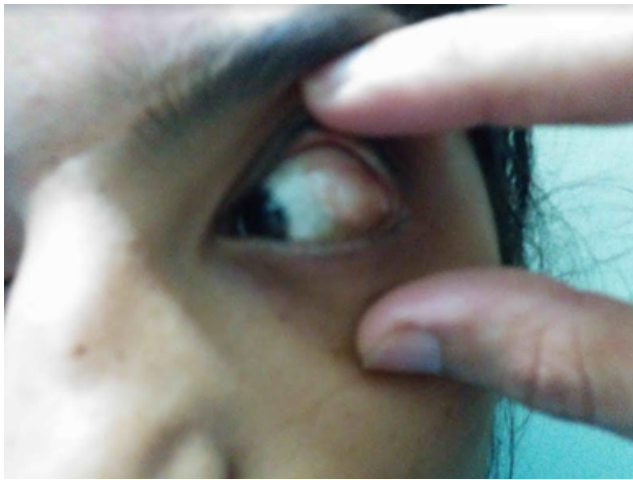

Fig. 1: Atpresentation

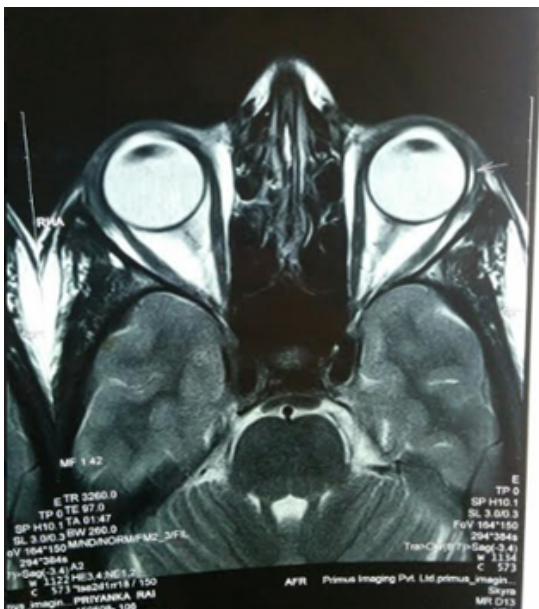

Fig. 2: MRIScan

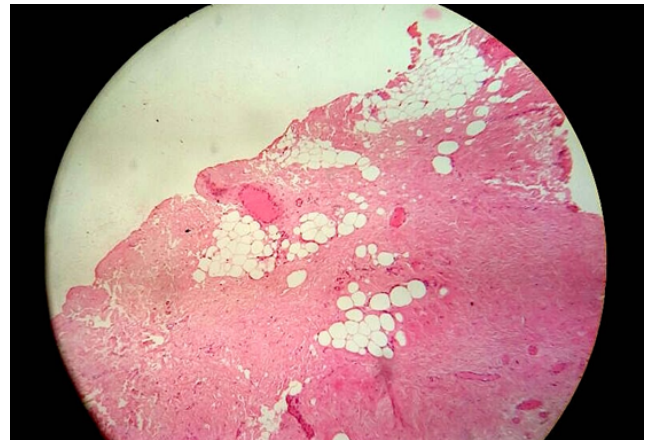


Fig. 3: Lowpower view (10X) of fibrolipoma characterized by presence of prominent bundlesof mature collagenous stroma intermixed with mature adipocytes

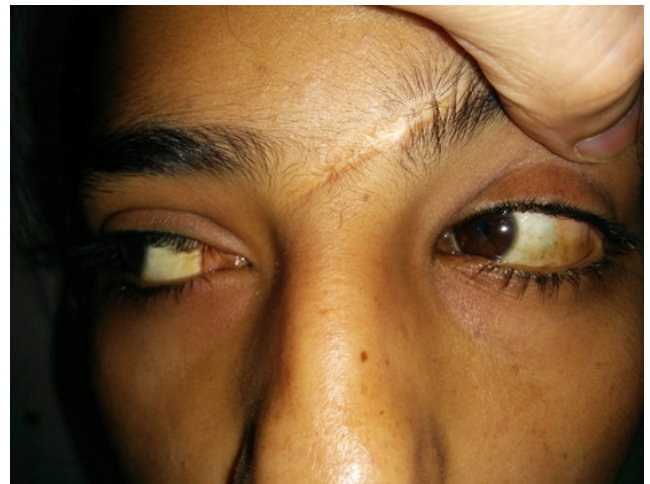

Fig. 4: Day7 post-operative

3. Discussion

Lipomas are slow growing benign tumors. They are well circumscribed and are composed of mature fat cell clustered in lobules with the help of connective tissue septa.⁶They are uncommon in the orbit, and accounts for just less than 1% of all orbital tumors.⁷Fibrolipoma is classified as a variant of lipoma by the World Health Organization (WHO), because of its composition of mature adipose tissue along with bands of dense connective tissue.^{3,6,8}They are usually seen in adult men with a peak incidence in 5th to 6th decade of life. The age of presentation in this case was uncommon, because they are rarely observed below the age of 20 years.⁶Clinically, the patient presents with an asymptomatic, gradually growing and well circumscribed

mass that can be seen in various areas, for example the oral cavity, esophagus, trachea, spermatic cord, parotid glandpharynx, larynx, colonand nose. The real incidence of fibrolipoma is hard to assess as it presents as a painless and gradual growing tumor and most commonly the patient consult clinician only for symptomatic or cosmetic problems.

The consistency of fibrolipoma can be soft or firm depending on tumor depth as well as distribution of fibrous tissue.⁹There occurs a change in consistency during contraction of involved muscle, which is a characteristic of fibrolipoma. It is soft and flat during muscle relaxation and becomes firm and more spherical during contraction.²MRI is a useful modality for diagnosing various types of lipomas. Lipomas have high signal intensity on T1-weighted images, with relative declining signal as seen on T2-weighted images, and usually the fibrolipomas are more

heterogeneous as compared to lipomas on MRI imaging. The exact etiology of lipomas and their types is not well known but an association with hereditary anomalies such as origin from lipoblastic embryonic cell nest has been suggested as well as some trauma mechanisms like chronic intermittent compression or blunt trauma has also been implicated.¹⁰ Various other causations like maturation of lipoblastomatosis, endocrinal imbalance, degenerated products of fibromatous tumor have also been cited.

Lipomas are classified on basis of their histological appearance as a simple lipoma or variant, such as angiolipoma, spindle cell, pleomorphic lipoma, myolipoma, chondroid lipoma, hibernoma and diffuse lipomatous proliferations (lipomatosis). Histologically, fibrolipomas are characterized by proliferation of components of mature adipose tissue, surrounded by septa of dense fibrous connective tissue. Furthermore, fibrolipomas have got a higher proliferative activity as compared to other variants.⁹ Usually fibrolipomas are benign tumors but very rarely they can convert to liposarcoma. The clinical differential diagnosis considered for the present case includes epidermoid cyst and dermoid cyst. Histopathological examination helps in making the definitive diagnosis. The treatment of choice for fibrolipoma and its variants is complete surgical excision but it should be very precise keeping in mind not to damage any extra-ocular muscle or optic nerve lying in vicinity of the lesion. In our case the patient requested the removal of his lesion because of its growth concerns, and the cosmetic purpose. Any harm to conjunctiva should be avoided so as to prevent post-surgical symblepharon.

4. Conclusion

In a nutshell, fibrolipomas are a rare variant of the lipoma. The treatment of choice is excision of tumor in toto. A very careful dissection should be done keeping in mind the proximity of the lesion with other orbital structures. The histopathological examination of the excised tissue remains the gold standard for making the diagnosis because of similarity in clinical pictures of various lipomas. Fibrolipomas have got an excellent prognosis and the recurrence is very rare.

5. Patient consent

I certify receiving and having archived the written consentement of Miss X, who has Conjunctival fibrolipoma about potential medical press publication of her clinical observation. This report does not contain any personal identifying information.

6. Acknowledgement

None.

7. Source of Funding

None.

8. Conflict of Interest

None.

References

1. Khubchandani M, Bahadure R, Gaikwad R, Thosar N, Baliga MS. Fibrolipoma of buccal mucosa. *Contemp Clin Dent*. 2012;3(5):S112–4.
2. Kumaraswamy SV, Madan N, Keerthi R, Shakti S. Lipomas of oral cavity: case reports with review of literature. *J Maxillofac Oral Surg*. 2009;8(4):394–7.
3. Jung SN, Shin JW, Kwon H, Yim YM. Fibrolipoma of the tip of the nose. *J Craniofac Surg*. 2009;20(2):555–6.
4. Kim MH, Sa HS, Woo K, Kim YD. Fibrolipoma of the orbit. *Ophthalm Plast Reconstr Surg*. 2011;27(1):16–24.
5. Coban Y, Coskun A. Giant fibrolipoma mimicking abdominal lipodystrophy. *Indian J Plast Surg*. 2008;41(1):97–8.
6. Ozturk M, Ila K, Kara A, Iseri M. Fibrolipoma of the nasal septum; report of the first case. *J Otolaryngol Head Neck Surg*. 2013;42(1):11.
7. Chi MJ, Roh JH, Lee JH, Paik HJ. A case of orbital lipoma with exophthalmos and visual disturbance. *Jpn J Ophthalmol*. 2009;53(4):442–4.
8. Capodiferro S, Maiorano E, Scarpelli F, Favia G. Fibrolipoma of the lip treated by diode laser surgery: A case report. *J Med Case Rep*. 2008;2(1):301.
9. Manjunatha BS, Pateel GS, Shah V. Oral fibrolipoma- a rare histological entity: report of 3 cases and review of literature. *J Dent (Tehran)*. 2010;7(4):226–31.
10. Vasconcelos JSP, Gharaibeh F, Nittinger HC. Trauma as Pathogenesis of a Plantar Forefoot Fibrolipoma: First Case and Review of the Literature. *Case Rep Surg*. 2013;2013:691276–691276.

Author biography

Mir Alam Siddique Assistant Professor

Ashu Pilania Glaucoma Fellow

Sandip Sarkar Senior Resident

Amit Kumar Deb Assistant Professor

Cite this article: Siddique MA, Pilania A, Sarkar S, Deb AK. A rare case report of conjunctival fibrolipoma in an adolescent. *IP Int J Ocul Oncol Oculoplasty* 2020;6(2):149-151.